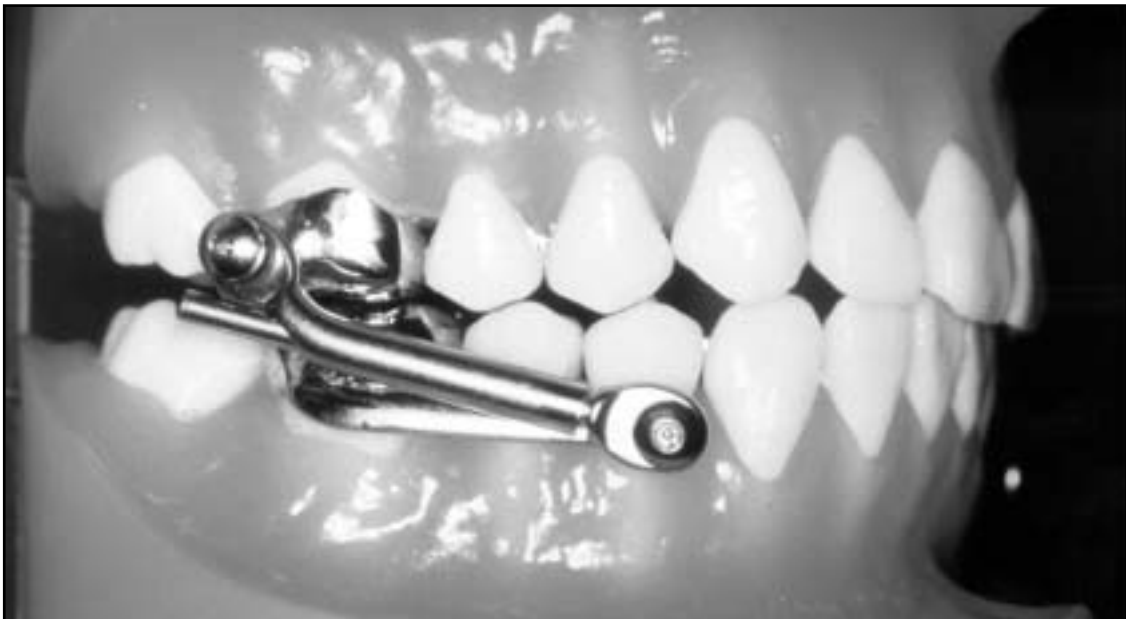

Clinical Management of Crown/Banded Herbst Appliances



A Manual for Orthodontists and Staff

Authored by Paula S. Allen-Noble
in Partnership with Allesee Orthodontic Appliances
AOA/Pro is a subsidiary of Ormco Corporation (revised 06/02)

Forward

This manual has been written by Paula S. Allen-Noble in partnership with Allesee Orthodontic Appliances/Pro Lab. It is a compilation of clinical protocols for the crown/banded Herbst appliance (sometimes called the Bite Jumper) currently being implemented by orthodontists and clinical staff who have successfully integrated the appliance into their practice.

The intent of the author is to share information concerning clinical management of the appliance, not to dictate procedure or associated treatment mechanics. This manual has been created as a continuous “work in progress” and is dedicated to keeping the orthodontic practice as current as possible concerning clinical techniques and appliance design. Graphic illustrations have been dated and are reviewed before each reprint to reflect changes and modifications.

Acknowledgements

Special acknowledgement of gratitude is given to Drs. Terry Dischinger and Joe Mayes for their significant contributions to this project, for which I am most appreciative, as well as Drs. Jim Hilgers, Bob Smith, Robert Chastant, Duane Grummons, Dwight Damon, Larry Hutta, Keith Black, Bill Dischinger and Peter Paulos. A special “thank you” to Mrs. Holly Brown, Drs. Terry and Bill Dischinger’s clinical coordinator, for her expert guidance and endless patience. Without these colleagues’ support and willingness to share with us all, the evolution of the Herbst appliance and the creation of this manual would not have been possible.

I would also like to acknowledge Ormco and Allesee Orthodontic Appliances/Pro Lab for their support of the *In Partnership with Your Practice* series of manuals and their commitment to the continuing education process. Many thanks to the Special Projects and Herbst Technical Support Teams at AOA/Pro for sharing their expertise concerning these appliances and for keeping us current with design changes and modifications. And especially to Max Hall and David Allesee for their continued support of this project. Without their vision and desire for achieving excellence in serving the orthodontic community, this manual would never have had the opportunity to be written as a “work in progress.”

Paula S. Allen-Noble
In partnership with Allesee Orthodontic Appliances/Pro Lab
June 2002

Clinical Management of Crown/Banded Herbst Appliances

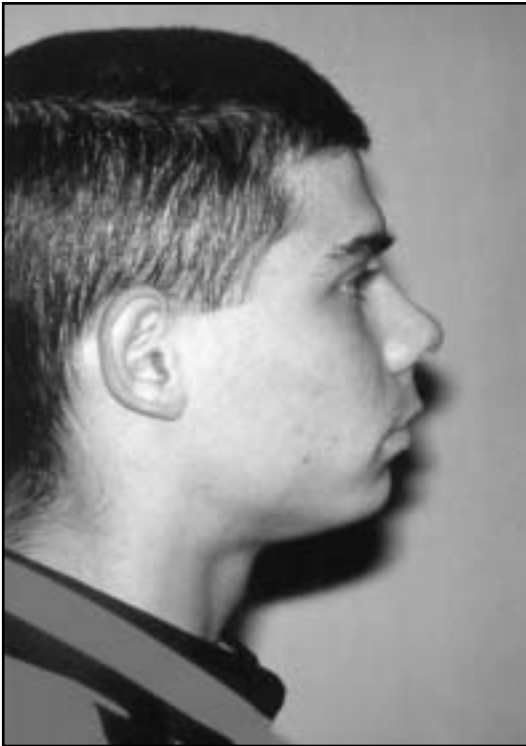Contents

Introduction of the Herbst Appliance	1
Evolution and Overview of Current Crown/Banded Herbst Designs	7
Enhancement and Options Corner	23
Prefabrication Preparation for the Herbst	25
Diagnostic Records and Impressions for Work Models	25
Bite Registrations and Placing Separators	26
Work Models for Appliance Fabrication	27
Crowns/Bands Furnished and Placed Indirect by Laboratory Technician . . .	27
Crowns/Bands Furnished and Fit Direct by Clinician or Clinical Staff	30
Delivery of the Crown/Banded Herbst	33
Pre-Insertion Checklist and Adjustments	33
Clinical Insertion	44
Post-Insertion Instructions to Patient/Parent	55
Expander Herbst	57
Expander Herbst Technical and Clinical Considerations	58
Delivery of the Expander Herbst	60
Post-Insertion Instructions to Patient/Parent	62
Expansion/Removal of Expander(s) and Continuation of Therapy	63
Hybrid Herbst	65
Technical and Clinical Considerations	65
Space-Closing Herbst	65
Intrusion Herbst	66
Treatment Sequence and Herbst Activation	69
Activating or Advancing the Herbst Appliance	70
Final Activation and Determining When to Remove the Appliance	71
Breakage and Repair	72
Removal of the Crown/Banded Herbst	73
Crown Removal Cutting Technique	74
Crown Removal Plier Technique	75
Crown Removal Slitting Plier Technique	76
Crown/Band Removal “Thumper” Plier Technique	77
Band Removal Technique	78
Cement Removal	79
Continuation of Orthodontic Treatment	81
Appendix	83
Supply List	83
Suggested Reading and Course List	84
Laboratory and Web Site Information	85

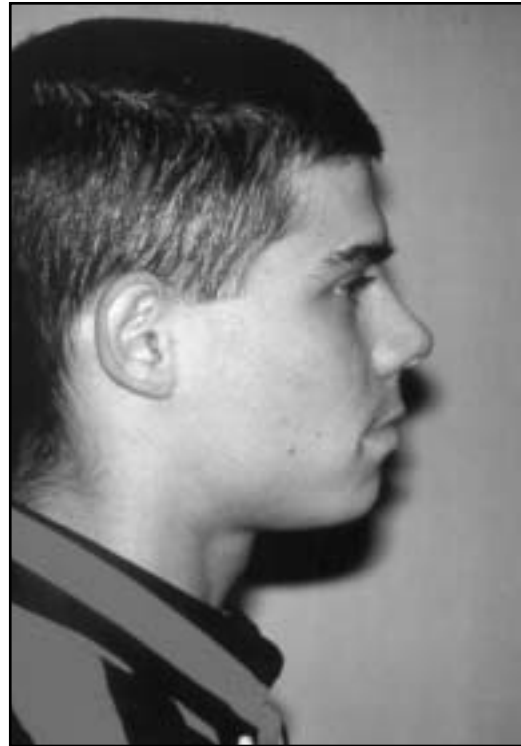Introduction of the Herbst* Appliance

The most common problem presented to the orthodontist is correction of skeletal Class II malocclusions. In the past, most Class IIs have been corrected with surgical procedures, headgear and/or elastic therapy.

In most cases, the improper bite is caused by a lower jaw that is too far back in relationship to the rest of the face. A good indicator of this type of malocclusion would be a case where the upper lip is balanced with the rest of the face by sliding the lower jaw forward, creating a more pleasing profile.



Patient with typical Class II profile.

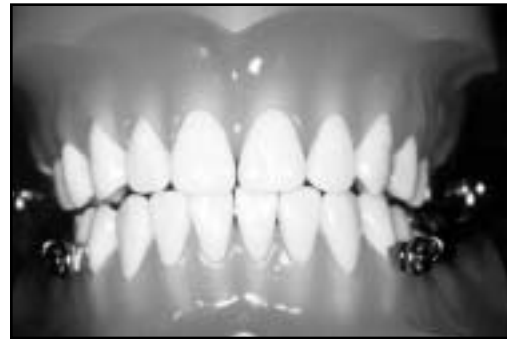
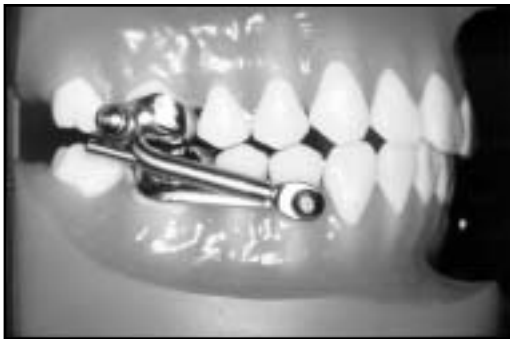
Patient with lower jaw positioned forward and edge-to-edge.

* Herbst is a registered trademark of Dentaaurum, Inc.

When the patient is still growing, it is possible to accentuate the growth of the lower jaw to catch up with the upper part of the face by using the Herbst. The Herbst is a functional appliance because it postures the patient's lower jaw in a forward direction. Over a period of months, this forward posture of the lower jaw promotes growth in the same direction. Recent research has shown that this appliance has the ability to inhibit maxillary anterior growth and produce an increase in mandibular length.

The crown and/or banded Herbst is permanently attached to the teeth for the duration of treatment, which addresses the lack of success that functional appliances have experienced in the past due to patient noncompliance. Even though this appliance prevents the lower jaw from moving backward, opening and closing movements still occur easily and patients fully adjust to the appliance in about a week.



Herbst appliances are a multifunctional adjunct to Class II correction and work well with different types of dental and skeletal Class II problems. The appliance can be designed to accommodate upper and lower expansion, orthodontic appliances, intrusion mechanics, space closure/opening of upper/lower second bicuspid space, distalization of upper molars and can be used unilaterally, bilaterally and with asymmetric cases. The appliance is a predictable way to treat Class II patients and can be modified to meet the patient's specific treatment requirements. The appliance may also be used as anchorage to achieve a variety of treatment goals.

The following are indications for Herbst treatment using standard, modified or hybrid designs:

- The upper jaw is in good position and you want to advance the lower jaw. Optimum results can be achieved by controlling the amount and direction of mandibular growth with the bite jumper.
- It is desirable to inhibit maxillary anterior growth and produce an increase in mandibular length.
- Patient presents with an obtuse nasiolabial angle and the use of headgear or Class II elastics would increase the angle, thus creating a less attractive face.

- Patients with a high-angle open bite respond well to the hybrid, open-bite intrusion appliance. The Herbst is used as anchorage to correct high-angle open bite cases through impaction of the maxillary posterior teeth and repositioning the mandible.

Intrusion Herbst

Mixed Dentition

According to Dr. Terry Dischinger, a high-angle Class II open bite, treated early to impact the maxillary molars allows autorotation of the mandible, creating a low-angle case.

Once the maxillary permanent molars are intruded, the maxillary first and second primary molars are extracted. After these teeth are extracted, the appliance will be used like a standard Herbst to correct the Class II.

Intrusion usually occurs in three to five months, with an additional three to five months for Class II correction.

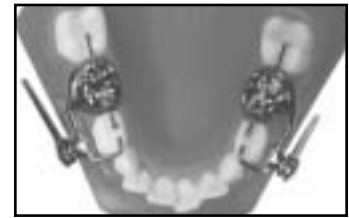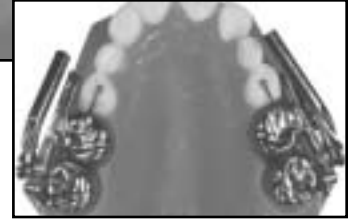
Permanent Dentition

The permanent dentition open-bite intrusion Herbst is more complicated. If required to intrude both maxillary first and second permanent molars, intrude the first molars first. If you intrude the second molars first, there won't be any way to hold them in place. When intruding second molars, a second upper intrusion appliance will be necessary.

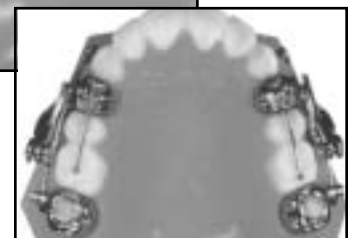
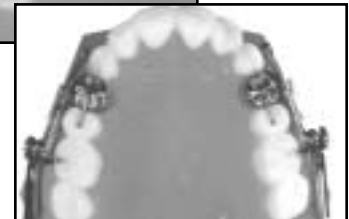
The maxillary intrusion appliance is designed differently, depending on whether or not permanent second molars are to be intruded.

Intrusion of the first molars usually occurs in three to five months, with an additional three to five months to intrude second molars and three to five more months for Class II correction.

Mixed Dentition



Permanent Dentition

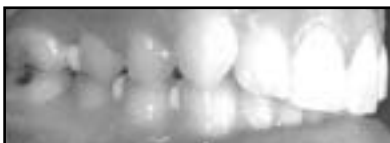
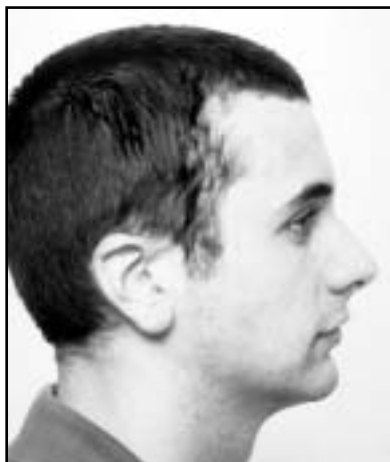
- The Class II brachycephalic patient.
This patient usually presents with lower incisors behind the A-pogonion line, a strong chin and strong musculature, making Class II and overbite correction difficult with traditional orthodontic appliances. In association with specific orthodontic mechanics, the hybrid brachycephalic Herbst allows treating these patients by moving the lower dentition into Class I occlusion with proper relation to the pogonion line and little change in chin position. It also allows the molars to erupt for better overbite correction. This appliance design is very effective for Class II, division 2 patients in intruding and advancing the mandibular incisors, repositioning the mandible, correcting overbite and mandibular asymmetry, while controlling the vertical dimension.

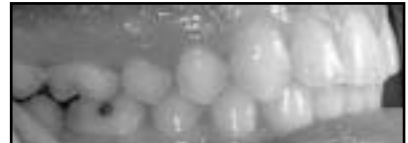Hybrid Brachycephalic Herbst

Sixteen-year-old patient – Class II, division 2 with deep overbite and distal position of mandibular incisors in relation to the A-Pogonion line. (Case provided by Dr. Terry Dischinger.)

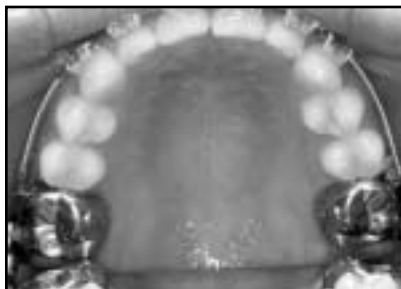
Pretreatment



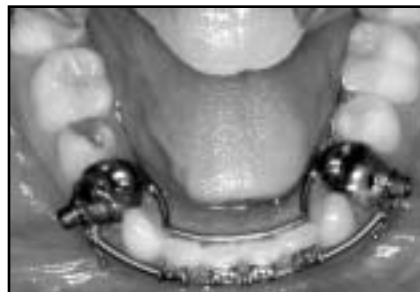Posttreatment



Final Overcorrected Position



Place brackets only on the maxillary incisors or intrude the cuspids and/or bicuspids.



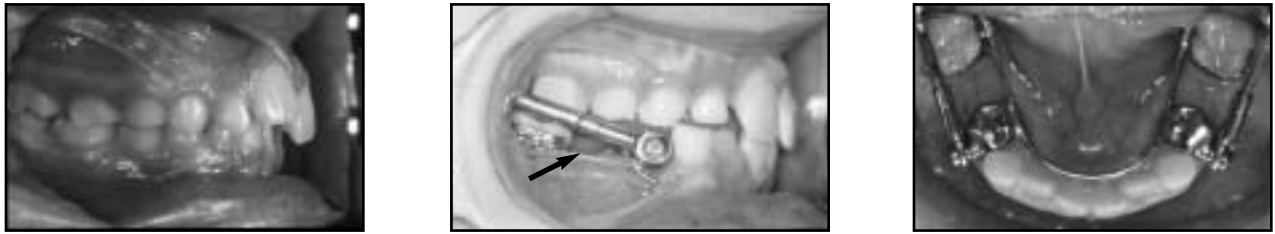
Place brackets only on the incisors for overbite correction.



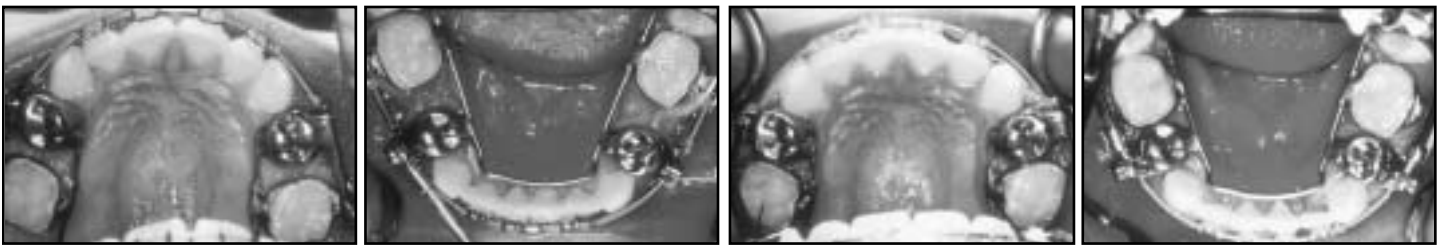Lower incisors intruded for overbite correction.

- Correction of a skeletal Class II missing upper/lower second bicuspid(s). There are a variety of designs that will allow you to close and/or open spaces using the Herbst while correcting the Class II. Using certain treatment mechanics, the appliance may also be used as anchorage for space closure/opening in Class I cases.

Space-Closing Herbst Using Sliding Mechanics to Close Spaces – Upper and/or lower molars moved forward with Ni-Ti springs, thread, or chain. Approximately 3mm of space closure is achieved in 7 to 8 weeks. Lingual wire slides through tube. Total closure in about 7 months.

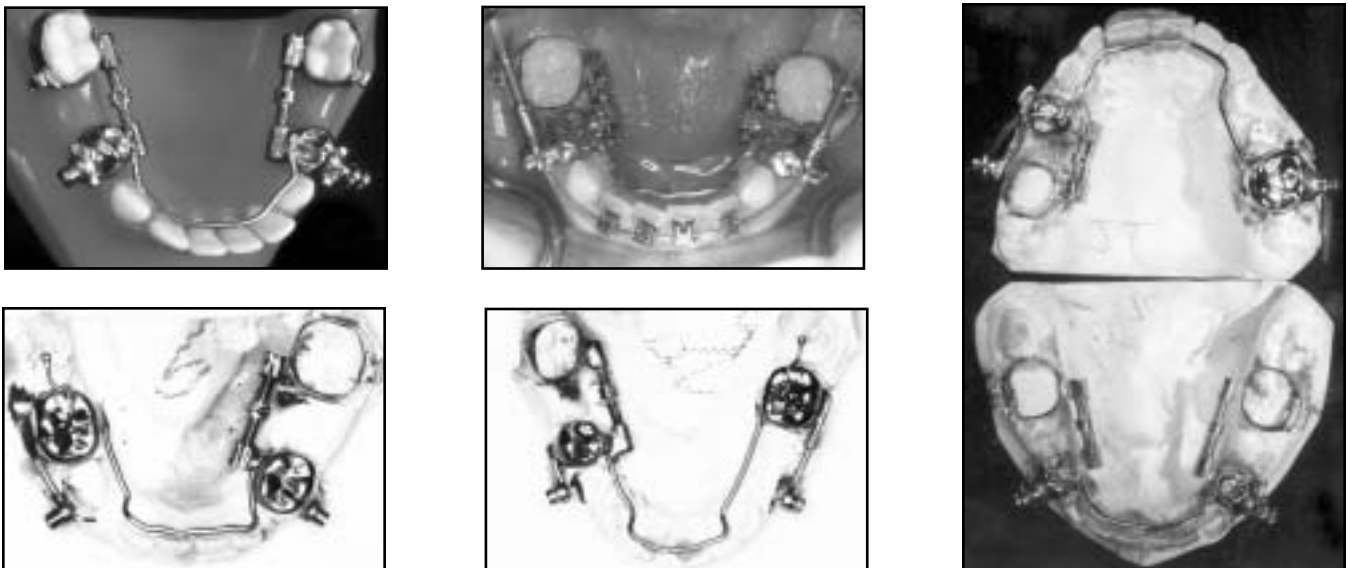


(Mixed dentition case requiring space closure provided by Dr. Joe Mayes.)



(Permanent dentition case requiring space closure provided by Dr. Terry Dischinger.)

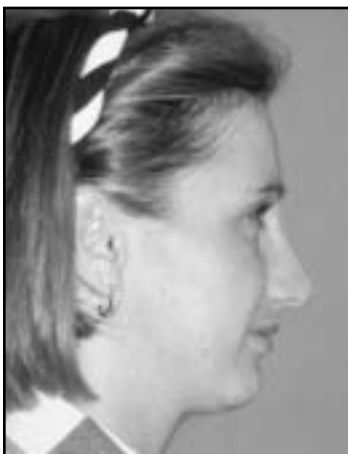Space-Closing Herbst Using Screws to Close Spaces – Upper and or lower molars moved forward using screws to close the spaces. Space closure takes approximately 2 to 3 months. (Case provided by Dr. Terry Dischinger.)



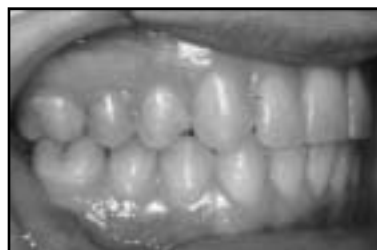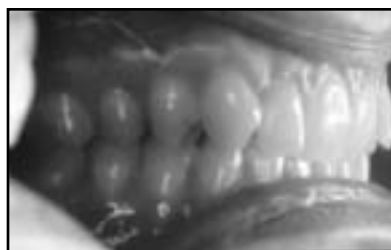- Adult cases can achieve a good compromise Class II correction using the Herbst when surgery is not an option. While the result is mostly dental, some mesial migration of the fossa is found. Adults have also shown very positive results when orthodontic treatment indicates intrusion mechanics (open-bite correction) as well as space closure/opening. (Case provided by Dr. Joe Mayes.)

Adult Class II

Pretreatment

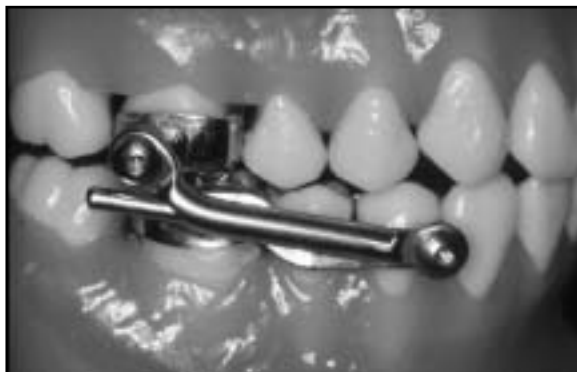

Posttreatment



Evolution and Overview of Current Herbst Designs

The Herbst appliance is by no means new to orthodontics. It was first developed by Dr. Emil Herbst in 1905 and reintroduced by Dr. Hans Pancherz in the mid seventies. The early designs usually incorporated bands or acrylic-type splints that were prone to breakage. However, the Herbst has finally found its place in the last few years as technology has advanced, allowing the orthodontic industry to design a more easily fabricated, sturdier and more comfortable appliance.



The Herbst

There are several advantages to the Herbst appliance over other Class II correctors.

- The patient's profile immediately looks better after the appliance has been inserted.
- Correction of Class II malocclusions are treated more efficiently, making treatment much easier on the orthodontist, staff, patients and parents.
- No removable parts, thus cooperation is not an issue and treatment time is predictable.
- Hygiene is not a problem.
- Orthodontic appliances can be worn in conjunction with the appliance.
- The appliance may be modified for use in a variety of ways.
 - *Stainless steel crown designs* are generally stronger than banded styles, resulting in less breakage. They are also adaptable to hybrid applications incorporating spacial and intrusion mechanics.
 - *Banded designs* have less of a learning curve for the fit and removal process. Banded Herbsts are more prone to breakage than crown Herbsts unless fabricated with reinforced band material and/or support wires. Banded Herbsts are not recommended for more complicated multifunctional applications.

There are many crown/banded Herbst designs that assist the clinician with correction of different types of dental and skeletal problems. As the orthodontist becomes comfortable in his or her command of the appliance, the designs usually become more sophisticated and modified to provide multifunctional applications based on the treatment plan. Efficiency, profitability, and consistently predictable results are what the appliance affords today's orthodontic practices.

In this section, examples of crown/banded Herbst design variations have been provided, as well as typical designs currently being used by clinicians such as the following who have successfully integrated the appliance into their practices: Drs. Keith Black, Terry Dischinger, Dwight Damon, Duane Grummons, Jim Hilgers, Larry Hutta, Joe Mayes, Michael Rogers and Bob Smith.

Herbst designs are constantly being improved and modified. Graphic illustrations have been dated and are reviewed before each reprint to reflect changes and modifications.

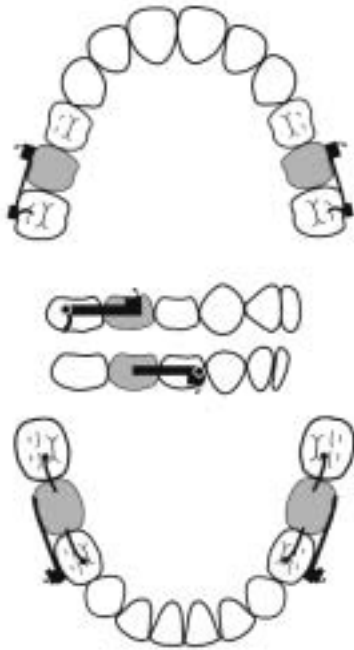
This manual has been created as a continuous "work in progress" and is dedicated to keeping the orthodontic practice as current as possible concerning clinical techniques and appliance design.

The photographs for this manual have been provided by Drs. Terry Dischinger, Joe Mayes, Dwight Damon, Larry Hutta, Jim Hilgers, Duane Grummons, Peter Paulos, Ben Pridemore, AOA/Pro and Ormco Corporation.

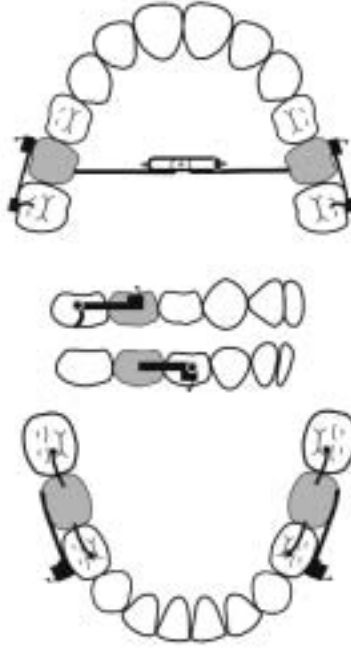
Dr. Terry Dischinger

Herbst Designs for Mixed Dentition

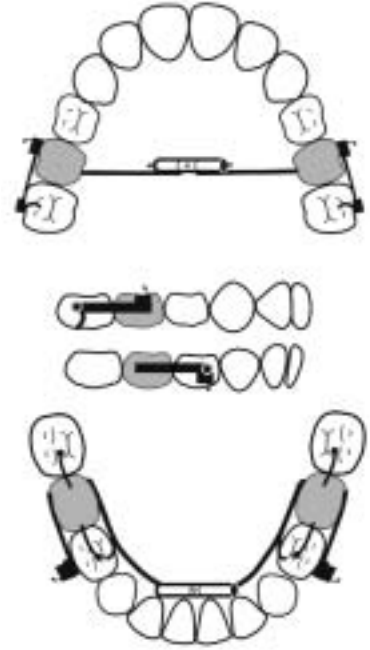
Dischinger Standard Herbst
(crowns on E's)



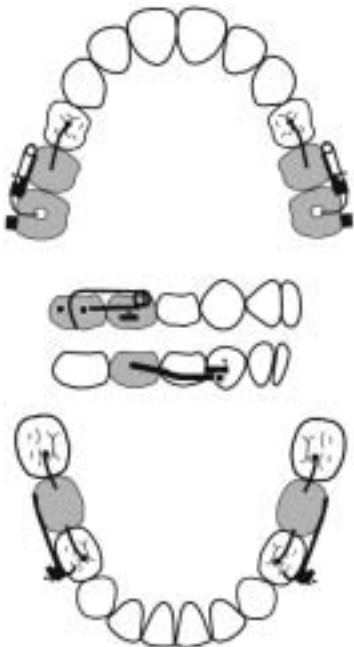
Standard/Upper Expander
(crowns on E's)



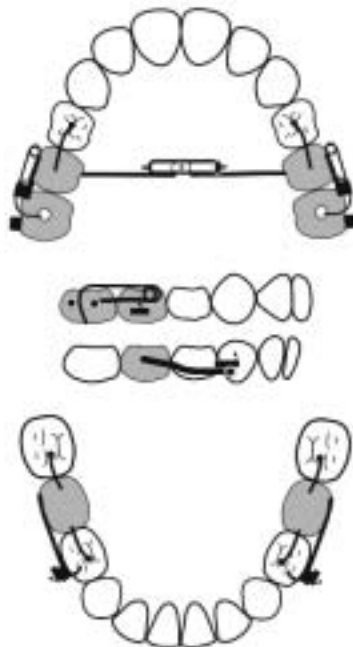
Standard U/L Expanders
(crowns on E's)



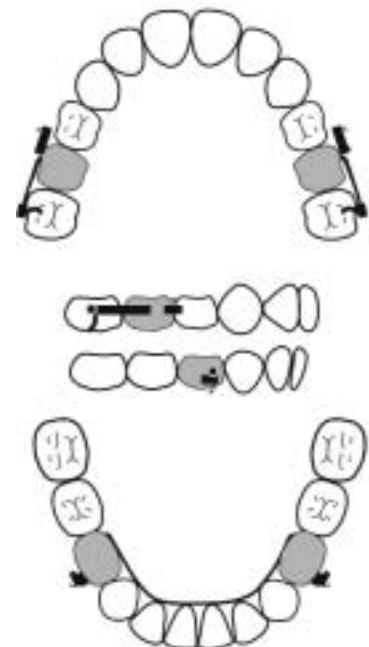
Dischinger Intrusion Herbst
(crowns on upper E's, 6's
and lower E's)



Intrusion/Upper Expander
(crowns on upper E's, 6's
and lower E's)



**Dischinger Brachycephalic
Low-Angle Herbst**
(crowns on upper E's)

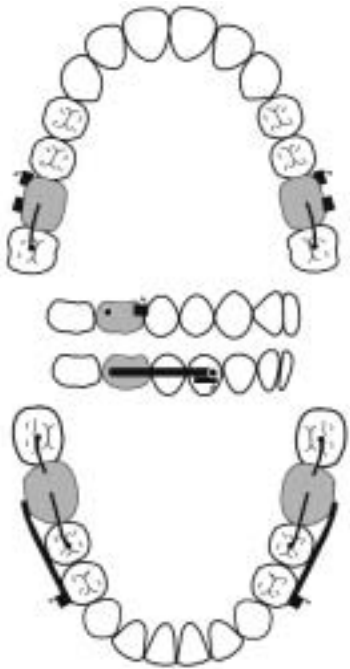


Initially the Herbst mechanism is placed to the axle on the upper extension. Once the upper 6's are intruded, the Herbst mechanism is moved to the crown on the intruded upper first molar.

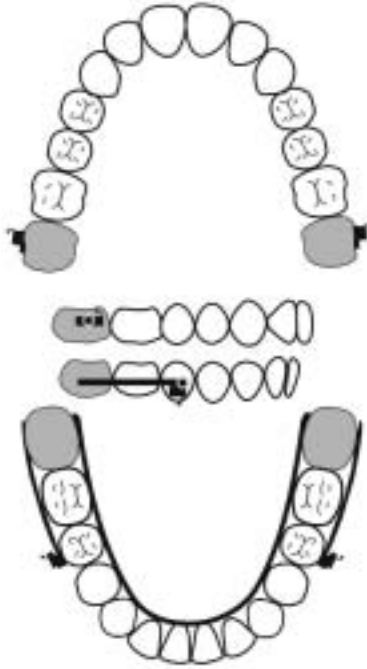
Dr. Terry Dischinger

Herbst Designs for Permanent Dentition

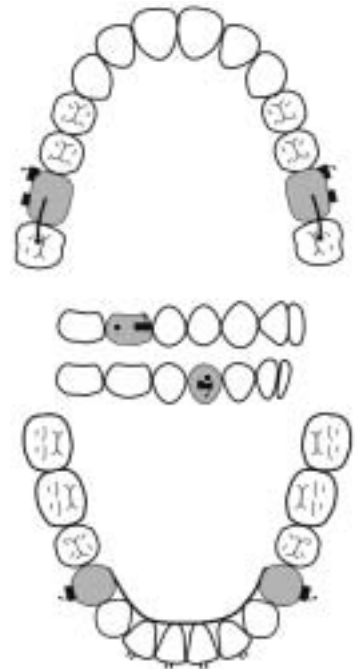
Dischinger Standard Herbst



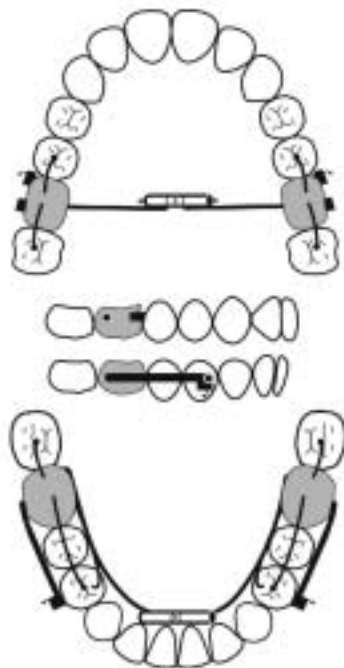
Variation of Standard
(crowns on 6's with lower lingual arch)



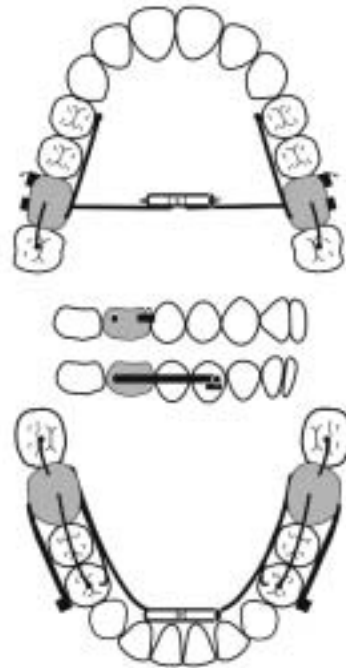
Dischinger Brachycephalic Low-Angle Herbst



Standard Herbst
U/L Expanders
(teenager and younger)



Standard Herbst
U/L Expanders
(older adult)

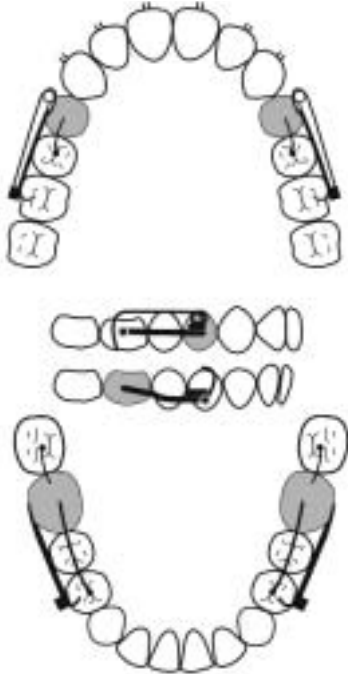


Dr. Terry Dischinger

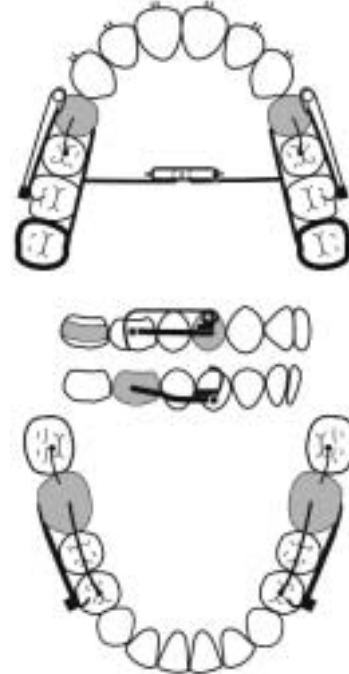
Herbst Designs for Permanent Dentition

Dischinger Intrusion Herbst – Requires (2) upper appliances when first and second molars are to be intruded. The lower appliance will remain in place throughout treatment.

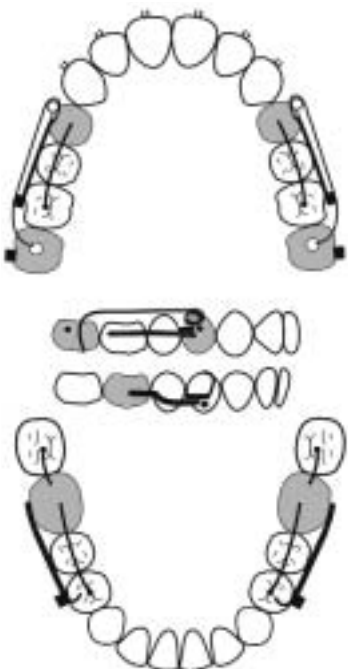
**Dischinger Intrusion Herbst
#1 of 2 upper appliances.
(crowns on upper 4's with axle extension
and intrusion wire to 6's)**



**Intrusion Herbst #1
with upper expander.
(bands on 7's to stabilize)**

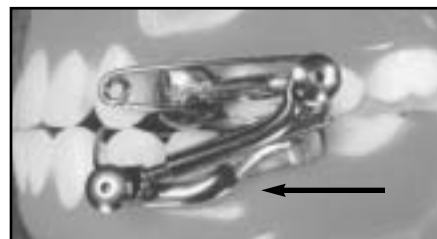


**Upper Intrusion Herbst #2 of 2
to intrude the second molars. (crowns on 7's)**



Note: *Mandibular Appliance Modification.*

In contrast to a standard Herbst, the mandibular cantilever arms of the intrusion Herbst (mixed or permanent dentition designs) are offset low and gingivally to produce more vertical force. This component of vertical force is necessary during molar intrusion.



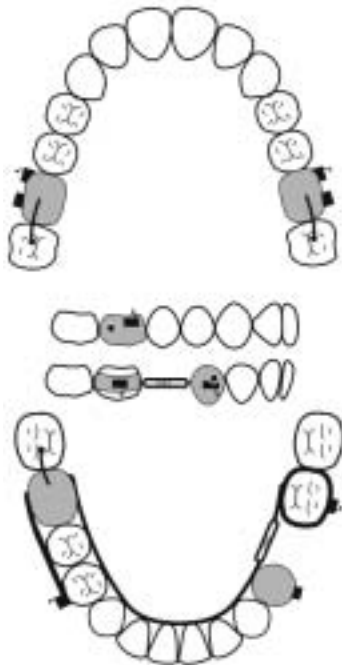
Mandibular cantilever offset.

Dr. Terry Dischinger

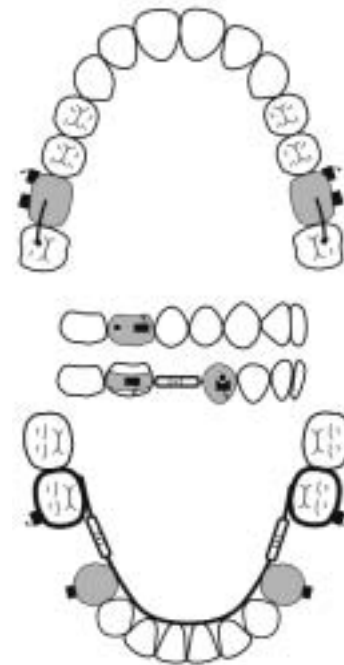
Herbst Designs for Permanent Dentition

Dischinger Space-Closing Herbsts (using screws for closure)

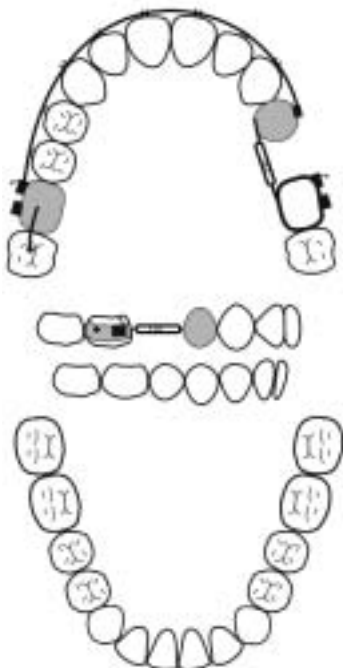
**Dischinger
Space-Closing Herbst (unilateral)**



**Dischinger
Space-Closing Herbst (bilateral)**



**Dischinger
Space-Closing in the Upper Arch**



Space-Closing Herbst

The space-closing Herbst can be used in both the maxillary and mandibular arches. It can be used bilaterally or unilaterally. The Herbst appliance is used as anchorage to hold the incisors in place, allowing molar space closure by forward movement of the molars without distalizing the incisors.

In a unilateral situation, the symmetry of the arches can be maintained during closure. Class II correction with the Herbst can occur simultaneously.

Note: If closing space in the upper arch, bond brackets on all maxillary teeth and tie back the arch to the molar immediately to keep the molars from distalizing.

Note: The appliance may also be designed to open space.

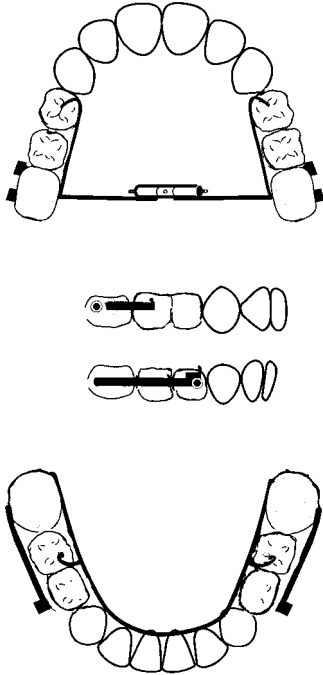
This method of space closure may be used with or without a Herbst appliance.

12/01

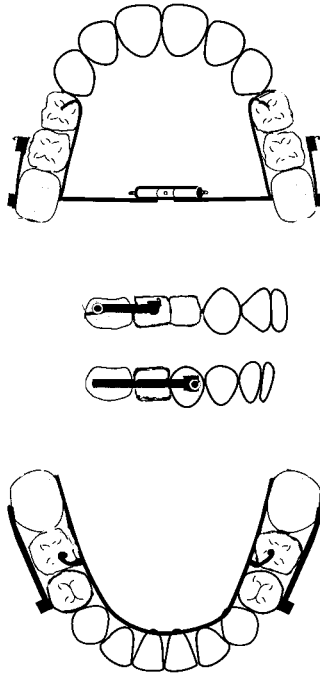
Dr. John R. "Bob" Smith

Herbst Designs

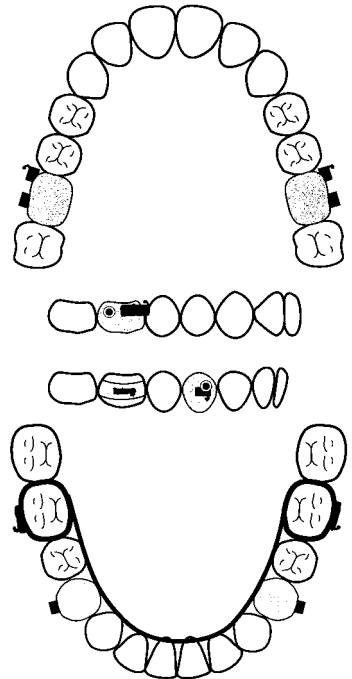
**Smith Type I
Mixed Dentition Herbst
(Expander Optional)**



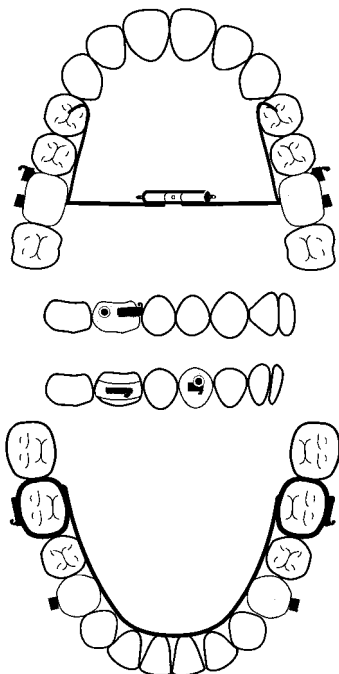
**Smith Type I
Variation**



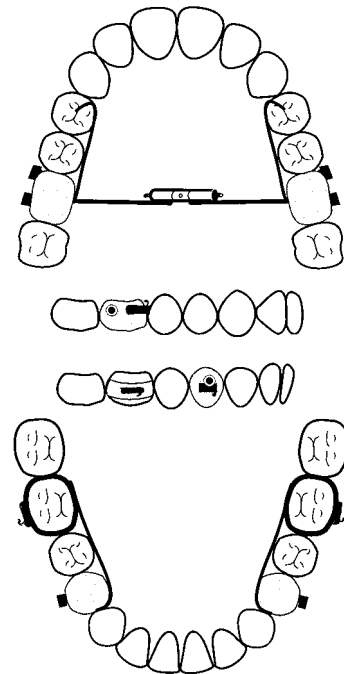
**Smith Type II
Standard Herbst
Permanent Dentition**



**Smith Type II
Upper Expander**



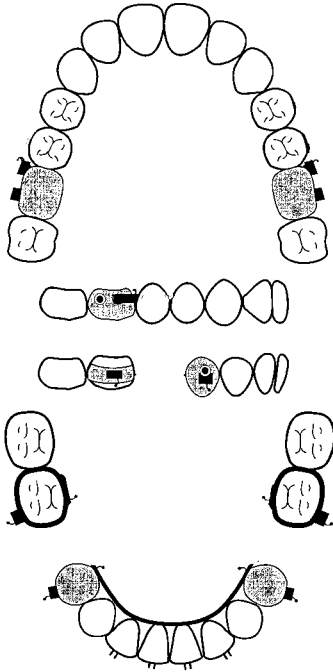
**Smith Type II
Upper Expander
Lower Modified**



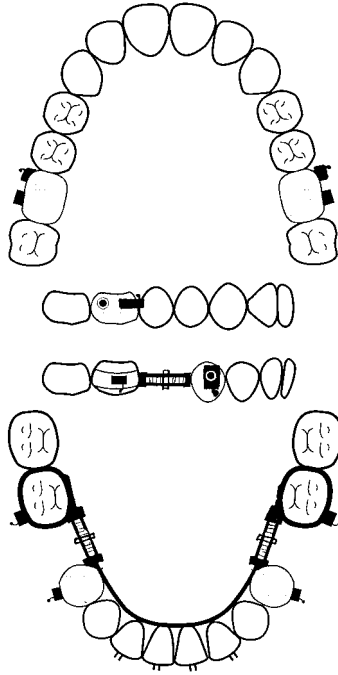
Dr. John R. "Bob" Smith

Herbst Designs

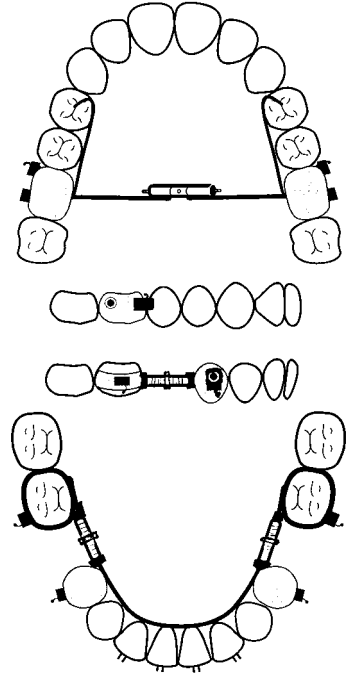
**Smith Type III
Simple Design
Space Closure**



**Smith Type III
Space Closure wth Screws
Permanent Dentition**



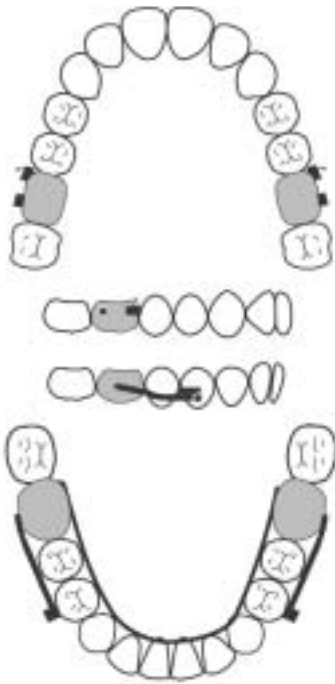
**Smith Type III
Space Closure w ith Screws
Upper Expander**



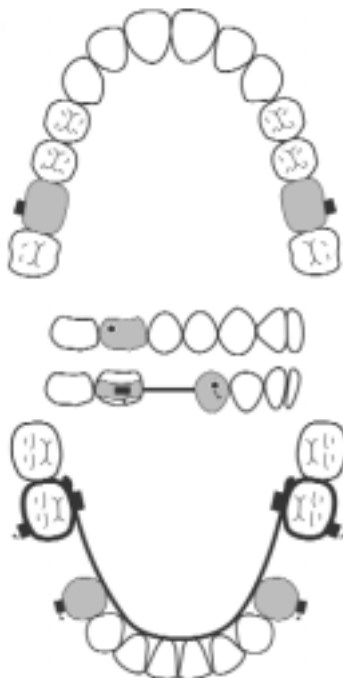
Dr. Joe Mayes

Herbst Designs

Mayes Standard Herbst (CBJ)



Mayes Space Closure Molar Mover (MMBJ)



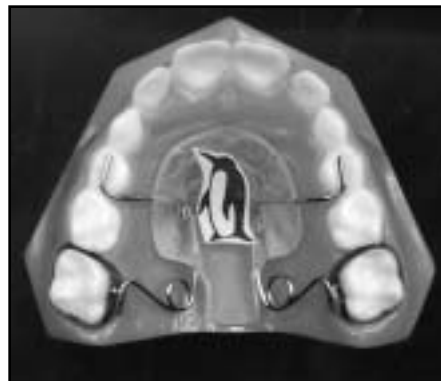
Other Treatment Modalities for Consideration

Transpalatal Arch

Dr. Mayes prefers to expand arches when necessary before Class II correction. He generally incorporates a transpalatal arch into his upper Herbst if the patient has had maxillary expansion immediately prior to delivery. The transpalatal arch will remain in place the initial 14 weeks of Herbst therapy when it will be removed.

Dentoalveolar Class II Correction

For molar distalization, Dr. Mayes uses a pendulum-type appliance. His appliance design is called the "Penguin Pendulum" and is different from Dr. Hilger's designs: (1) Dr. Mayes never incorporates an expander. He likes to expand first. (2) The spring coils are removable. (3) The spring coil is made so that the arm to distalize the molar is as close to parallel to the root of the molar as possible. (4) The acrylic pad is much thinner, which he feels allows for a smoother "swallowing trough."

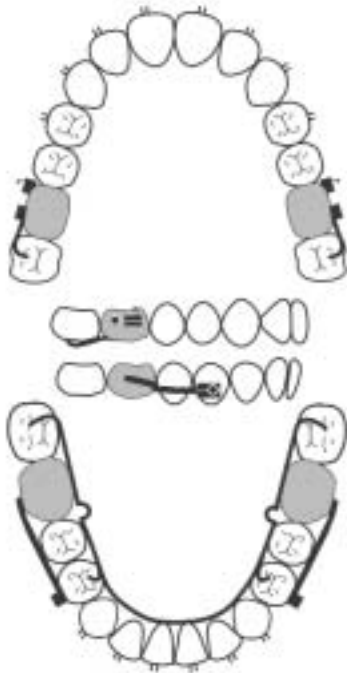


Mayes Penguin Pendulum

Dr. Larry Hutta

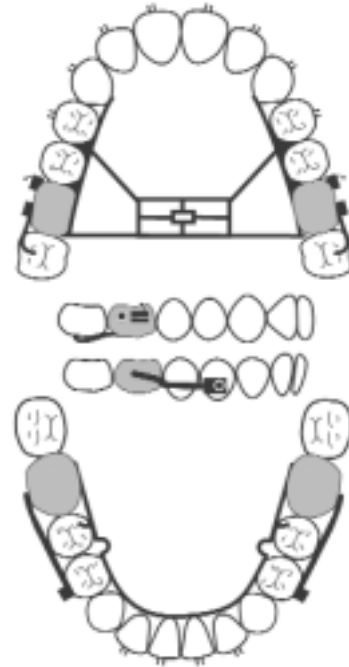
Herbst Designs

Hutta Standard Herbst



Dr. Hutta brackets the upper arch 4 to 4. He brackets the lower arch 3 to 3 using -10° torque brackets 2 to 2.

Hutta Standard Herbst with Upper Expander



After expansion, Dr. Hutta brackets the upper arch 4 to 4. On the lower arch, he places -10° torque brackets 2 to 2.

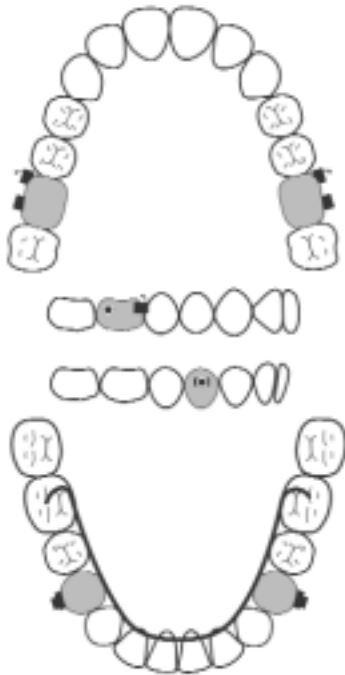
Treatment Considerations

Dr. Hutta rarely treats skeletal Class II patients in the mixed dentition. If the patient requires expansion, Dr. Hutta will either expand before Herbst treatment or incorporate an expander into the Herbst appliance.

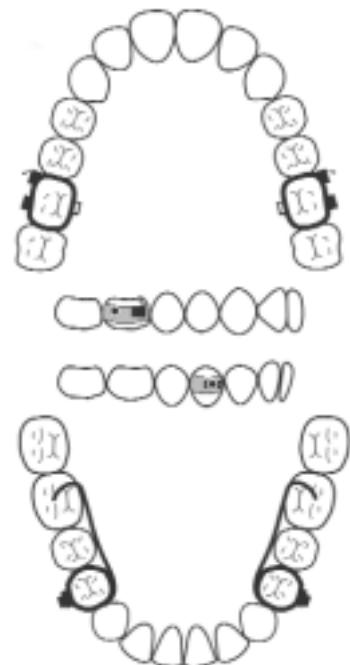
Dr. James Hilgers

Herbst Designs

Hilgers Functional Herbst



Hilgers Anchorage Herbst



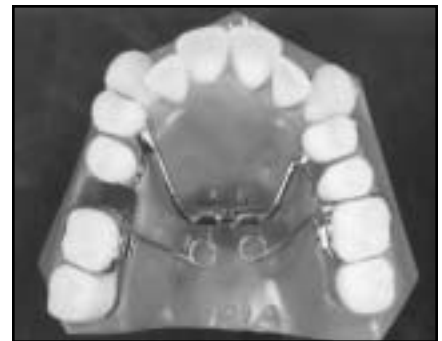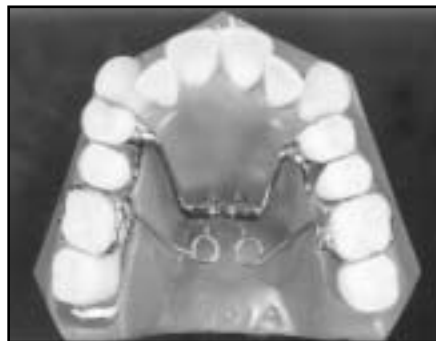(Brackets and archwire placed on lower anteriors.)

Other Treatment Modalities for Consideration

In keeping with his philosophy of hyperefficient orthodontics using noncompliance therapy in Class II nonextraction cases, Dr. Hilgers has also developed a number of effective appliances for dentoalveolar Class II correction, distalizing maxillary molars. In addition to the pendulum, pendex family of appliances, Dr. Hilgers, in collaboration with Dr. Steve Tracy, developed the MDA Expander (*Mini-Distalizing Appliance*).

The MDA Expander is a small, clean expansion appliance that has the power to distalize molars with comfort and size advantages using TMA Pendulum Springs to deliver constant force over the treatment time.

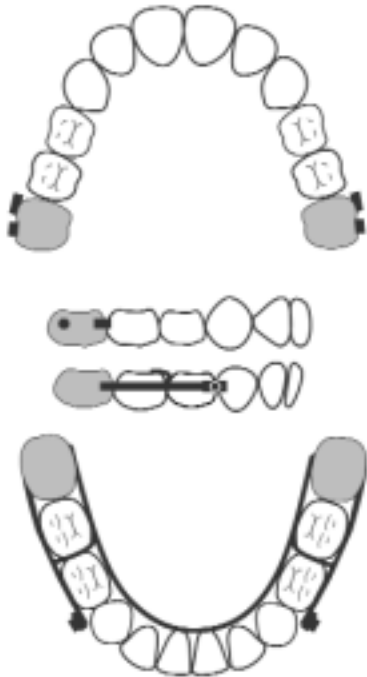
Hilgers/Tracey MDA



Dr. Dwight Damon

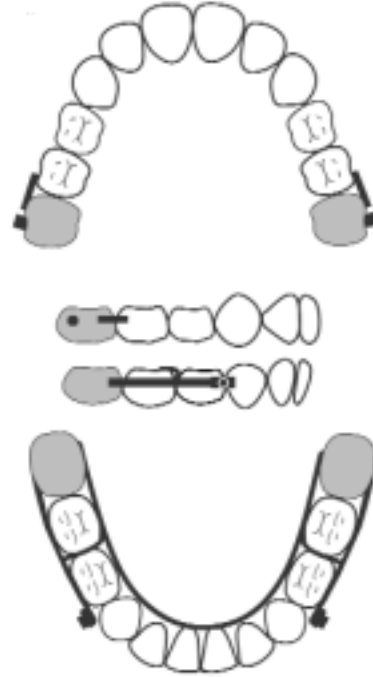
Herbst Designs

**Damon Standard Herbst
Mixed Dentition**



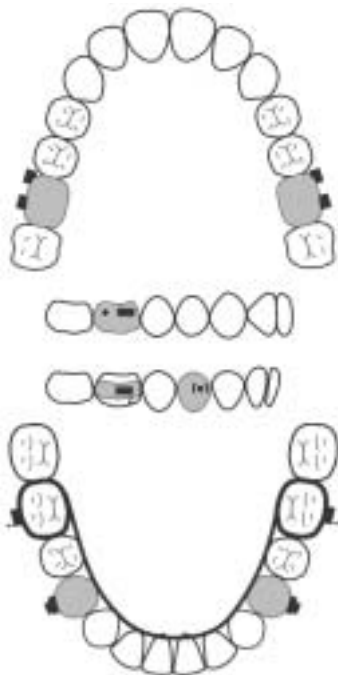
**Crossover wire is placed
between D/E**

**Damon Standard Variation
Mixed Dentition
(Used when gaining space)**



**Upper archwire tube is
extended distal to E**

**Damon Standard Herbst
Permanent Dentition**



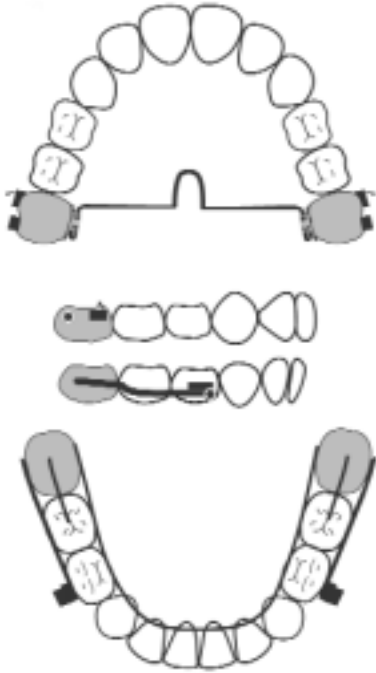
Other Treatment Modalities for Consideration

Dr. Damon rarely adds an expander to his Herbst appliances. His treatment protocol allows the Herbst to act like an expander in achieving overall arch development. The appliance is built with an initial 4 to 4.5mm of advancement. The patient remains at this position for 20 weeks. Further advancements are in 3mm increments until the patient reaches an end-to-end relationship. Using this method of advancement, Dr. Damon gains 7 to 8mm of expansion. Total Herbst treatment time is approximately 14 months. This protocol is in keeping with his philosophy of using slower, more-natural forces to achieve optimal orthodontic treatment results.

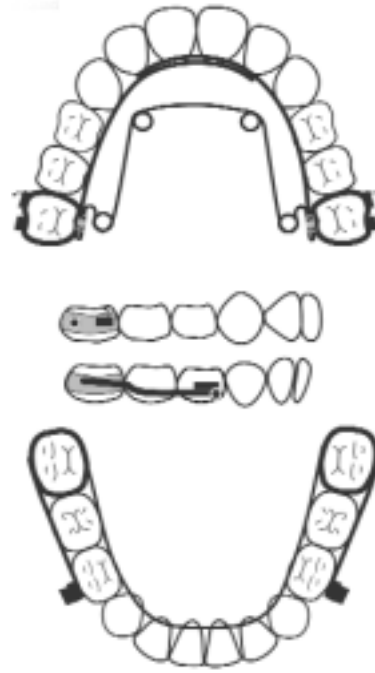
Dr. Duane Grummons

Herbst Designs

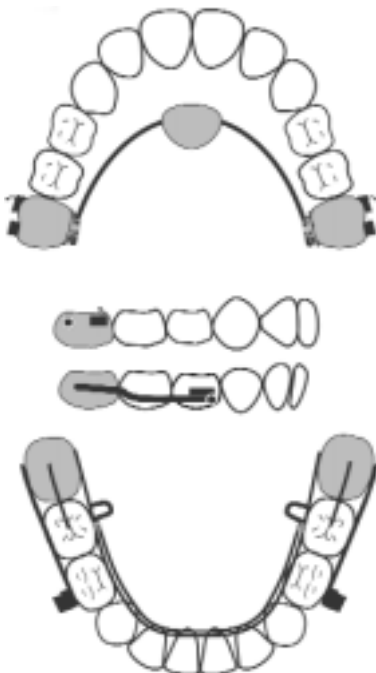
**Grummons Herbst
with Upper Removable TPA
Fixed Lower Lingual Arch**



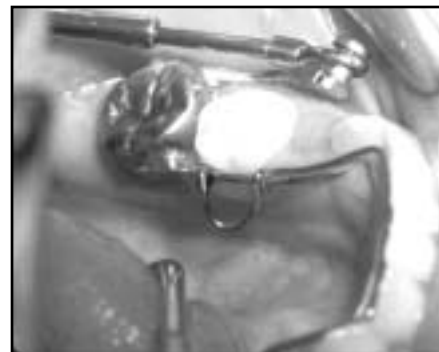**Grummons Herbst
with Upper Removable Quad Helix
Fixed Lower Lingual Arch**



**Grummons Herbst
Upper Removable Nance
Fixed Lower
Double Lingual Arch**

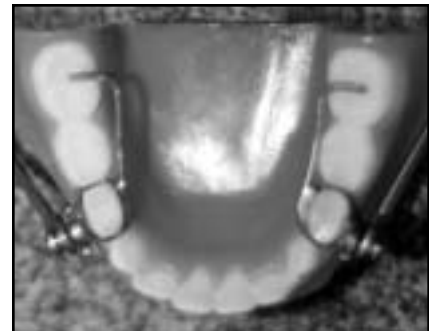
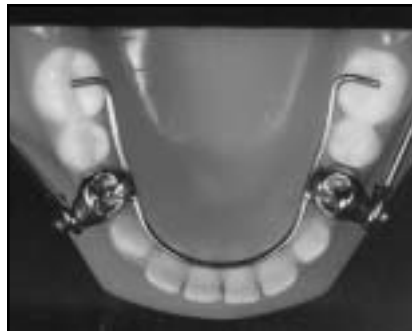
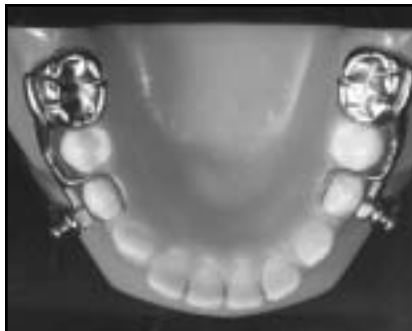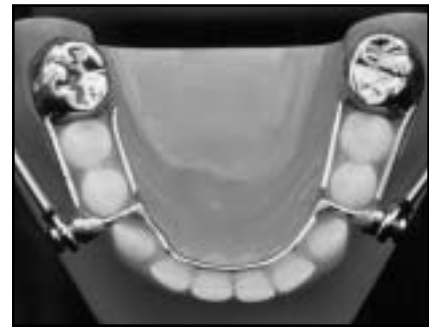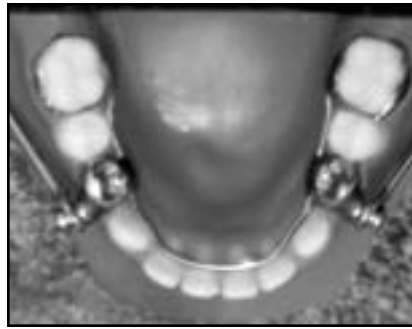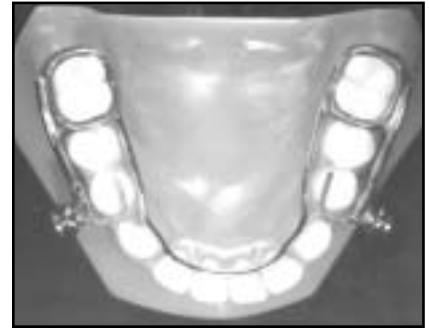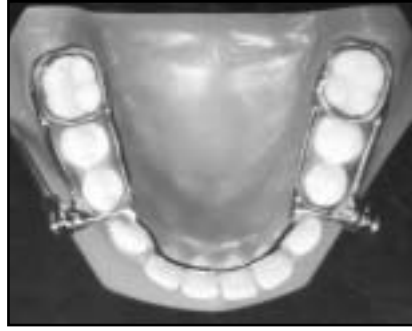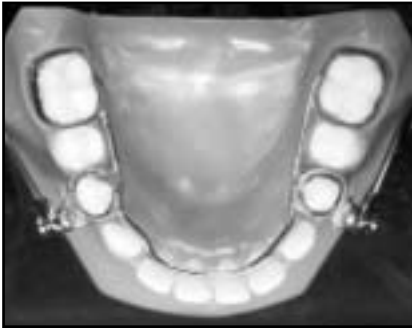Special Feature

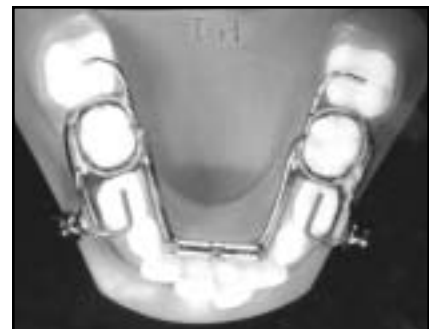
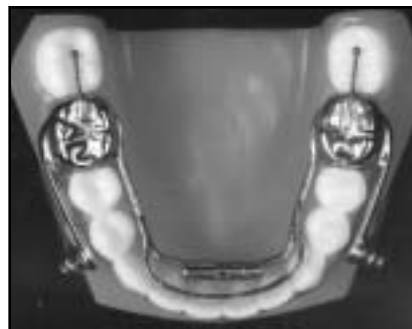
Lower appliance modified with fixed double lingual arch incorporating a loop to gain space.

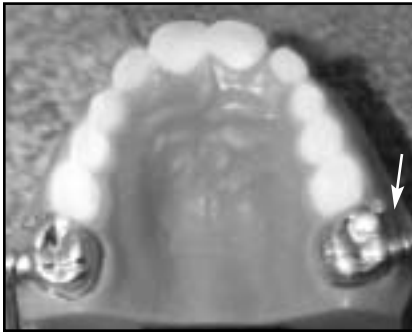Lower Arch Herbst Design Variations



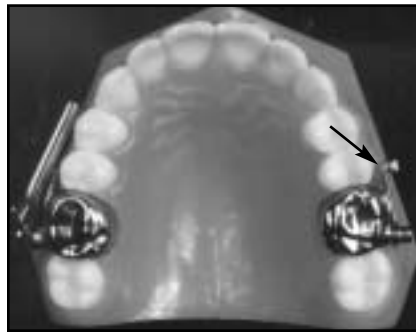
Lower Expansion Variations



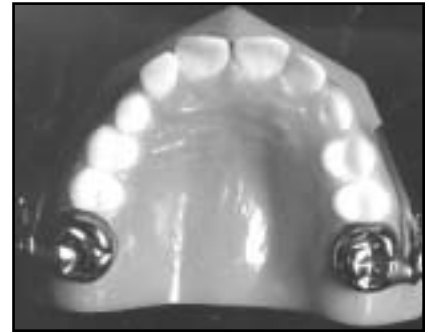Upper Arch Herbst Design Variations



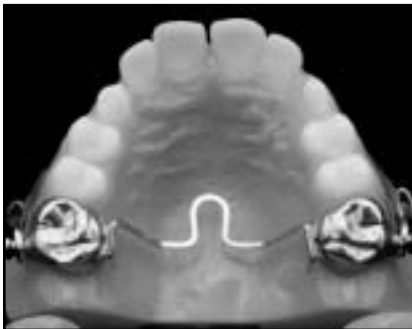Mesially placed archwire tubes.



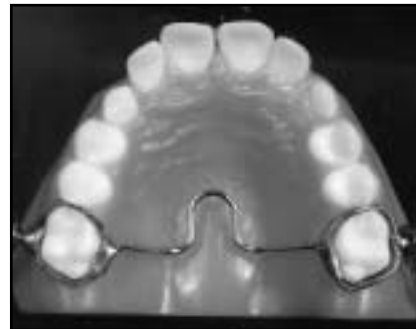
Extended archwire tubes.



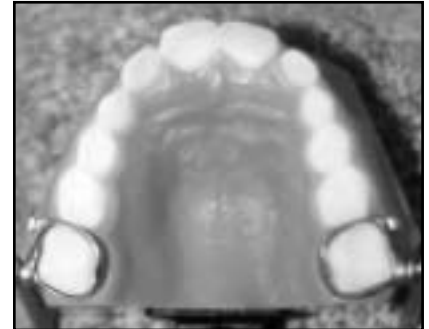
No archwire tubes.



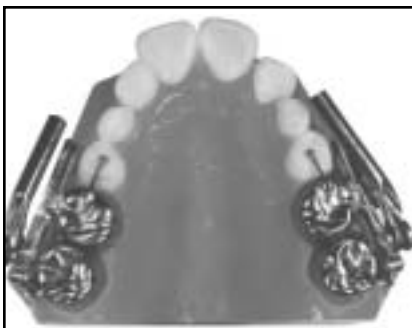
Crowns with removable TPA.



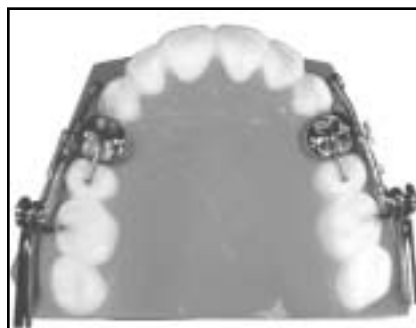Reinforced bands with TPA.



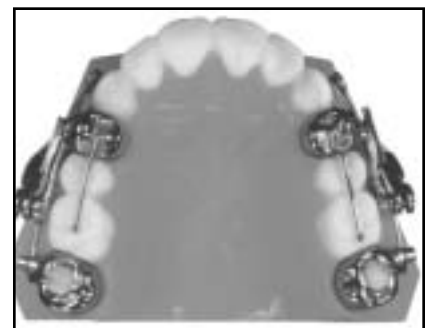
Reinforced bands with AWT.



Intrusion wire to first molars.
Mixed dentition.

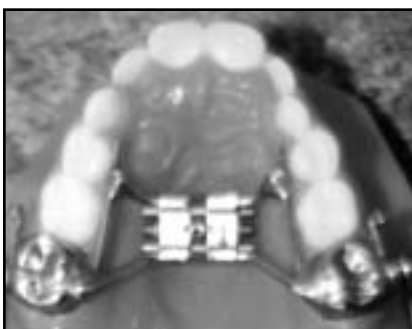

Intrusion wire to first molars.
Permanent dentition. (#1 of 2)

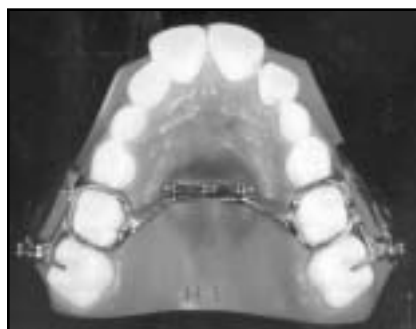

Intrusion wire to second molars.
Permanent dentition. (#2 of 2)

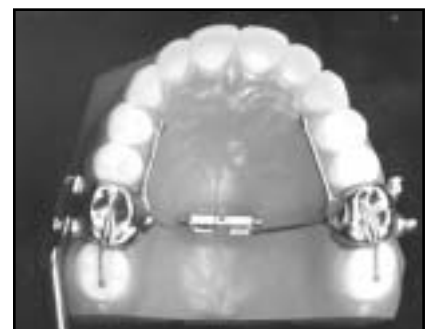Upper Expansion Variations



Hyrax RPE with extended archwire tube.



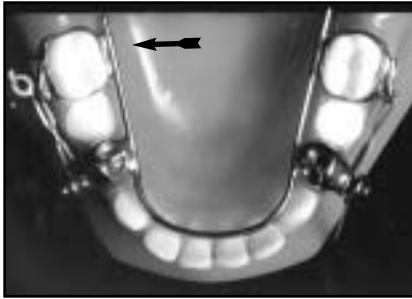
Banded design to E's with
Compact RPE screw.



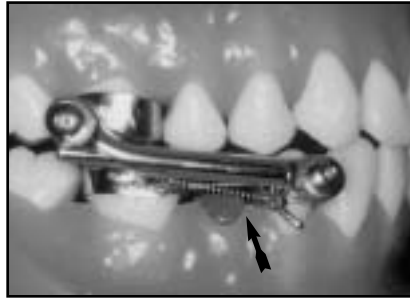
Compact RPE with lingual
extensions.

Hybrid Herbst Design Variations

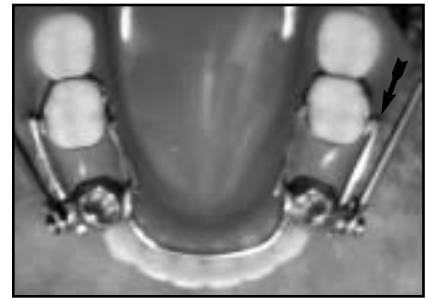Space-Closing or Molar-Protraction Designs



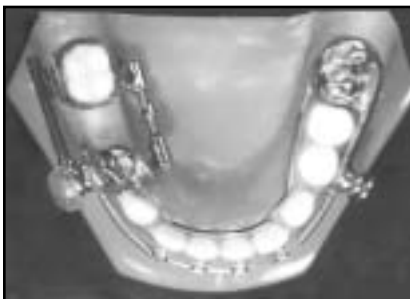Sliding tube attached lingual.



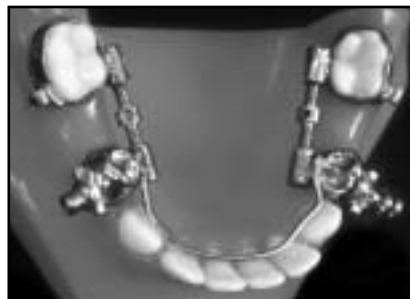Buccal View with closing coil.




Sliding tube attached buccal.



Small screw used for unilateral closure on the lower arch.

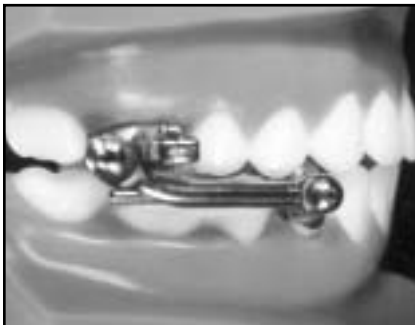

Small screw used bilateral closure on the lower arch.

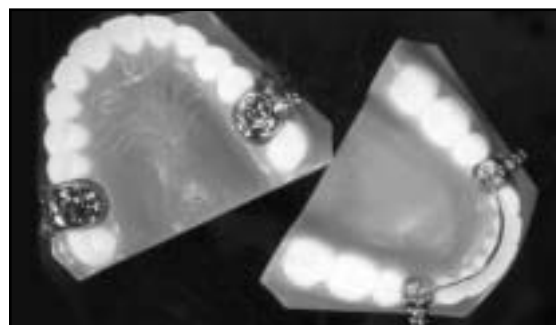

Small screws available for space-closure appliances.

Brachycephalic Herbst Design

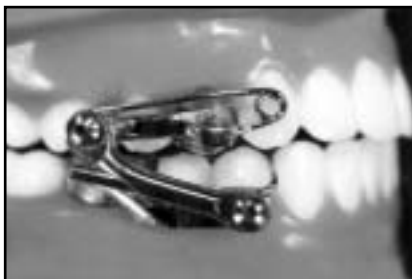

Side view.




Upper and lower occlusal view.

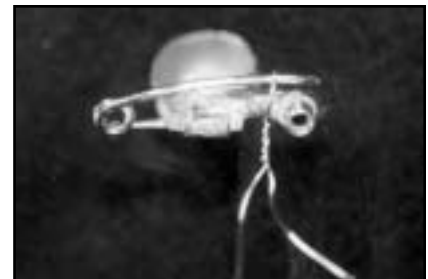Intrusion Herbst Design



Designs vary according to treatment plan and dentition.



Upper intrusion wire activated 90° and secured for delivery.



Enhancement and Options Corner

Through clinical experience, communication and a willingness of the orthodontic manufacturers to develop products that affect efficiency, reliability and patient comfort, great strides are constantly being made to perfect the Herbst mechanism and appliance auxiliaries. Listed are a few of the latest improvements offered.

The Offset Rods

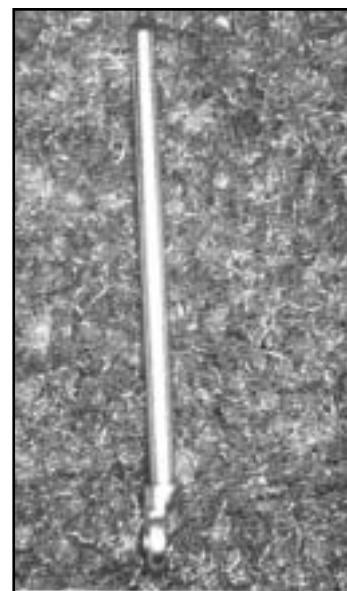
Ormco has developed the offset rod to, first, eliminate soft tissue irritation. The design uses the rod-tube assembly to keep the cheek away from the screw head on the lower unit. Second, it is made from a more rigid stainless steel, decreasing the possibility of the rod bending, and third, the lumen has been enlarged. As with the original Ormco mechanism, it is recommended to place a posterior separator over the axle before attaching the rod. This will hold the entire assembly out and not allow the pressure of the cheek to push the assembly in, making the screw head stand out, which will irritate the cheek.

There is not a right or left rod but there is an in-and-out side to the design.

Larger 5.5mm Screw Head

This screw head was designed to increase patient comfort. The original screw head is 4mm, which is still available. There should be no problem interchanging screw-head sizes with Ormco axles.

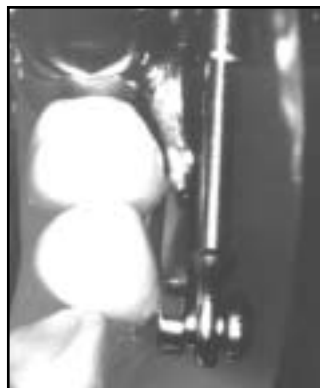In some expansion cases it has been found that the lower rod may hit against the upper 5.5mm screw when the patient closes. In this case, exchange for 4mm size.



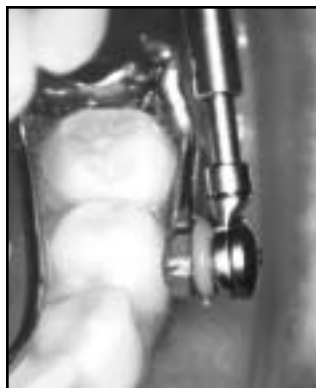Offset rod.



Original 4mm and new 5.5mm screw heads.



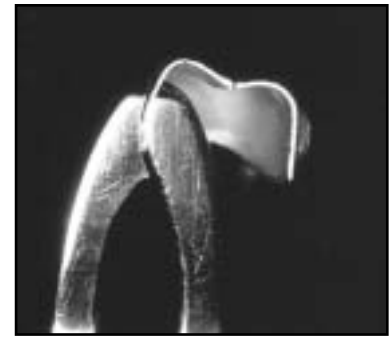
Original rod and screw head.



Offset rod and larger screw head.

Crown Crimping Plier:

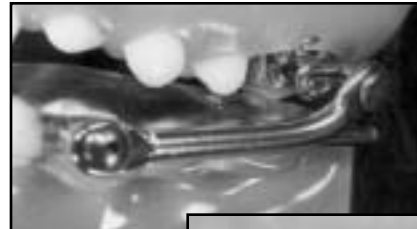Festooning or reshaping the crown's peripheral borders has been a problem because most offices used any plier that would crimp the edge of the crown, which could lead to misshaping them. This plier has been needed for a long time and seems to be working very well. (AEZ/Ormco)



Herbst Mechanisms:

In addition to the Ormco Herbst mechanism, there are several other types available, such as the Atlas Axle, Malu and the Flip-Lock* from TP Orthodontics, Inc.

AOA/Pro offers all these variations. Indicate which style mechanism is preferred on the prescription sheet.



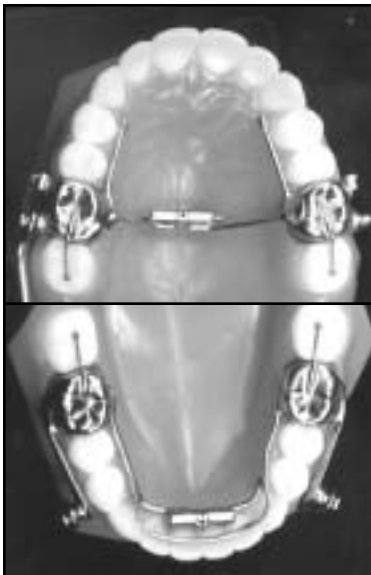
Malu



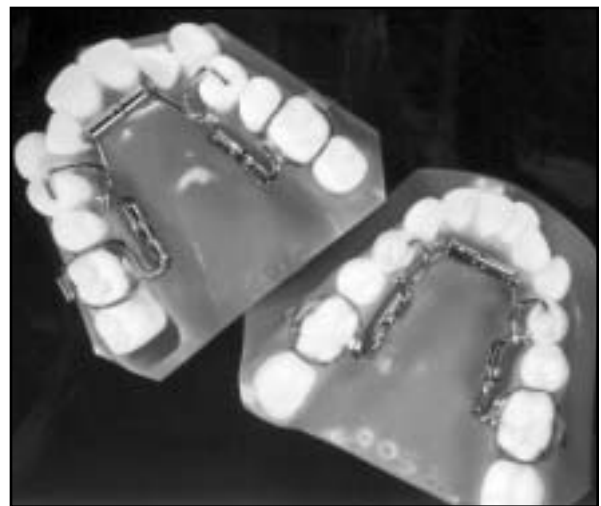Flip-Lock

Small (Mini) Screws:

As the Herbst is used for multifunctional purposes, such as space closing and expansion in younger patients, mini screws have been designed for ultimate patient comfort. These screws are used in maxillary and mandibular arches and accommodate Herbsts as well as arch-development appliances.



A variety of mini screws are available. Ask AOA/Pro which screw is best suited for your case.



These small screws are ideal for molar distalization cases requiring transverse expansion.

* Flip-Lock and Grip Tite Plus are registered trademarks of TP Orthodontics, Inc.

Prefabrication Preparation for the Herbst

Diagnostic Records

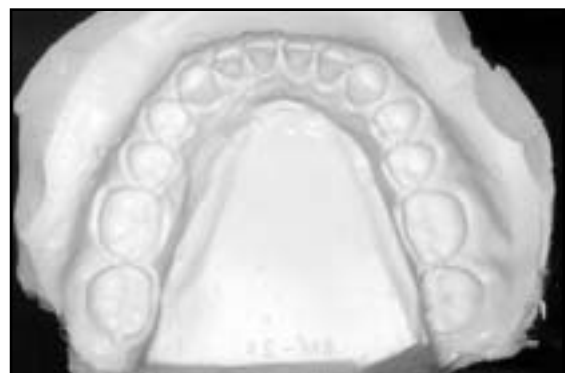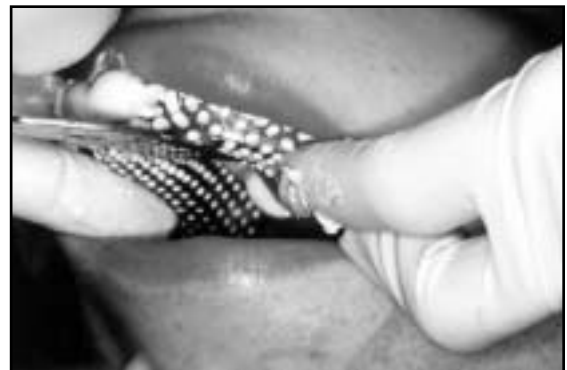Diagnostic records requirements are as diversified and unique as the clinicians' diagnoses. Listed below is a compilation of recommended records.

- Cephalometric x-ray
- Submental vertex x-ray for tomogram
- Transcranial or tomogram
- Slides, photos or imaging
- Impressions for diagnostic study models
- Diagnostic wax bite
- Take second set of impressions for Herbst appliance fabrication
- (May duplicate original diagnostic models if they are in perfect condition)

Note: When sending your appliance to AOA laboratory and they are to indirect fit crowns or bands, you will not have to separate the patient for space between the permanent or primary molars and/or second permanent bicuspid before taking work model impressions. The lab will disc the teeth during appliance fabrication. Separators should be placed between the patient's teeth one to two weeks before the delivery appointment.insertion.

Impressions for Work Models

Maxillary and mandibular alginate impressions are required for the working models. Impressions must be free of distortions, bubbles and voids. Perforated or metal impression trays are recommended when taking impressions directly on the patient. Disposable trays may be used with care (when duplicating arches from diagnostic study models), because they have a tendency to distort. It is important to keep in mind that the laboratory technician can make an appliance to fit only the models you provide and it all starts with the impressions. To create work models, pour impressions in orthodontic stone.



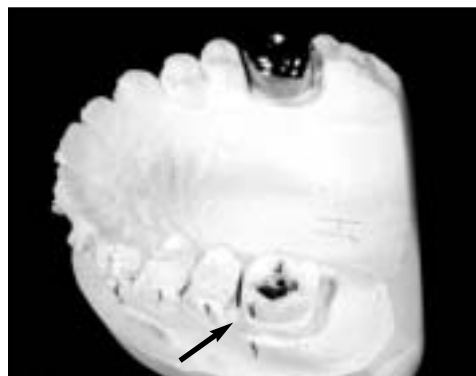
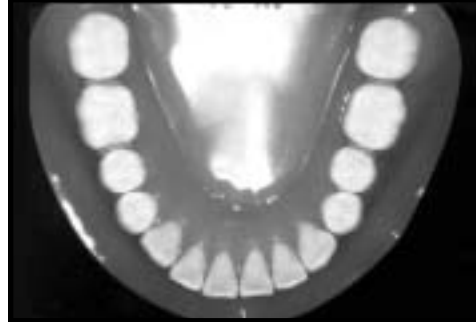
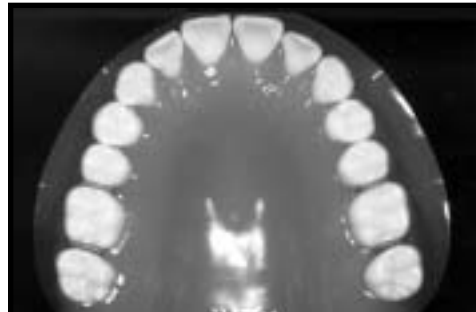
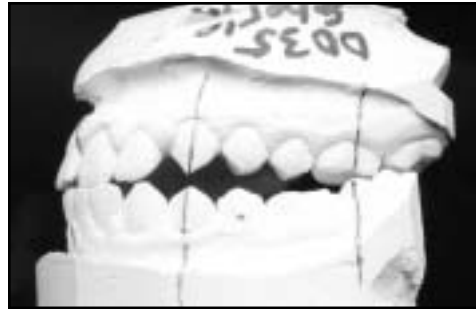
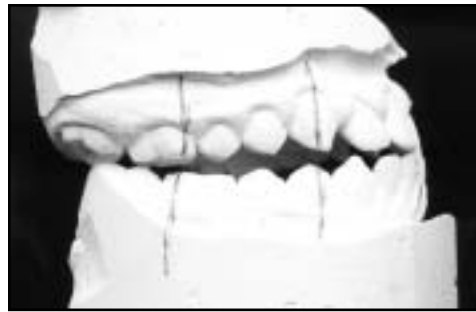Bite Registrations

Wax bite registrations are not necessary when fabricating a crown or banded Herbst unless the clinician just feels more comfortable providing one to the laboratory technician. Work models may be hand articulated and marked indicating the prescribed incisor and molar relationships in the advanced position. The exception would be if an acrylic splint were to be incorporated into the Herbst design. Then a wax bite registration would be required to construct the appliance, taking into consideration the vertical dimension.

Placing Separators

Exact placement of the separators will be determined by the design of the Herbst being used. Improper separation, particularly when permanent second molars are present, can result in loose crowns/bands during treatment. Separators are placed one or two weeks before the appliance is inserted.

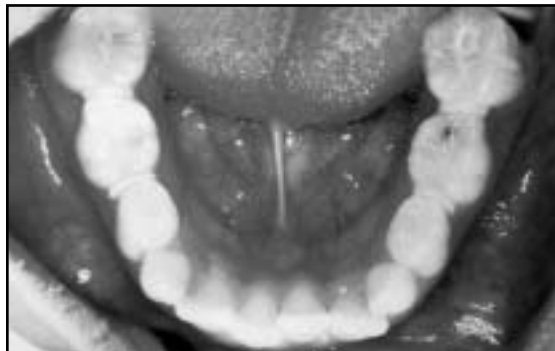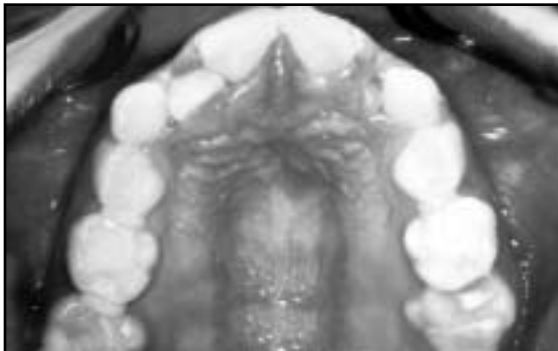
Note: If the laboratory is going to indirect fit your crowns or bands, you do not need to separate the teeth before taking impressions for the work models. The lab will disc the model when fitting the crowns. If separators were placed at the time impressions were taken, schedule the patient to return one week before appliance delivery to place or replace lost separators to ensure there will be plenty of space on delivery day.



Work model with tooth disced for crown or band placement.

Design Exceptions that Effect Separator Placement

Place the crowns or bands on the lower second primary molars, even though the first permanent molars are present. This usually occurs if the operculum covers the distal of the lower first molar. Always check the panorex x-ray to make sure the second primary molars are securely anchored.

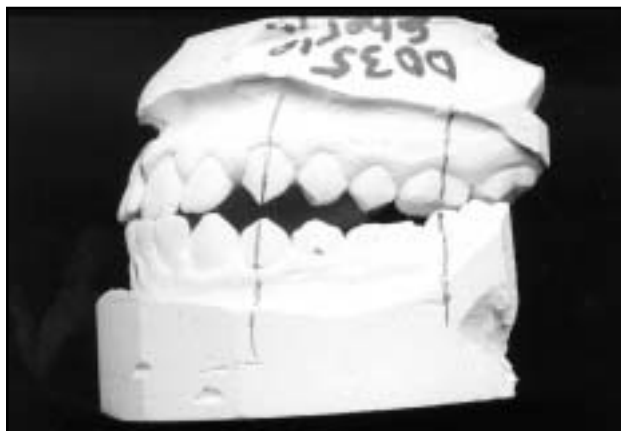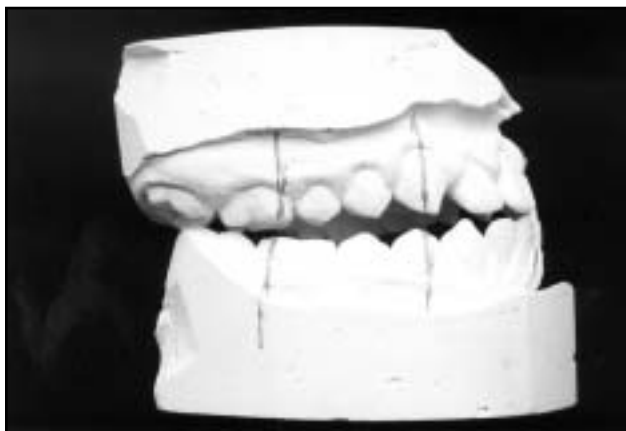


The patient may present with a very small vestibule and not have enough room in the back cheek area to accommodate the Herbst axle if placed on the first permanent molar. In this case the appliance is often fabricated more mesial in the posterior section of the mouth, using the second primary molar.

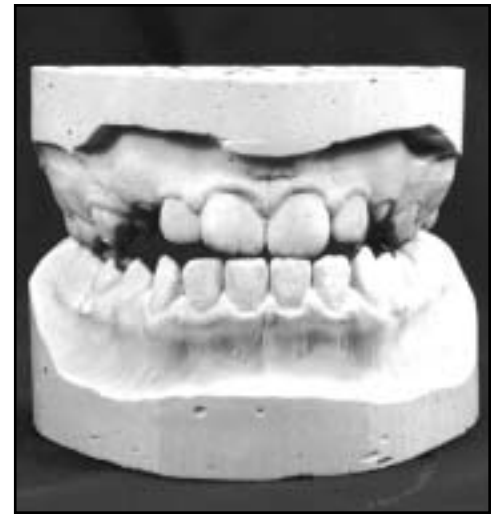Work Models for Appliance Fabrication

Crowns/Bands Furnished and Placed Indirect by Laboratory Technician

Pour impressions in hard orthodontic stone. The models must be free of voids or distortions. Hand articulate the work models into the advanced position, usually a Class I, edge-to-edge. Mark advancement guidelines on the models in pencil (upper and lower). The laboratory will use these lines to mount the models to your prescription.

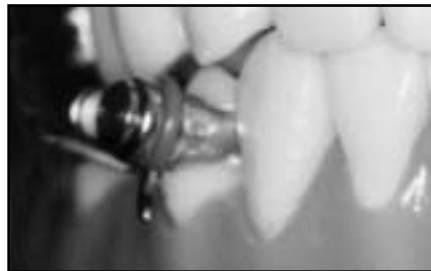
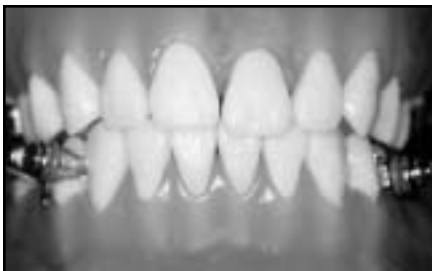
Note: If the patient's models are in a cusp-to-cusp relationship or in a cross-bite when articulated into the advanced position, this is an indication that the maxillary arch is too narrow. The patient will need to have the upper arch expanded before placing the appliance, or an expander can be incorporated into the appliance during fabrication. If the patient's maxillary arch is too narrow, the rods and tubes on the bite jumper will bind, impinging on the lower crowns or lower posterior teeth. If the appliance is a cantilever style, the upper tube will not close over the cantilever and the patient will not be able to close their mouth. The laboratory should recognize the problem during the fabrication process and call to discuss options.



Pearl: If the expansion problem is not discovered until after appliance delivery and the expansion required is minimal, you may be able to continue with Herbst therapy by adjusting the appliance as follows:

- Reduce the initial advancement by 2mm to accommodate the molar relationship and allow the patient to close.
- Due to the functional mechanics of the Herbst, you get a natural mesiobuccal rotation to the upper molars resulting in up to 1.5mm of expansion. The combination of reducing the initial advancement and this minor expansion affect should allow you to fully advance the patient at the next appointment without the tube and rod mechanism binding. Future advancements should not be effected.
- A large separating elastic can be placed over the axles on the upper and/or lower crowns/bands. Then place the tubes and rods over the elastics and secure with a screw. This procedure will move the tube and rod assembly outward, allowing the patient to close.



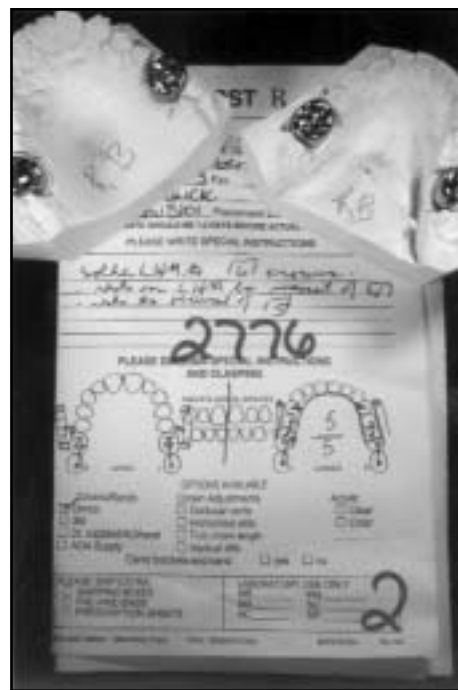If the upper arch seems not to be an issue and there is a slight binding of the mechanism, place separating elastics over the lower axles. If still binding, place over the upper axles as well.

Prescription Considerations

Before sending work models to the laboratory, a few minutes should be taken to reference them to the prescription sheet for design specifications. The clinician or clinical coordinator needs to make sure the models and prescription sheet has been marked properly. Prescription sheets sent to the laboratory should be filled out in detail. Drawing out design modifications on the prescription sheet along with written instructions keep technical conceptual errors to a minimum.

Crowns

Currently there are three types of crowns on the market suitable for Herbst fabrication: Ormco crowns, 3M stainless steel crowns and 3M Ni-Chro crowns. All have characteristics unique to the way they fit on a tooth. The 3M crowns are shaped with a long, narrow base, giving it a rigid, tight “snap fit” feel. These crowns usually require more trimming. When fit properly, Ormco crowns have a looser “snug fit” feel but do not slip off the tooth. Ormco crowns are routinely recrimped or contoured immediately prior to cementing on the tooth, ensuring a tight fit at the gingival margin.



Commercial laboratories have a tendency to favor certain crowns. If a crown has a different feel, ask the laboratory what type of crown they are using routinely. If their crown is different from what you are accustomed, request the laboratory to provide the type of crown your office prefers. *(AOA laboratory routinely uses Ormco crowns but will provide 3M crowns upon request.)*

Note: Operculum tissue over the distal of the lower first molars is the most common cause of incorrect crown adaptation. In this situation it is recommended that (1) the lower first molars be sized with bands allowing the lab technician to use them as an aid in identifying the molars' distal cusps hidden under the tissue or (2) an operculumectomy be performed. *In this early stage of development, it is usually easier to crown/band the deciduous E's.* If this is a consideration, check the panorex to make sure there is enough root support on the primary molar to hold the crown through treatment.

Bands

Bands like crowns can be indirect fit by the laboratory. However, it is preferable for staff or clinicians to fit their own bands. Most bands are made of .007 material and need to be reinforced during Herbst fabrication with extra band material or an occlusal support wire soldered around it for stability. Even with these modifications, appliances fabricated with .007 band material have a high rate of breakage. TP Orthodontics, Inc. has developed a heavier band (GRIP Tite Plus Band) out of .010 material that has proven very successful in reducing breakage when using a banded Herbst. *(AOA-Pro routinely provides this band when asked to indirect fit bands for a permanent dentition banded Herbst.)*

Crowns/Bands Furnished and Fit Direct by Clinician or Clinical Staff

Crowns

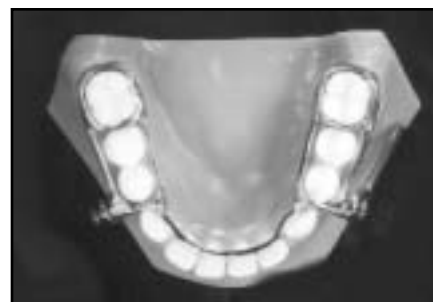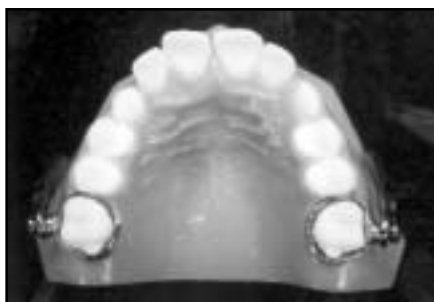Fitting your own crowns will require keeping an inventory. There are eight sizes of molar crowns of which four are used regularly. Most staff are accustomed to fitting bands, that are available in many sizes, however, because of the sizing limitations, crowns will not fit precisely. There will be a little play in them when seated. Currently there are three types of crowns on the market that are suitable for Herbst fabrication: Ormco crowns, 3M stainless steel crowns and 3M Ni-Chro crowns. All of these crowns have characteristics unique to the way they fit on a tooth.

Note: Since crowns are expensive and tend to distort when fitting, you may find it convenient to purchase a crown sizing kit to facilitate the fitting procedure. Ormco has a precontoured, pretrimmed trial Crown Fit Kit. These crowns have laser markings, can be sterilized and reused until they are beyond reshaping. When using the trial kit, you must use Ormco crowns to fabricate your appliance. If you are short on crown inventory, simply notify the laboratory to use Ormco crowns and note on the prescription sheet the patient's Ormco crown size for an accurate indirect fit.



Bands

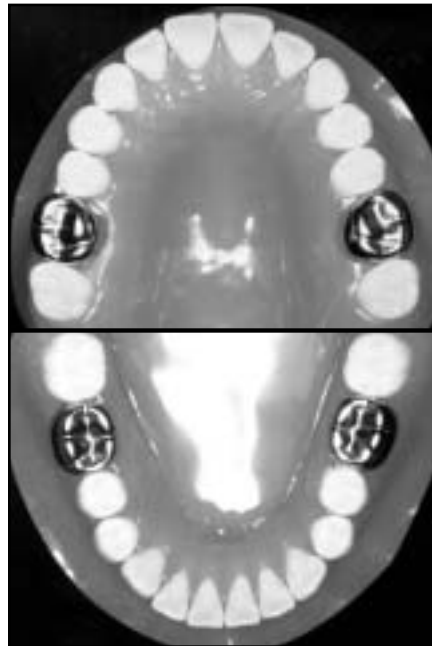
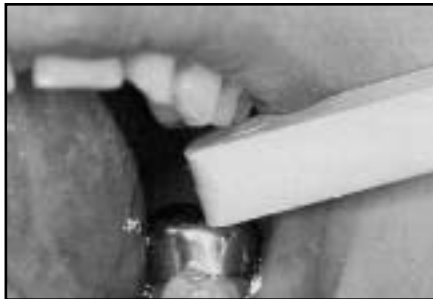Orthodontic offices usually have an inventory of bands in stock and it is easy to think that any blank molar or bicuspid band will work. Standard bands are made of .007 material and will need to be reinforced with solder, extra band material or an occlusal support wire soldered around it for stability. Even with these modifications, Herbst appliances fabricated with .007 band material have a higher rate of breakage. In response to this dilemma, several years ago TP Orthodontics, Inc. developed a heavier band out of .010 material (Griptite Plus Band) that has proven very successful in keeping breakage associated with the banded Herbst to a minimum. (AOA/Pro routinely provides the Grip Tite Plus band when asked to indirect fit permanent dentition bands for a banded Herbst.)



Upper and lower banded style Herbst using Grip Tite Plus bands and reinforced wire.

Clinician/Staff Direct Fit Crowns

1. Fit crowns on one tooth at a time and then remove it to prevent aspiration. Check size and length of crown. Starting with a size five crown and going up or down will help the novice in sizing.
2. The crown should slide over the tooth with some resistance and then slide down on the occlusal surface without pinching the soft tissues.
3. Once the crown has reached about three quarters of its seating position with thumb pressure, it is beneficial to use a bite stick to complete seating. Place handle portion of the bite stick in the central groove of the crown at an angle matching the cuspal incline and have the patient bite it down from there.
4. The crown can be removed with your fingers, an explorer, a scaler, or crown remover pliers. Use only crown remover pliers if your crowns have removal holes placed before fabrication. Otherwise you may misshape the expensive crown.



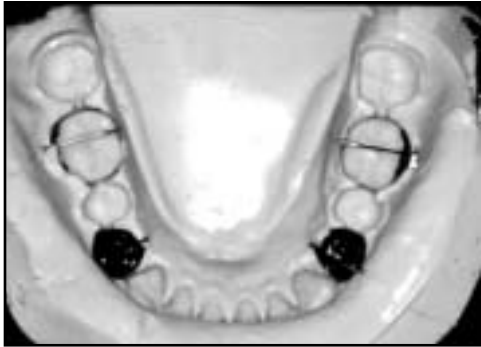Clinician/Staff Direct Fit Bands

1. Fit bands on the teeth being incorporated into the appliance design, sizing the band exactly to the tooth. Bands that fit too large will result in a loose Herbst appliance. Bands should be blank – no brackets, but lugs or cleats may be present to help with the fitting procedure.

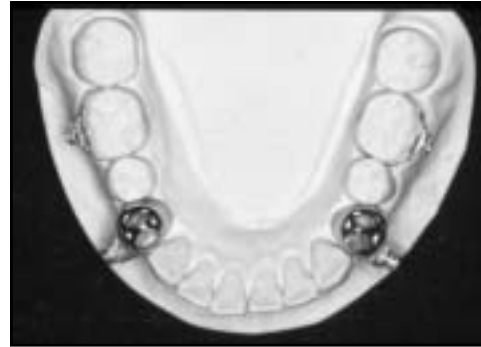Note: Use a heavier band such as TP's Grip Tite Plus band made out of .010 material, which will help reduce breakage. *This band is not currently available (12/01) for primary first and second molars. AOA/Pro will reinforce your primary teeth bands before fabricating the Herbst.*

Impressions and Work Models when Clinician/Staff Fit Crowns/Bands

1. *Crowns/bands incorporated into the work model* will require that the impressions be taken with the crowns/bands seated on the teeth. Remove crowns/bands and place in impressions, securing with wax or a pinning technique to ensure that they do not move while pouring the stone.



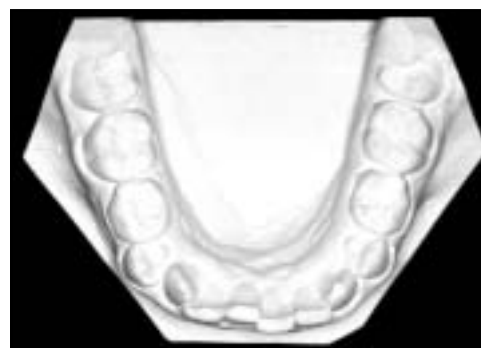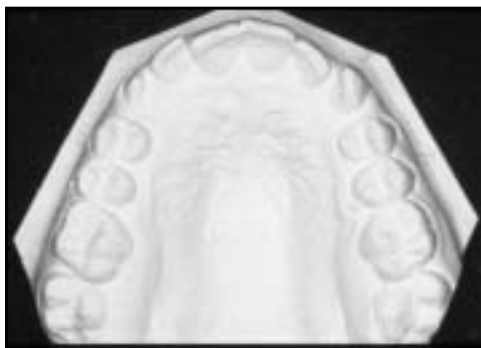
Lower impression of a Smith Type II Herbst with crowns and bands held in place with short pieces of stainless steel wire.



Lab working model for Smith Type II Herbst with crowns and bands in place. (The crowns used for this photo are from the prefabricated CBJ kit.)

Notes:

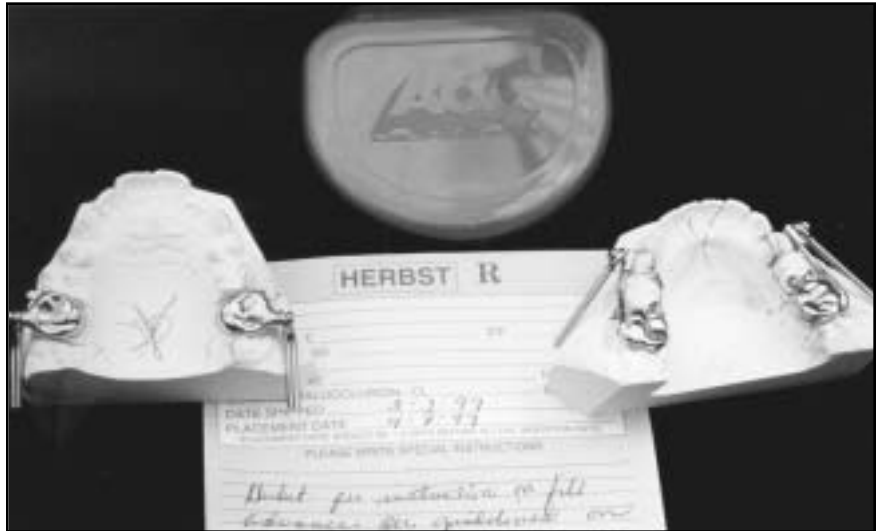- Due to the smooth form of the crowns, they can easily be placed in impressions backward or switched from right to left.
 - Superglue is not recommended to secure bands or crowns in impressions because often the glue runs into archwire tubes or slots. The superglue releases a powerful odor and gas when heat is applied during the soldering process.
2. *Your direct-fit crowns/bands to be placed indirect on the work models by the lab:* This procedure will require that the fitted crowns/bands be removed from the teeth prior to taking impressions. Crowns/bands to be refit on the work models by the laboratory should be sterilized, identified, bagged and the bags stapled to the prescription sheet. Work models are poured in hard orthodontic stone. *(AOA/Pro prefers this procedure because it eliminates errors associated with pouring work models resulting in crowns/bands floating out of position. Most Herbst appliances that do not fit initially can be traced back to (1) bands floating during pouring of the work model and/or (2) inaccurate impressions.*



Delivery of the Crown/Banded Herbst

Pre-Insertion Checklist

1. Several days before the patient's appointment, check to make sure you have the appliance and its components back from the laboratory. Review the prescription sheet to determine that the appliance has been made to specification and make sure the work models and appliance identifications match the patient.



Never discard work models until after the appliance has been inserted. If there is a problem, the original work models will need to be returned to the laboratory along with the appliance and a new set of work models. This procedure ensures quality control for both the laboratory and your practice.

Herbst Accessory Kit

Every office should have an accessory kit. A starter kit will give you an ample supply of Ceka Bond, spare Herbst components and advancement shims/bushings. Ceka Bond, component parts and shims/bushings can be reordered from AOA/Pro, or larger quantities can be provided through your Ormco representative.



2. Check the appliance for accuracy before the patient's appointment. Adjustments to the tubes and rods made prior to the delivery appointment can save time on clinical production schedules.

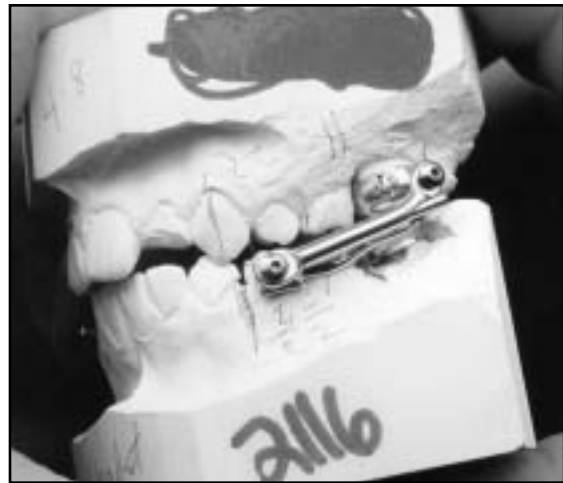Place the crowns/bands on the work models. Line up the guidelines on the upper and lower models or check the prescription sheet for the advancement requested.

Place the upper tubes and lower rods into the axles passively (placing screws is optional).

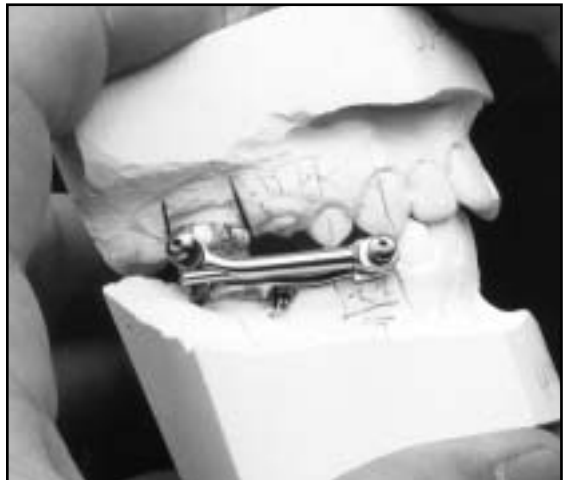
When engaged, the upper tubes should be long enough to hold the advancement of the mandible as prescribed, and the lower rods should ideally end in the center or just distal to the screw housing, not beyond.

Rods and Tubes Too Short or Too Long
When the upper tubes are too short (which is rare), it is an indication that the appliance will not advance the patient properly and the appliance may disengage. When the lower rods are too long, they impinge on the soft tissue in the back of the cheeks.

Note: When elongating an upper tube, you will probably need to lengthen the lower rods at the same time. If the lower rods are not lengthed, the patient will most likely disengage upon opening.

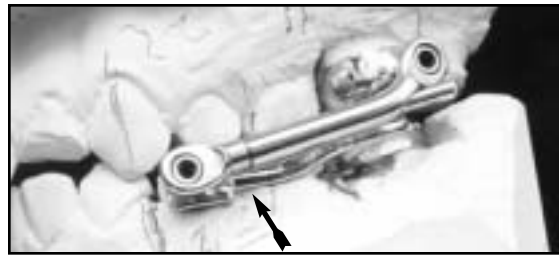


Tubes and rods are the proper length. Advancement is correct.



Upper tube is too short.

Minimal Adjustment – If the upper tubes need minimal adjustment and the lower rods are long enough, you may be able to add a shim to the lower rods to compensate for the upper tubes being too short.



Minimal adjustment corrected with a shim/bushing.




With models in the appropriate advanced position, tubes are marked to reflect the correct length.

a. Upper Tubes Too Short or Too Long

If the tubes are too long, make the following adjustments; if they are too short, replace them with new ones and then make the following adjustments.

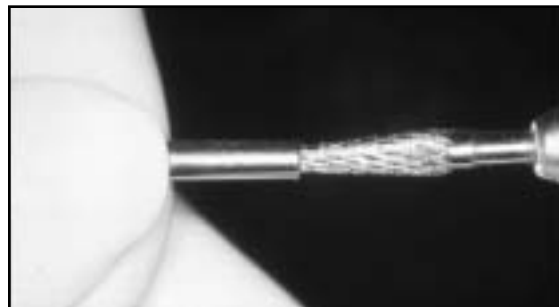- 1) Place the tube over the upper axle, line up the advancement guidelines and mark the tube for correct length.
- 2) Cut the tube with a disc or 1171 bur and smooth the edges with a heatless stone or rubber wheel. Rout the tube to remove any burs, allowing the lower rod to slide easily when inserted into the tube.



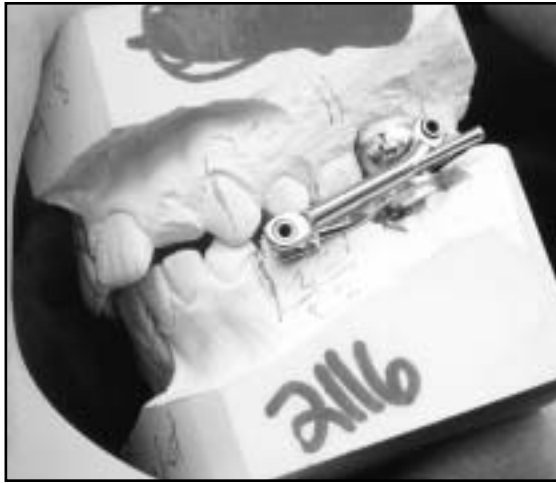Tube cut with a disc.



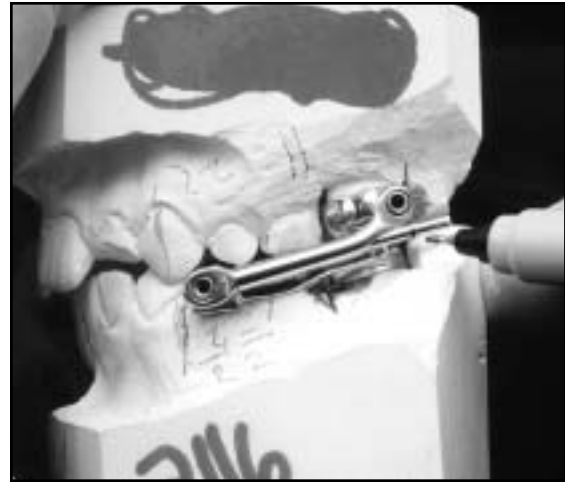Edges smoothed with heatless stone or rubber wheel.



Tube routed to remove burs.



Lower rod is too long.



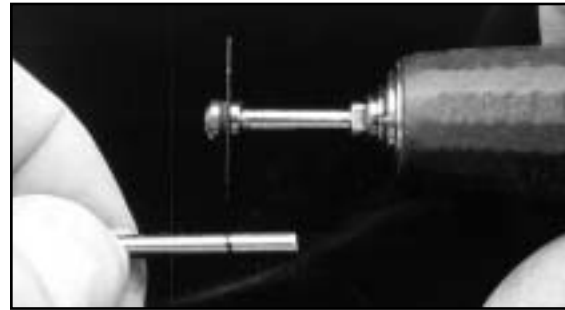
Holding the work models at the advanced position, the correct length is marked on the rod.

b. Lower Rods Too Short or Too Long

If the rods are too long, make the following adjustments; if they are too short, replace them with new ones and then make the following adjustments.

- 1) Slide the rod into the upper tube. Place the eyelets of the tube and rod assembly passively over the axles, holding the work models at the advanced position, and mark the correct length on the rod.
- 2) Cut the rod with a disc or cutting plier and round off the end with a stone or rubber wheel.

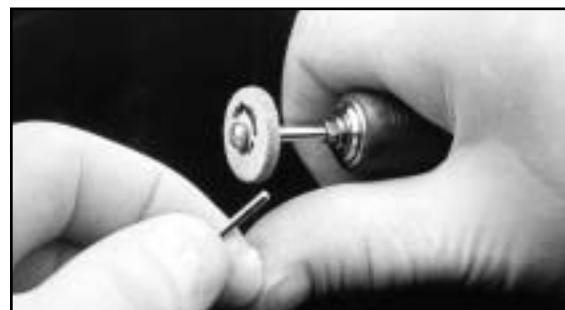Note: When using Ormco “offset” lower rods, an extra-heavy-duty cutter is required because of the strength of the material used to fabricate these particular rods.



Rod cut with a disc.

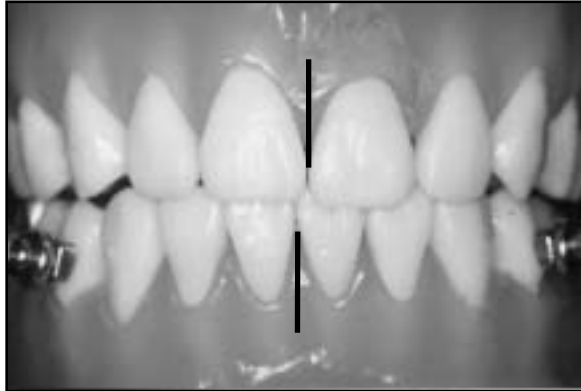

Rod cut with cutting plier.

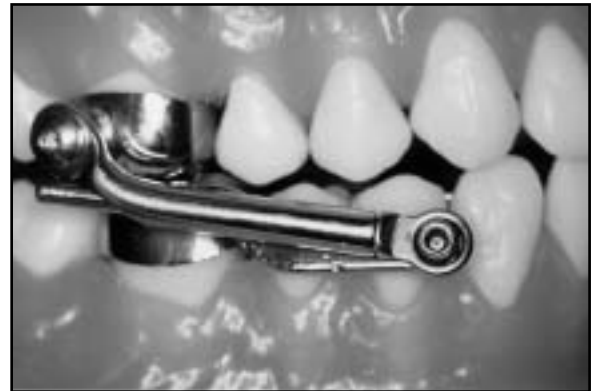

End rounded off with a stone disc.

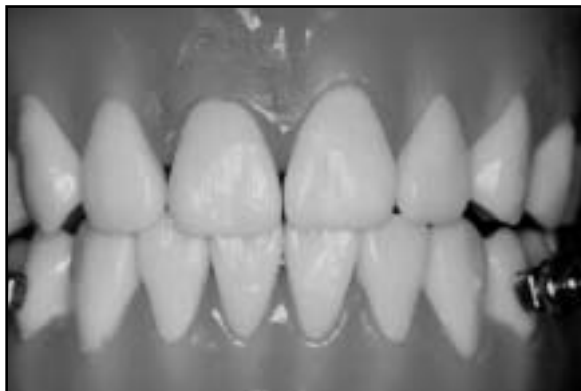3. Check that midlines are correct.



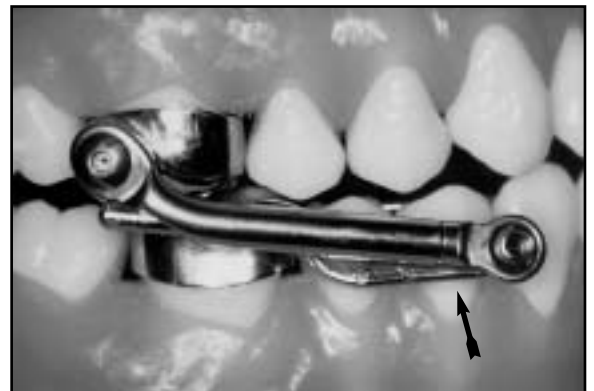
Midline off.



Midline off – buccal.

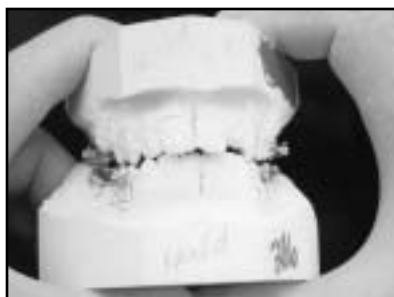

Midline on.

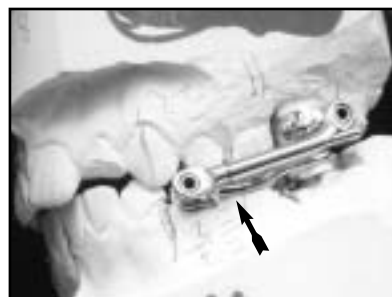

Midline corrected – buccal.

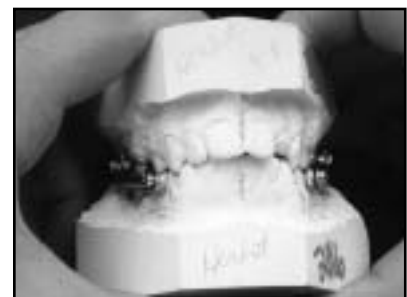If the work models show a deviation and the midlines are off, add a shim of the appropriate length to correct the discrepancy. As pictured below, note that the midline is off to the left, so a shim has been added to the left lower tube, shifting the mandible to the right and correcting the midline. Patients will occasionally present with this problem at delivery as well as later during treatment. Correction is easily made at the chair.



Right Left
Midline Off



Left Buccal
Midline Corrected

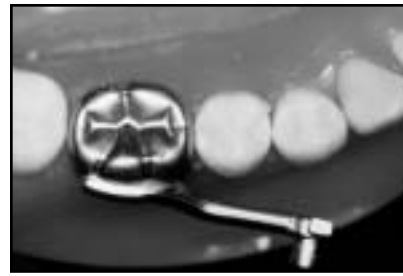

Right Left
Midline On

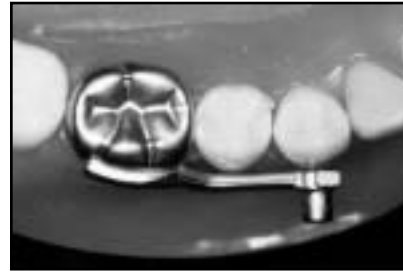4. If applicable, check that mandibular cantilever arms are aligned properly. If they are too far from the teeth, they will cause cheek irritation. If they are tipped too far inward, they will impinge on the gingival tissue.

It is very important to check for and correct this problem before cementing your appliance. If you notice a potential problem, correct as best you can and recheck once again when fitting on the patient before cementation. Once the appliance is cemented, you would most likely have to remove the lower crown and mechanism to correct, resulting in loss of patient confidence, time and money if the quadrant becomes damaged and has to be remade.

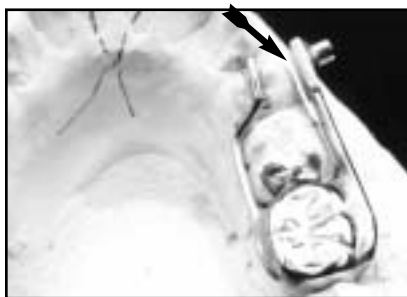Adjustments to the mandibular cantilever arms are usually made with three-prong headgear pliers or the CJB three-jaw plier from Ormco (AEZ). Any up-down, in-out, or torque corrections should be made at this time.



Cantilever arm out too far buccally.



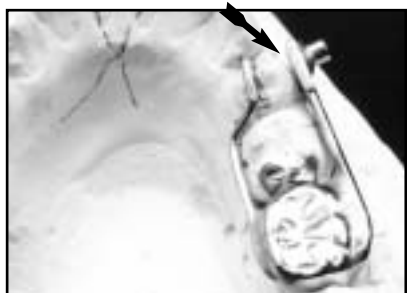Cantilever arm correct.



Right cantilever out too far.



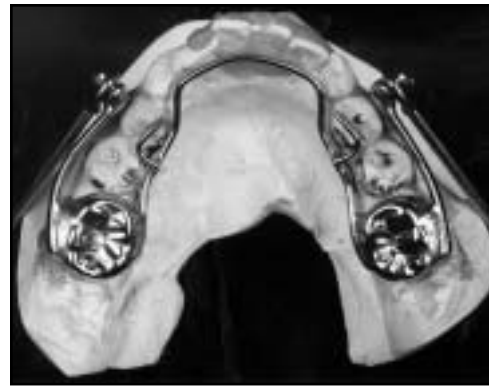Correcting with 3-prong plier.



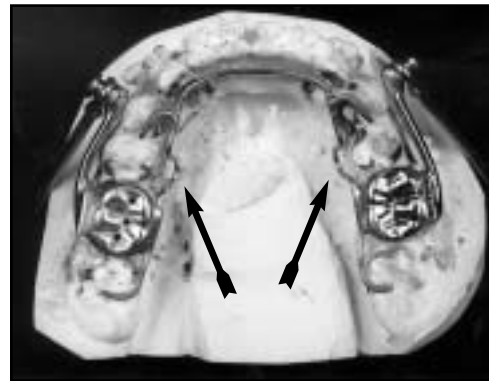
Right cantilever corrected.

5. If a lower lingual arch is present, check that the lingual arch is the correct width and is not expansive nor narrowing to the lower molars. The lingual arch should rest close to the cingulums of the lower incisors.

Incorporating an omega adjustment loop into the lingual wire during construction can simplify adjustments to the lingual arch and the fit of the lower appliance.



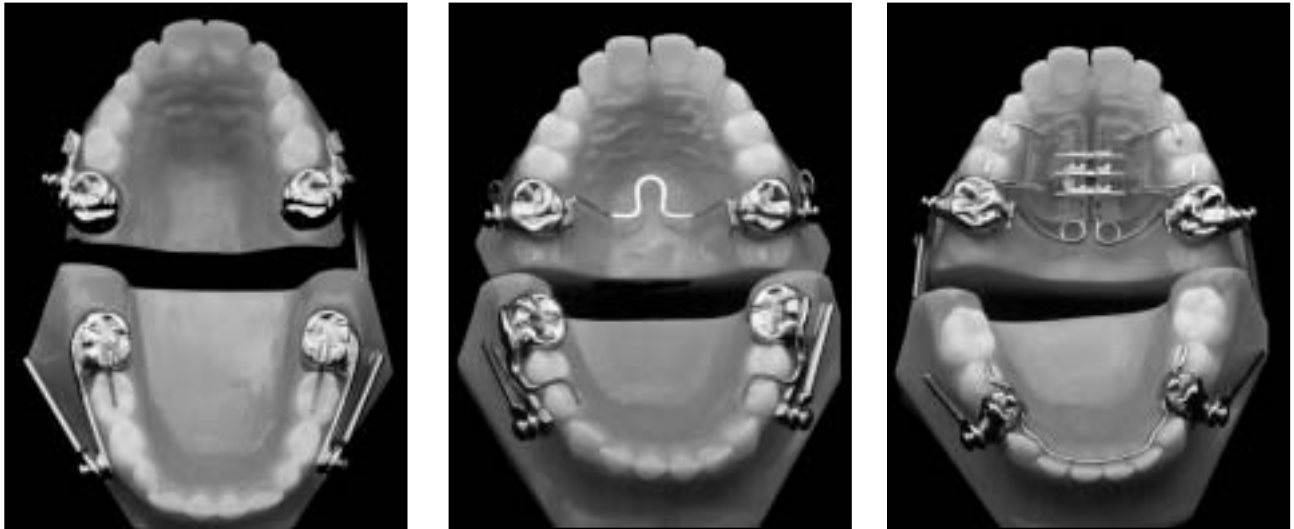Lingual arch.



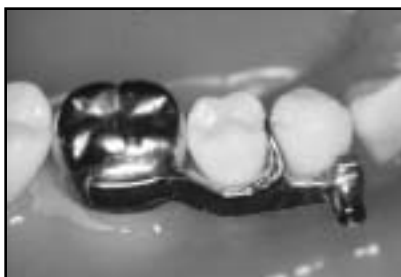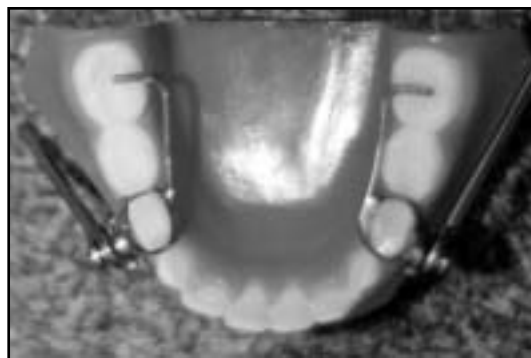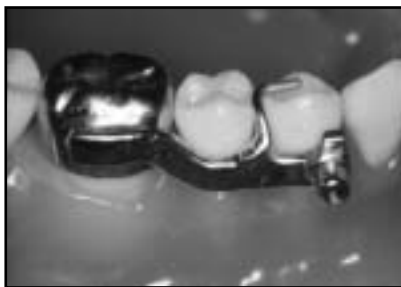Lingual arch with adjustment loops.

6. Check occlusal rests for their approximation to the teeth and then recheck at the trial fit of the appliance. Rests vary in design and function.

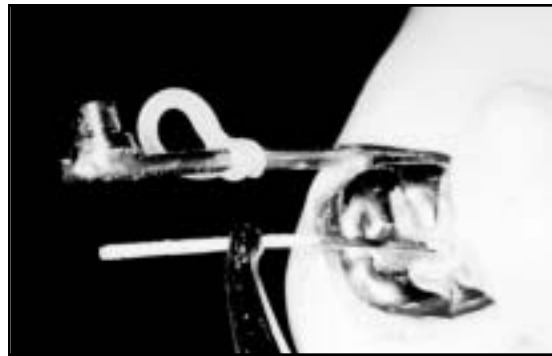Occlusal rests are sometimes placed on second molars to ensure that there is no supereruption of those teeth during Class II correction. Rests on lower permanent or primary premolars help keep cantilever arms from tipping and molars from rotating. Occlusal rests are sometimes used in conjunction with expanders to control molars from tipping and en-masse expansion of the entire arch.



Rests on the occlusal surface of upper or lower permanent first or second bicuspid, deciduous E's or D's and in a few designs on lower first permanent molars are usually secured with some type of composite material. As with crowns/bands, occlusal rests should be microetched to ensure a good bond. *(AOA/Pro lab routinely microetches all crowns/bands and rests).*



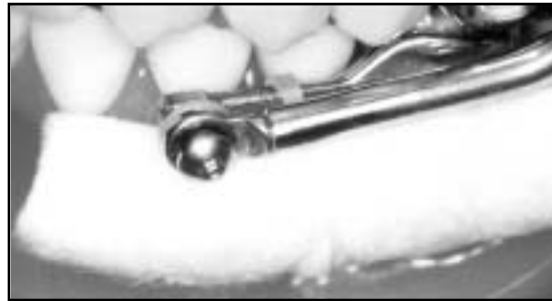Adjustments to occlusal rests are easily made with How or bird beak pliers. However, caution should be taken when adjusting rests because they can break if over annealed.



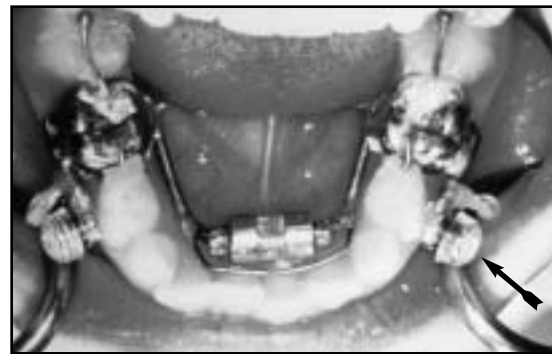
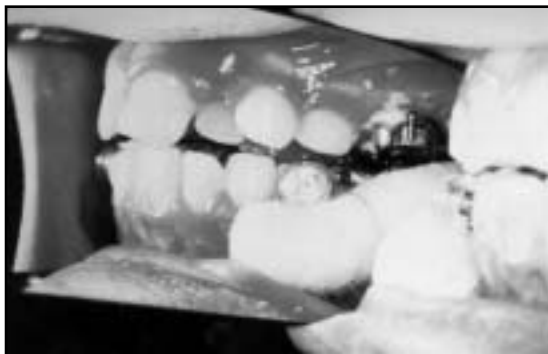Pearl #1: The addition of a ¼" diameter 6 oz elastic around the lower mandibular cantilever arms will allow the patient to place a cotton roll through the elastic, helping to alleviate any discomfort to the cheek area while the patient is getting accustomed to the appliance during the first week. The elastic will be removed once the patient feels comfortable with the appliance. Because of the cantilever arm's approximation to the gingival tissue, it is best to place this elastic on the cantilever prior to cementation.



Slip Knot



Pearl #2: Placing "comfort caps" over the screw heads enlarges the surface area of the screw/axle component, enhancing cheek comfort. These caps are especially useful during the expansion phase when the lower rods are not present. Comfort caps are opaque in color and are made of a plastic-type material. They are easy to use, as they roll on. It is helpful to place the caps in warm water prior to initial placement.



Herbst appliance with "comfort caps" and cotton rolls for maximum cheek protection.

7. Crown Removal Design Modifications (Optional)

Adding vertical removal notches, occlusal removal holes, or horizontal removal slits to the crowns can simplify crown removal. Requesting these modifications prior to fabrication will save time. If crowns are to be modified in the clinic after fabrication, it is suggested to remicroetch the crowns before delivery.

Vertical Removal Notch

Notching the crowns will make crown removal much easier. Most crowns are placed 1 to 2mm below or right at the gingival margin. Notching makes the crown more accessible and causes less patient discomfort. The upper crowns are notched approximately 1.5 to 2mm on the mesiopalatal, while the lower crowns are notched 1.5 to 2mm on the mesiobuccal, just lingual to the cantilever arm. These notches will eliminate the need to use a bur subgingivally if the crowns are to be sectioned, making the removal process easier on you and more comfortable for your patient. The notches also aid in crown removal when using a crown slitting plier.

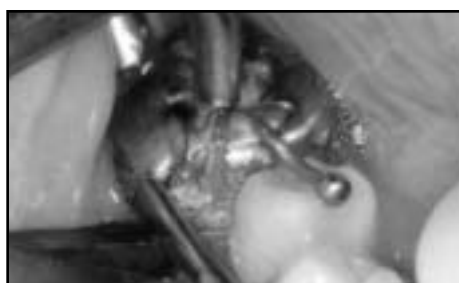Note: To add notches to the crowns, rotate disc or bur so spurs will be inside the crown. Be careful to stay within suggested guidelines. If the crown is notched too much, it could weaken and split over time.



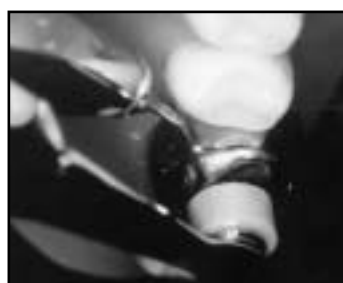Maxillary crown notched.



Mandibular crown notched.



Using notch to remove crown, first cutting then using crown removing plier.



Using notch to remove crown with a crown slitter.

Occlusal Removal Holes

Occlusal removal holes are placed in the occlusal surface of the crowns to aid in appliance removal, especially if a crown removal plier is going to be used. This hole can be made by the clinician at the time of appliance removal, however most clinicians find it easier to have them placed by the laboratory during fabrication. An occlusal crown removal hole is about 1/8" diameter.

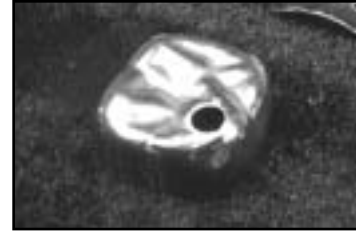Note: Do not confuse an occlusal removal hole with a "vent hole." Vent holes are much smaller and are requested to help extra cement escape from under the crown. Venting is not a necessary feature of cementation, but the name developed because of the venting observed during the cementing procedure. It is usually enlarged later to facilitate crown removal.

ALERT: Do not use Vaseline or ChapStick on the occlusal surface of teeth during cementation if a crown occlusal removal hole or cement escape vent hole has been precut in the occlusal surface of the crown. In this case the cement should set or cure before cleaning. Check for voids around the margins of the holes to avoid decalcification.

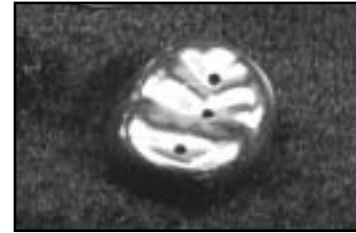
Horizontal Removal Slit

Horizontal removal slits are normally placed only on the mesiolingual corner of maxillary first molar crowns. They act as a purchase point for use with the Ormco "Chastant" crown removal pliers. The slit should be placed halfway from the gumline to the occlusal surface. An occlusal crown removal hole will need to be placed either at the time of fabrication or by the clinician at the removal appointment.

Upon request, AOA/Pro laboratory will add crown removal design modifications (horizontal slits, vertical notches and occlusal removal or vent holes) to the crowns during fabrication.



Occlusal crown removal hole.



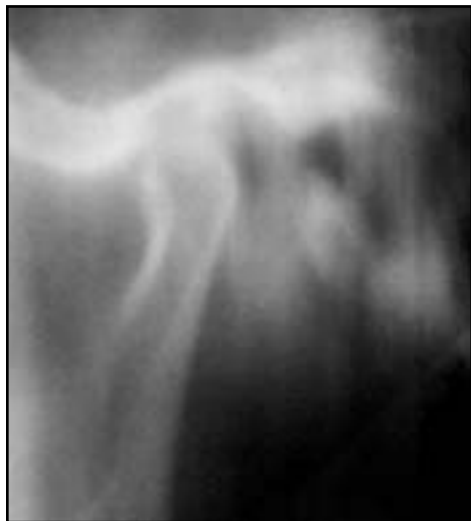Vent hole.



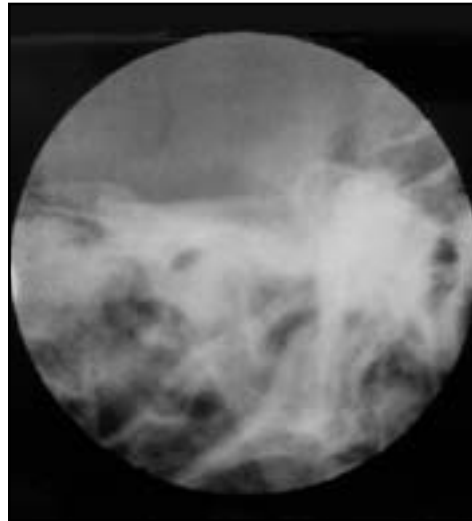
Horizontal removal slit with occlusal removal hole.

Clinical Insertion

Step 1. Many clinician's will take corrected tomograms or transcranial x-rays prior to seating the Herbst appliance to evaluate the initial position of the condyle and give the orthodontist a beginning baseline of joint morphology.



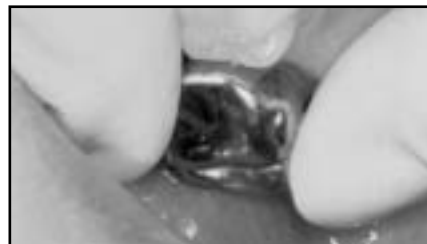Tomogram



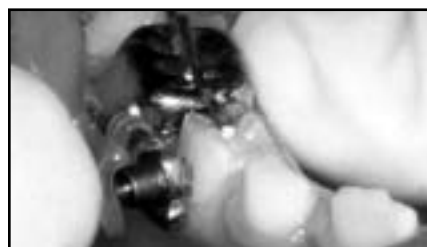Transcranial

Step 2. Remove all separators.

Step 3. The following procedures will address crowns and bands as required. Fit crown components on teeth *one* at a time and then remove to prevent aspiration, checking size and length of crown. Banded designs must be checked for proper fit. Bands will most likely fit or not fit. Crowns, being sized differently (only 8 sizes) have more room for adjustment.



Note: If using a crown design Herbst, it will be necessary at this time to document on the patient's chart any large restorations of the teeth receiving crowns. Crown removal on such teeth could result in a fracture if using crown removing pliers that apply pressure to the occlusal surface. In this situation it would be preferable to cut the crowns off the teeth at the removal appointment.

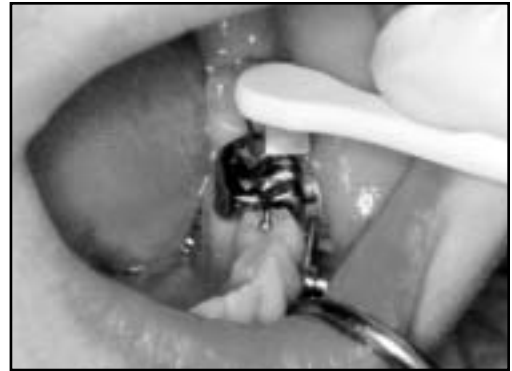

A. Fitting Crowns

During the initial fitting procedure, if the crown has a tight snap fit and you cannot remove it with your fingers, use an explorer or scaler to help pry the crown loose. Avoid using band and crown removing pliers, since they apply pressure to the top of the crown and can cause distortions. You may use these pliers if a removal hole has been precut into the crown, allowing the tip of the plier to rest on the tooth enamel. Care should be taken not to distort the gingival edge of the crown.

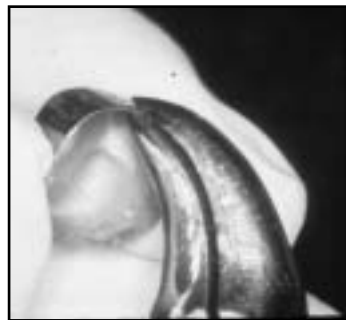Crowns should slide over the tooth with some resistance and slide down on the occlusal surface without pinching the soft gingival tissues.

Once the crown has reached about three quarters of its seating position with thumb pressure, it is beneficial to use a bite stick to complete seating. Place handle portion of the bite stick in the central groove of the crown at an angle matching the cuspal incline, and have the patient bite it down from there.

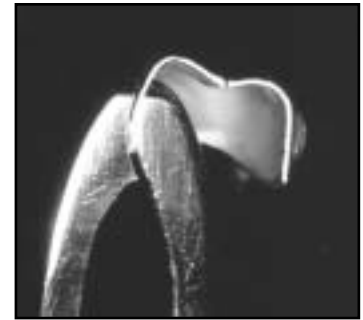


Crown is loose. Using Ormco crown contouring pliers, bird beak or How pliers, crimp the mesial and distal edges of the stainless steel crowns. Adjusting a crown in this manner can tighten it up to one-half size. Avoid crimping crowns interproximally because this may misshape them, forming a bulge in the interproximal area that will cause the crown to rock and not seat all the way down. If you must crimp interproximal, make a short, sharp crimp at the edge of the crown.

Pearl: If the crown seems a little too large after crimping and you want to go ahead with cementation, recrimp the crown very sharply close to the margin or edges all around the crown, including the interproximal area. Do not try the crown on the tooth again. Fill the crown completely full with glass ionomer to compensate for the extra crown space.



Bird beak type contouring plier.



Ormco Crown Contouring Plier. Cross section of contouring procedure.

Depending on how loose the crown is, you may consider **not** using Vaseline or ChapStick on the occlusal surface. This will enhance bond strength by allowing the adhesive to flow into the occlusal grooves. **Note:** Make a notation on the patient's chart that extra cleanup will be required at the removal appointment.

Crown is too tight. It may have been over crimped and you will need to straighten or flatten out the edges of the crown with How pliers. You can also trim the crown gingivally. Care must be taken whenever trimming crowns because contoured crowns get considerably larger when trimmed.

Crown is too long. The patient complains that it is uncomfortable on the gingival tissue. Using a heatless stone or scissors, you can trim the edges slightly to relieve impingement. It is important to remember that the higher up you trim a crown, the looser it gets on the tooth.

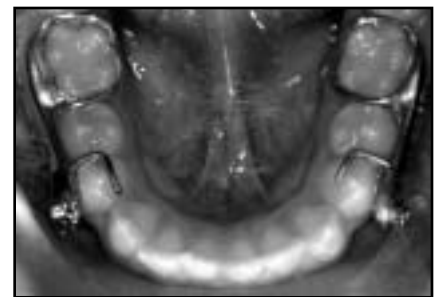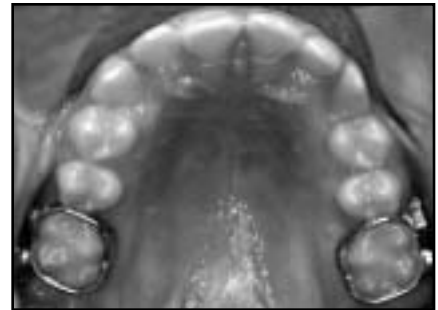Crown or Crowns Do Not Fit. Upper and lower impressions should be taken for a new set of working models. The original work models may have been distorted. When possible, direct fit a new crown or band on the tooth. If this is not possible, give the laboratory a detailed explanation of the problem. When returning an appliance to a commercial laboratory, it is very useful for them to have the original models because examination of the original and new models may help to identify the fabrication problem.

B. Fitting Bands

Bands generally fit or they do not fit. If you have prefit the bands prior to fabrication, there should be no problems pertaining to size. Check bands for poor solder joints or nicks because both of these issues can lead to breakage. It should be noted that banded Herbst designs that have support wires soldered to the band will not fit interproximal and will seat a little high. It is key to proper fit to leave the band seated like this.

Bands are Too Loose or Too Tight. Bands were most likely missized during the initial fit at the chair, or possibly by the laboratory technician if the bands were indirect fit, or there may have been a “mix-up” with another band or set of bands either prior to or during fabrication. Solder and wire supports on the bands can also affect fit.

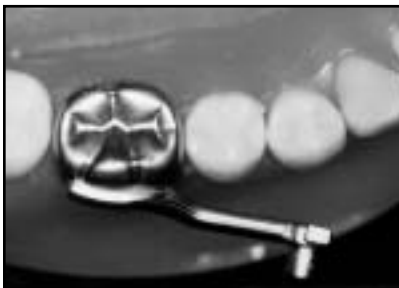Band or Bands Do Not Fit. Upper and/or lower impressions for a new set of working models should be taken. When possible, direct fit a new band on the tooth/teeth.



Bands uncemented on teeth.

Step 4. Evaluate the placement of the mandibular cantilever arms (if present) and check that they are aligned properly. If they are too far from the teeth, they will cause cheek irritation. If they are tipped too far inward, they will impinge on the gingival tissue.

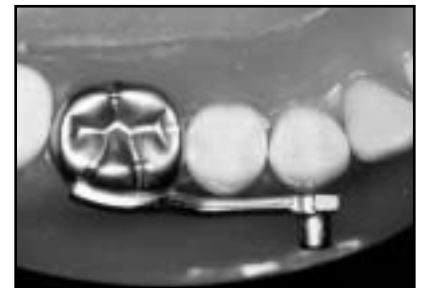Adjustments to the mandibular cantilever arms are usually made with three-prong headgear pliers or the CBJ three-jaw plier from Ormco. Any up-down, in-out, or torque corrections must be made at this time. It is almost impossible to make these adjustments after the appliance has been cemented. (Adjust as described in the Pre-Insertion Checklist, Section 4.)



Cantilever out too far.

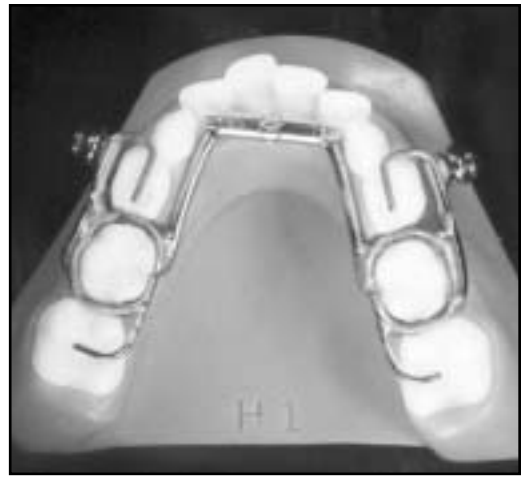
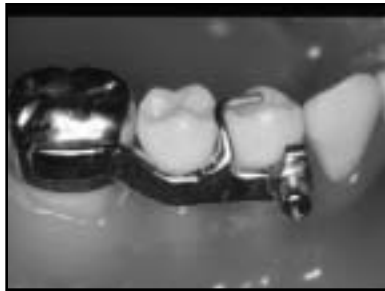
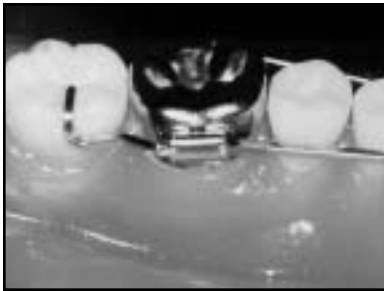Adjustment using CBJ pliers.

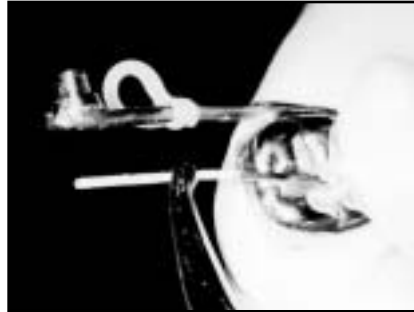
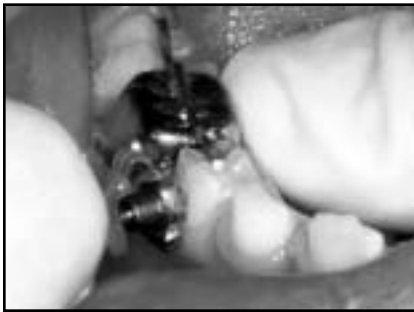

Cantilever corrected.

Step 5. Evaluate occlusal rests (if present). Occlusal rests need to be checked for their approximation to the teeth.

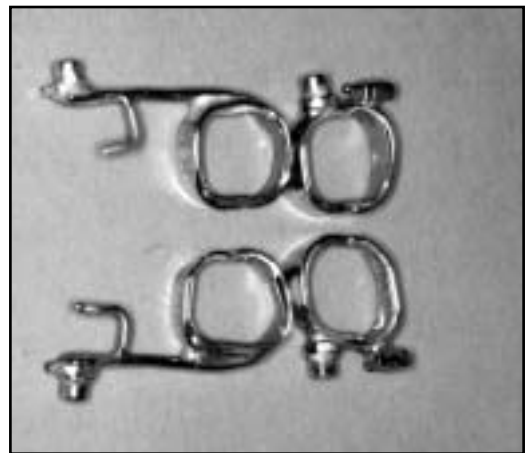
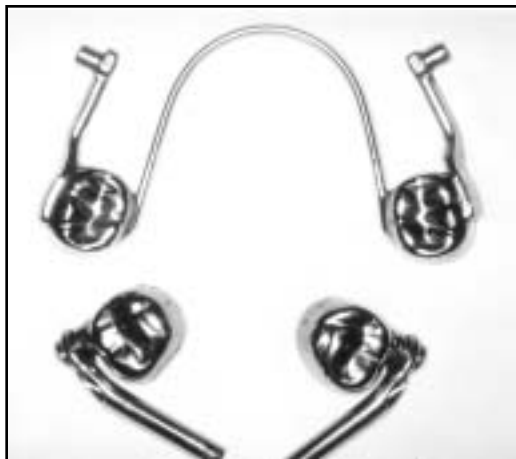
Occlusal rest adjustments are easily made with How or bird beak pliers. However, caution should be taken when adjusting rests because they can break if annealed too much.

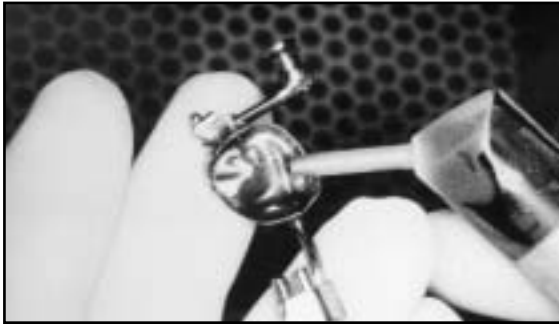

Step 6. Preparing Appliance for Cementation

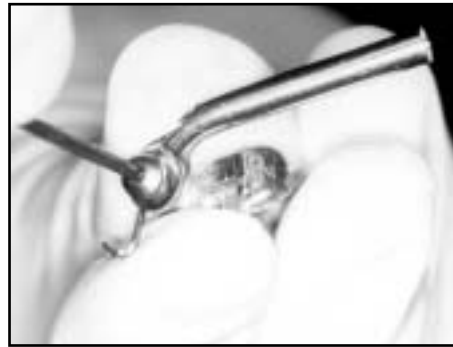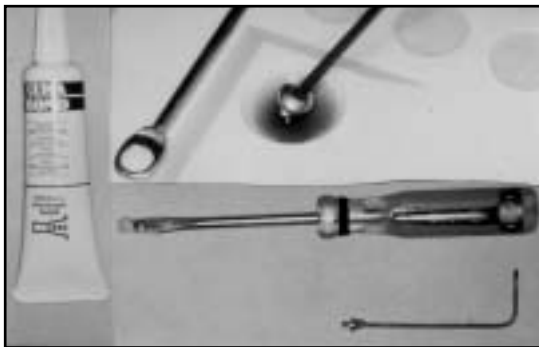
A. Dry the appliance and all its components thoroughly. The same procedure applies to crown or banded appliances.



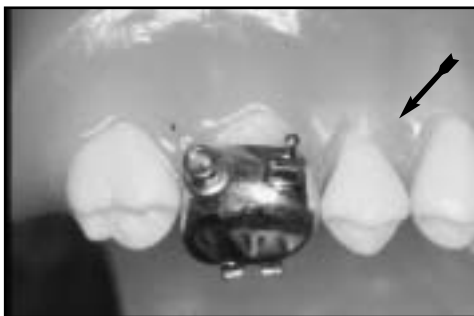Pearl: If you have made considerable adjustments to occlusal rests, crowns or bands, you may want to remicroetch before cementing.



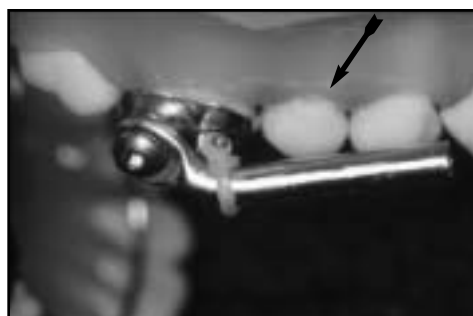
B. Dip the screws for the upper assembly in Ceka Bond, place the upper tubes over the axle on the maxillary crown and secure with the screw. This procedure is very important for two reasons. First, the Ceka Bond will keep the screws from coming loose during treatment. Second, it is very difficult to place screws in the upper mechanism after cementation due to the anatomy. *Lower rods are attached after the appliance is cemented.*



Pearl: To help keep the upper tubes from falling down into the patient's mouth during cementation, place an 1/8" diameter elastic around the screw head and twist over the upper tube, looping the elastic onto the ball hook of the archwire tube; or loop the 1/8" elastic over the ball hook pulling it under and up over the upper tube and slipping the opposite end of the elastic back over the ball hook.

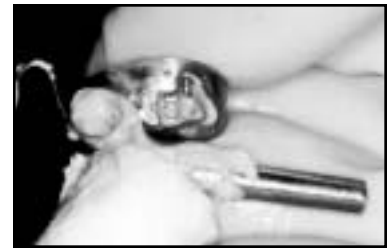

Archwire tube with ball hook soldered to crown.

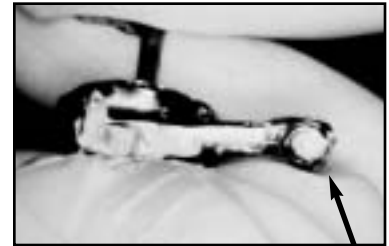

Elastic used to hold tube up and out of the way during cementation.

- C. Place toothpaste or lotion in any and all open areas of the appliance's components. This includes upper tubes, upper and lower archwire slots, both axles and also in the expander screw if one has been incorporated into the design. Avoid getting any of these separating agents inside the crowns/bands as they may contaminate the cement and weaken the bond.



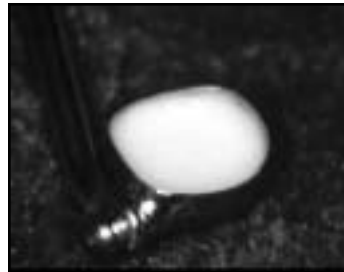
Note: If using wax, do not place in *screw housings. Ceka Bond will not adhere.



*screw housing

Step 7: Cementation of the Appliance

- A. Mix cement and place in the crowns/bands. Crowns should be 1/2 to 2/3 full. Use a glass ionomer cement such as Fugii I, Ormco Protech, or Ormco Protech Gold.

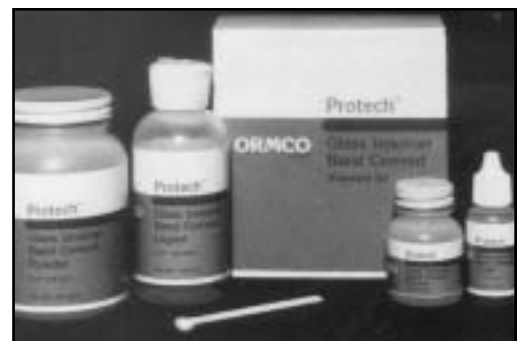

Pearl #1: Make sure the doctor is at the chair and ready to proceed as you are filling crowns/bands with cement. If the cement hardens, you will lose 30 to 45 minutes cleaning out the crowns/bands and remicroetching.



Pearl #2: Using "Allwrap" or a similar material over the mixing slab will cut cleanup time. This material is found through dental supply houses and is the same material general dentists use to cover their equipment for sterilization considerations.

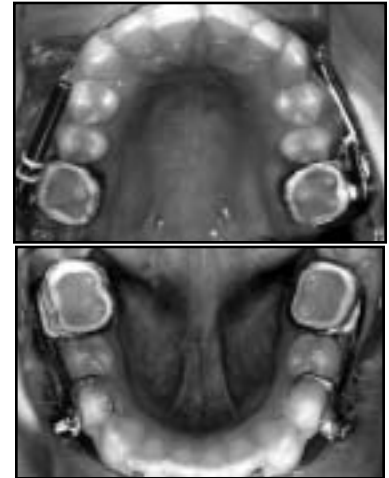
Pearl #3: When using a crown Herbst, Ormco's Protech Gold glass ionomer is very good to use because its gold color is easily seen when cutting through the crown during the removal procedure. And during cleanup, it is easier to see that all of the cement has been removed.



B. Isolate and dry teeth.

1) Cementing Bands

- Fill bands with cement (glass ionomer) and place the appliance. Note that the bands with soldered support wires will seat a little high interproximally.
- It is important to build up a shelf with cement around the inside margin of the bands to prevent washout and to keep this area from becoming a food trap. Clean excess cement from occlusal surfaces and around gum tissue.
- Have the patient bite down on cotton rolls while the cement sets.
- Once set, clean remaining cement from the teeth.

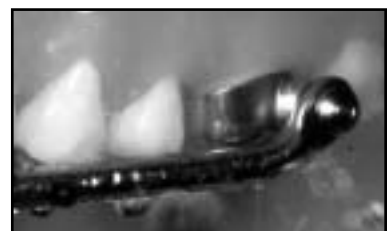
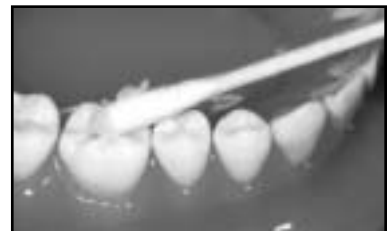
2) Cementing Crowns (without removal or vent holes on the occlusal surface)

- With a cotton applicator, place a thin film of Vaseline or a little ChapStick on the occlusal surface of the tooth. This will keep the glass ionomer out of the grooves, simplifying removal of the crown and keeping cleanup time to a minimum.
- Clean excess cement from crowns and surrounding teeth immediately using the air-water syringe suction. When using a glass ionomer, there is no reason to wait for it to set up before rinsing.
- Have the patient bite on cotton rolls to hold the crowns in place while the cement sets.

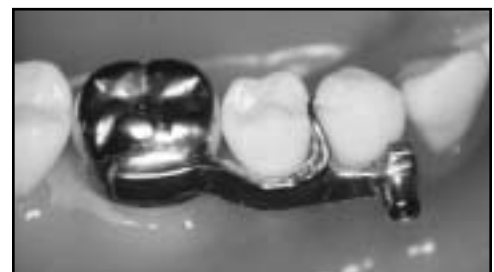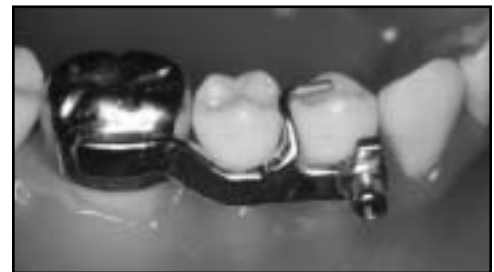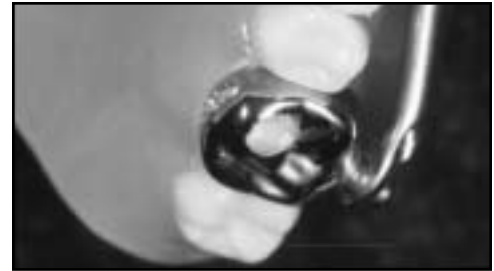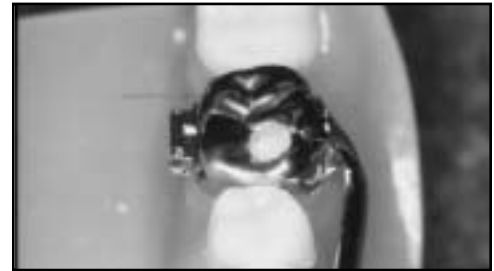Note: Do not use Vaseline or ChapStick on the teeth if a crown removal or cement vent hole has been precut in the occlusal surface of the crown. In this case, the cement should set or cure before cleaning. Have the patient bite on cotton rolls while the cement cures. Check for voids and leave a bit of excess cement around the margins of the holes to avoid decalcification.

Pearl: If a crown did not fit properly (too large or small) and/or considerable adjustments were made, let that particular crown's cement cure before cleaning off the excess.



3) Cementing Crowns (with removal or vent holes on the occlusal surface)

- Do not use Vaseline or ChapStick on the teeth if a crown removal or vent hole has been precut in the occlusal surface of the crown.
- If there is a removal or vent hole, the cement should set or cure before cleaning.
- Do not wipe the extruded cement away from the hole until it sets, and then leave a bit of excess to retard washout. Check for voids around the margins of the holes to avoid decalcification.
- Because cement escapes out of the holes, do not blow air around the removal or vent holes before the cement completely sets up.
- Have the patient bite on cotton rolls to hold the crowns in place while the cement sets.
- Clean off any excess cement after it sets.



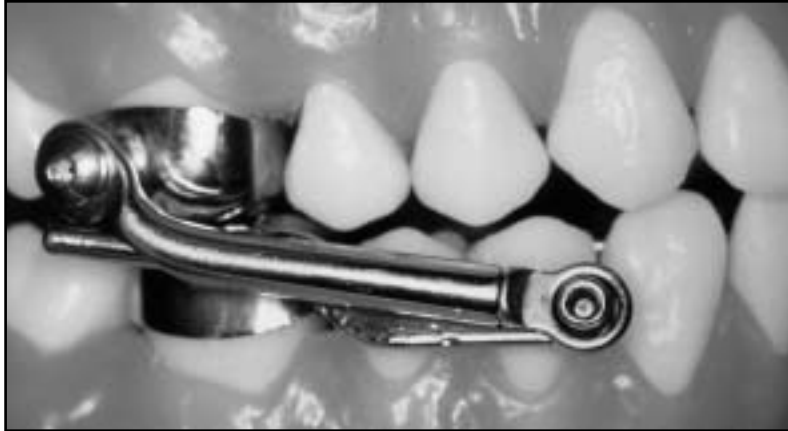Step 8. Bond occlusal rests, if applicable. Prepare the teeth for light-cure composite material, bonding one arch at a time. Place enough adhesive to fill in the occlusal grooves of the tooth and cover the metal rests. Cure adhesive with light.

Note: Second molar rests are not usually bonded.

Pearl: An adhesive booster is suggested to increase bond strength.

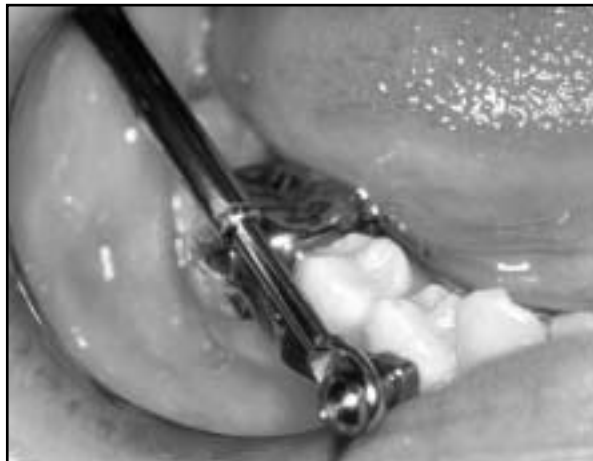Step 9. Interlocking the Herbst Mechanism

- A. Remove elastics from upper tubes.
- B. Slip the lower rod into the upper tube, place the eyelet of the lower rod over the axle and hold, guiding the patient's lower jaw into the advanced forward position. At first, the patient will have a tendency to resist closing in this position. Lower screws do not need to be placed during this phase. If they are, you may spend more time removing them if adjustments need to be made.



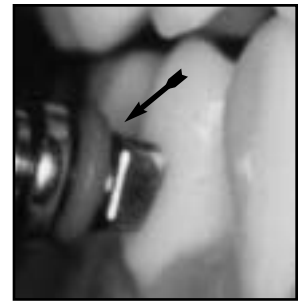
C. Interlocking Checklist

- 1) The patient should be able to open and close without interference from:
 - The appliance.
 - Brackets, if applicable.
 - Binding of the tube and rod assembly.

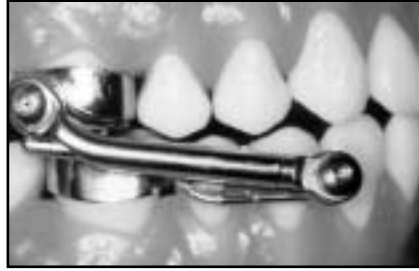
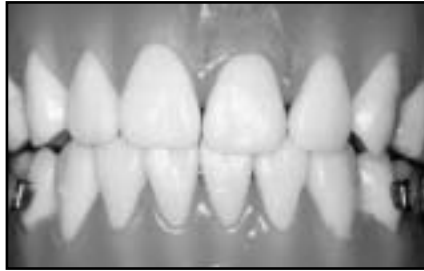
If the patient's tube and rod assembly is binding and expansion of the maxillary arch is not an issue, try placing a large separating elastic over the lower axles on the crowns, place the lower rods over the elastics on the axle and secure with the screw.

- 2) Check that the patient's midlines are lined up and that the appliance has been advanced according to the prescription.

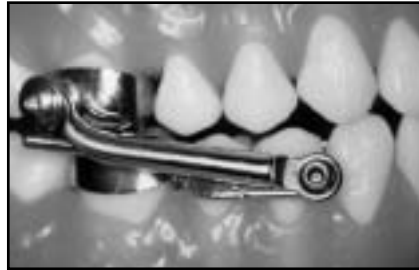
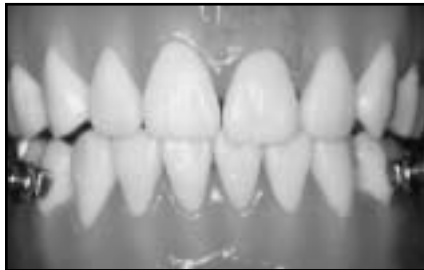
Midline correct.

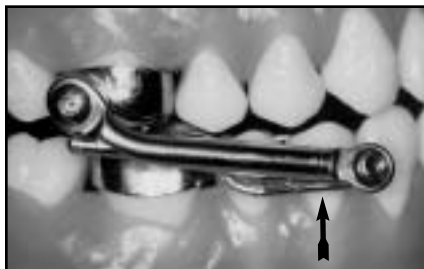


If the midlines are off, correct by placing a shim/bushing on the lower rod as described in the Pre-Insertion Checklist, Section 3.

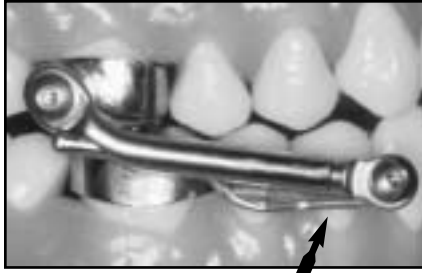
Midline off.



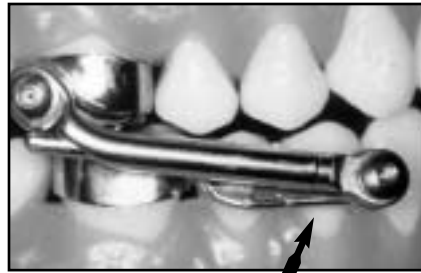Midline corrected with shim.



If the patient has not been advanced properly and the upper tubes are a little short, you may be able to correct the advancement simply by crimping an appropriate size shim/bushing over the lower rod, filling the space. If the upper tubes and lower rods need replacing, refer to the Pre-Insertion Checklist, Section 2.



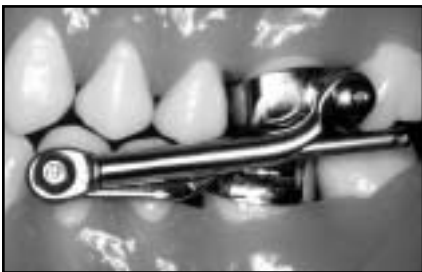Upper tube too short. Too much space between tube and lower rod.



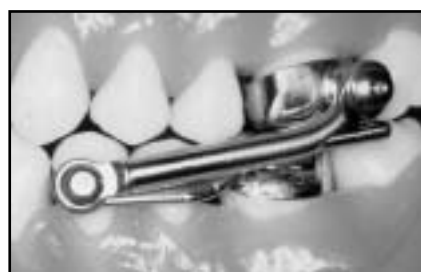Upper tube length corrected by adding shim to lower rod.

- 3) Have the patient close completely and check that the lower rods do not protrude too far out of the upper tube. If they do, the lower rods will cause irritation and sores.

If the lower rods are too long, correct as described in Pre-Insertion Checklist, Section 2.



Lower rod too long.




Lower rod correct length.

- 4) If the patient has been advanced properly but disengages easily, replace as described in the Pre-Insertion Checklist, Section 2.

Note: To keep from disengaging, a patient may require advancement to a Class III overcorrected position. This is a rare problem. However, because of the patient's anatomy, advancing to a Class III position may be the only way to keep the Herbst mechanism interlocked. A patient advanced like this normally relapses to an end-to-end relationship within a couple of weeks.

5) If one side of the mechanism is hard to engage after the other side has been connected, have the patient slide their jaw away from the side to be adjusted. Slip the lower rod into the upper tube and place the eyelet over the lower axle.

D. If there are no problems with the mechanisms and the appliance fits properly, dip the lower screws in Ceka Bond and place in the lower axle.



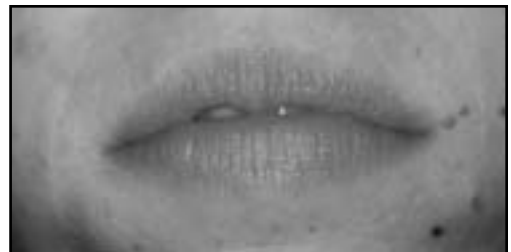Post-Insertion Instructions to Patient/Parent

It is important to inform patients and parents that there will be an adjustment period and that problems associated with the appliance can arise. Discuss these issues in detail at the exit interview. A “care kit” and a written “instruction sheet” should be sent home with the patient. Educating and communicating with patients and parents empower them to take a proactive role in the management and care of their appliance during therapy, minimizing frustrations and resulting in fewer emergency appointments.

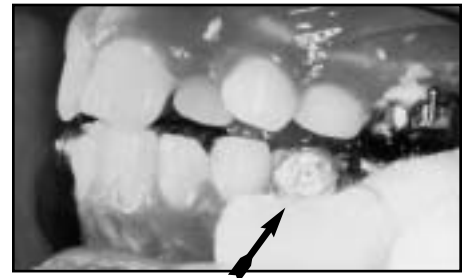
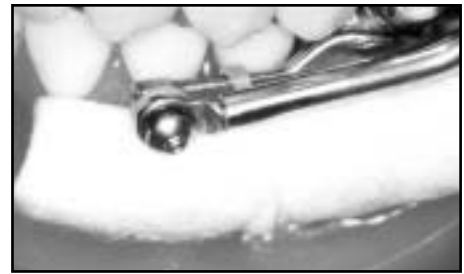If the patient is a minor, the parent should always be present at the exit interview.

This is a perfect opportunity to point out to the parent and patient how good the chin and profile looks with the appliance in place.

1. Explain that there will be difficulty in eating for four to ten days. Suggest that they cut most of their food into small pieces, keeping frustration with chewing to a minimum. They will be able to eat just about anything on their normal diet in a few days.
2. Sometimes a patient’s cheeks will become puffy. Explain that the puffiness will disappear over the next several weeks.
3. They may experience soreness in the area of the lower screws. Inform them that the soreness will go away as the tissue toughens and a callus forms.

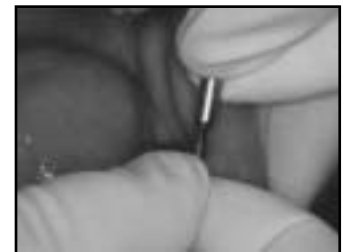
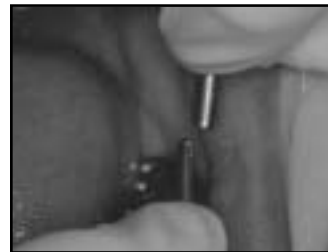
4. Give the patient Orabase with Benzocaine to relieve soreness and cotton rolls to place inside a 1/4" elastic placed around the lower cantilever arms at night while the tissue adapts to the appliance around the screw head on the cantilever. Brace Relief is also helpful in maintaining comfort. Patients usually become accustomed to the appliance in a couple of weeks.

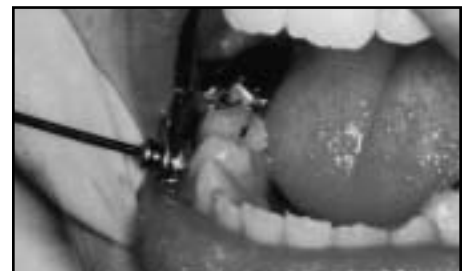

Pearl: Placing comfort caps over the screw head at delivery also helps reduce irritation.

5. Show the patient and parent how to interlock or engage the upper tubes and rods in case the patient opens too wide, disengaging them.



6. Give the patient/parent an extra allen wrench (hex screw) or screw driver (slot screw); show them how to replace the screw. Most parents/patients will not be able to replace an upper screw. If the patient does not have a wrench or screw, tell them to remove the rod or tube involved, save the pieces and call the office the next business day for replacement. Inform the patient/parent that a screw does not need to be replaced right away unless the patient is uncomfortable.



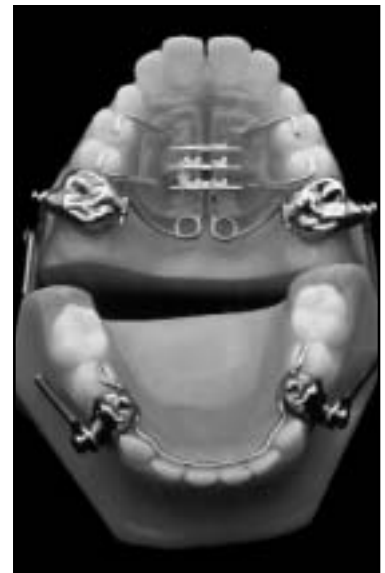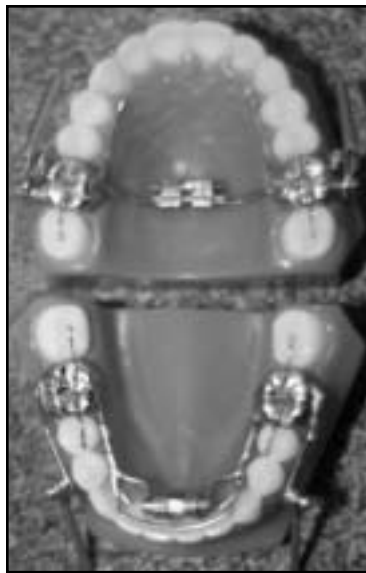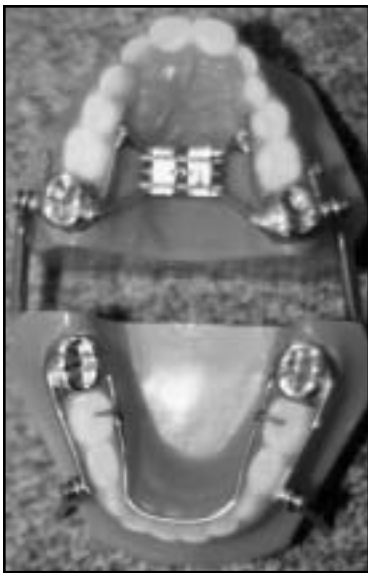
7. Explain that due to the exceptional forces on the appliance during chewing a crown may come loose.
8. Patients and Parents should always be given written information sheets that describe the appliance, its function, and possible problems with solutions. Each office should create their own unique information sheets.

Expander Herbst

If transverse correction is required prior to correcting the Class II, incorporating expanders into a crown/banded Herbst can be efficient and cost effective.

The following are advantages of incorporating expanders into the appliance:

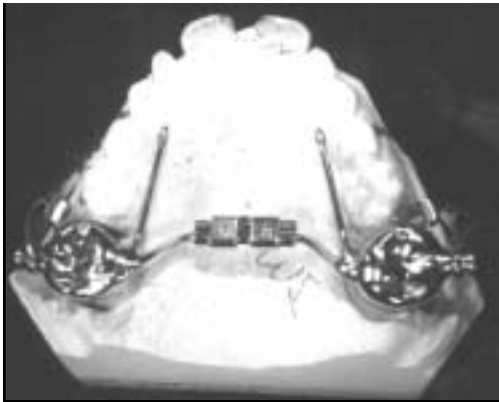- A single, multifunctional appliance is used for both transverse and anteroposterior correction.
- Transition from the transverse correction into anteroposterior correction is virtually seamless.
- With arch development, many times the maxillary arch width exceeds the mandibular arch, making arch coordination difficult. Once engaged, the rod and tube appliance assembly aids in arch coordination.
- Because of the vertical control that occurs with the appliance, the patient's bite does not tend to open as it often does when expanding.
- Tipping of the teeth is controlled and teeth remain upright during expansion.
- When expanding the mandibular arch and taking into consideration the appliance design, it has been reported that lower incisors can have a tendency to move lingually as opposed to forward. In these cases, the incisors are tipped forward after expansion, resulting in more mandibular arch length.



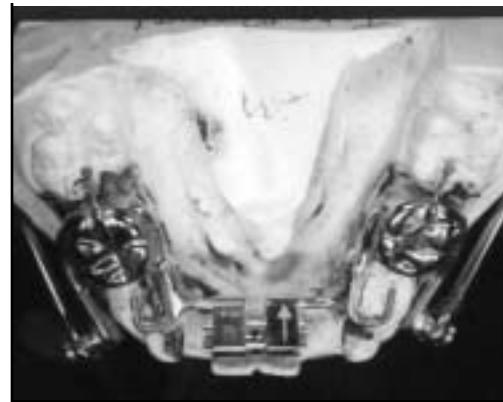Expander Herbst Technical and Clinical Considerations

When incorporating an upper expander into an appliance, the crowns/bands are generally placed on the first permanent molars in permanent dentition. However, a patient presenting in primary or mixed dentition may require a design modification to accommodate the patient's comfort. Cheek tissue always becomes tighter after expanding an arch, and this is true for both adults and children. Access to the posterior area of the mouth becomes very difficult to manage, especially in small children.

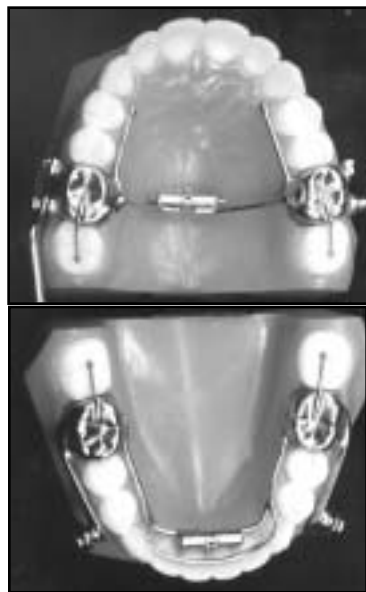If the patient is very young and there is sufficient root structure, upper and lower second primary molars can be used for crown/band placement. Using second primary molars avoids placing crowns on permanent first molars that may be partially erupted. On the upper arch, a screw housing soldered to a second primary molar crown is more accessible when attaching the upper tube assembly (particularly after expansion).



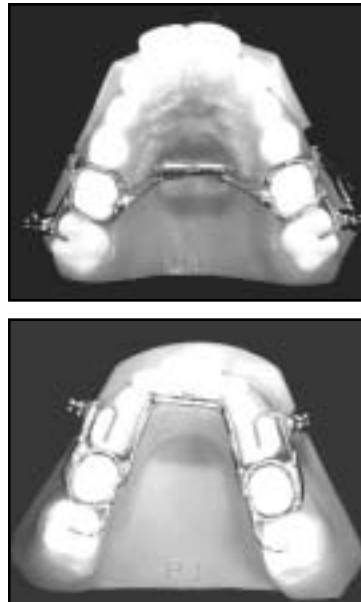
Upper expander Herbst using a small screw. Crowns placed on first molars.



Lower expander Herbst using a small screw. Crowns placed on second primary molars.



Compact RPE screw is much smaller than most screws currently available.

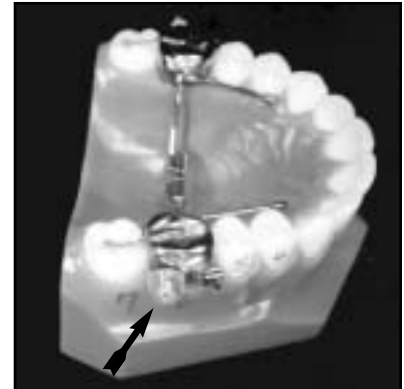


Delivery of the expander Herbst appliance is basically the same as described in the Clinical Insertion section on Delivery of the Bite Jumper with the following exceptions:

A. Since the upper tubes and lower rods will not be attached until expansion is complete, the screw housings will need to be covered for patient comfort. Several options are described below.

1. Prior to Cementation

Dip screws in Ceka Bond and place in the axles. This procedure has a drawback because you will have to remove the screws to place the upper and lower assembly when expansion is complete. Remember, the cheeks will get tighter as the arch is expanded.

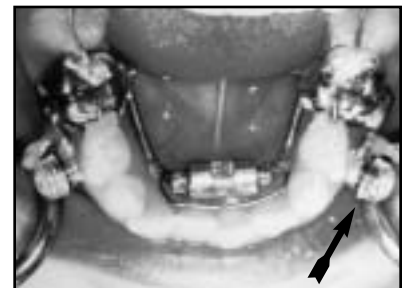


2. After Cementation

a. "Comfort Caps" can be placed over upper and/or lower axles with or without screws in place to help keep the patient comfortable during the expansion phase. Comfort cap styles include caps to cover 4mm and 5.5mm screws as well as one that slips directly over the axle.

Comfort Caps may be purchased from Comfort Solutions in Canada and from AOA/Pro in the United States.

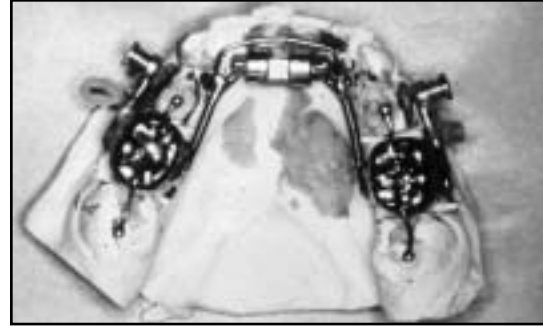
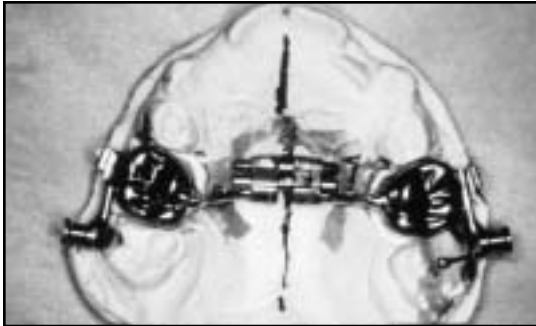
b. "Barricade" can also be placed on the open upper and lower axles after cementation, covering the screw housings and forming a protective barrier. Barricade can be purchased through a local dental supply house. It is a product used in periodontics as a tissue-protective dressing or shield. It is light-cured and has a rubbery feel to it. Over time it becomes somewhat sticky but usually stays on the screw housings through the expansion phase. The material can be pulled off and any excess left in the screw housing does not seem to hinder screw placement when attaching the tube and rod assemblies after expansion is complete. If you choose this option, make sure you fill the open screw housings with toothpaste or lotion to keep out the glass ionomer cement before cementing the expander.



B. Precutting rods and tubes that will be placed after expansion can sometimes be inaccurate due to the changes in arch width. When precutting the assembly, a technician can only approximate the length that will be required by taking into consideration the amount of expansion allowed by the expander itself and how far the clinician wants to advance the patient after expansion. It may be advisable to request that the laboratory send the rods and tubes uncut and make the adjustments in-house as needed after expansion is complete.

Delivery of the Expander Herbst

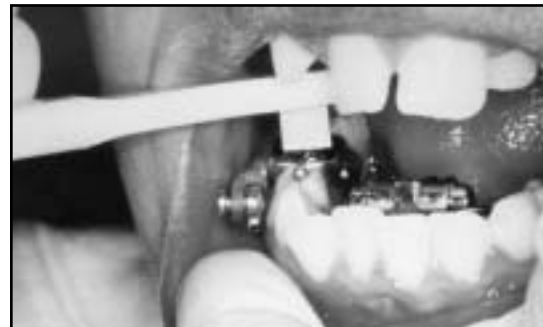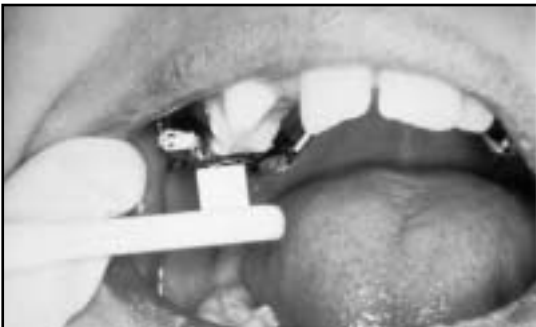Several days before the patient's appointment, check to make sure you have the appliance and its components from the laboratory. Inspect the appliance as described in the Pre-Insertion Checklist section. Expander Herbst appliances should have the appropriate expansion keys to activate the expanders returned with the case. To make sure the expander screws work, check them according to each manufacturer's instruction.



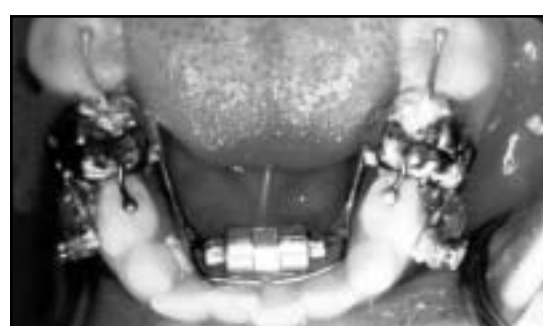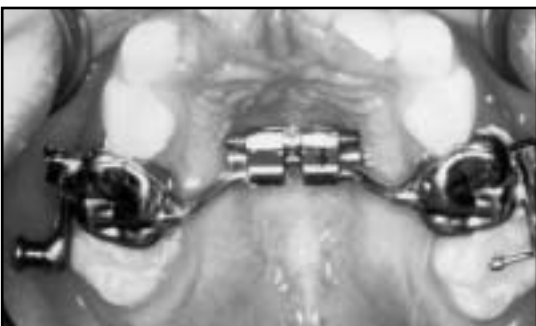Step 1. Delivery appointment: If available, take corrected tomograms or transcranials.

Step 2. Remove all separators from between the teeth to receive crowns/bands.

Step 3. Try the appliance in the mouth one arch at a time.



Step 4. Check the appliance for fit and, if necessary, make adjustments as described in the Clinical Insertion section for bands and crowns.



Pearl: If considerable adjustments were made to the crowns/bands and/or occlusal rests, remicroetch the component before cementation.

Step 5. Dry the appliance and all of its components.

Step 6. Before cementing, make sure all the orifices in the expander(s), as well as open screw housings, axles and archwire tubes, are filled with lotion or toothpaste to keep out the adhesive.

Note: If you plan to use Ceka Bond to secure screws, do not use wax in the screw housings of the Herbst mechanisms. Wax is very difficult to clean out, and if it's left in the screw housings, a barrier will form and the Ceka Bond will not cure.

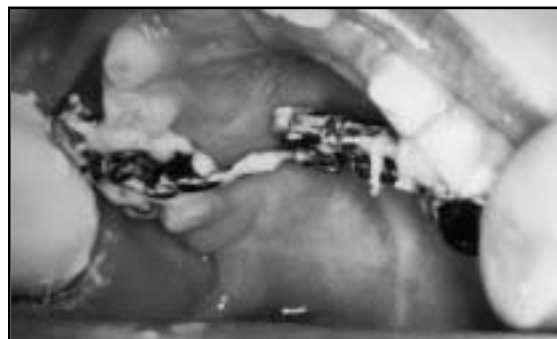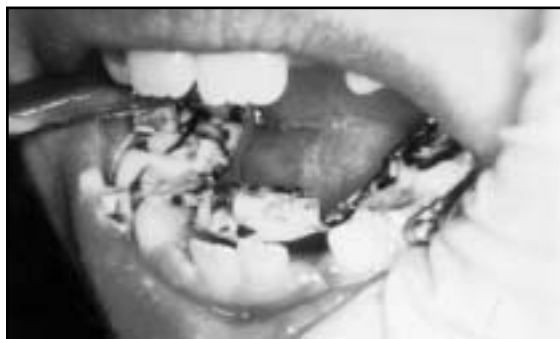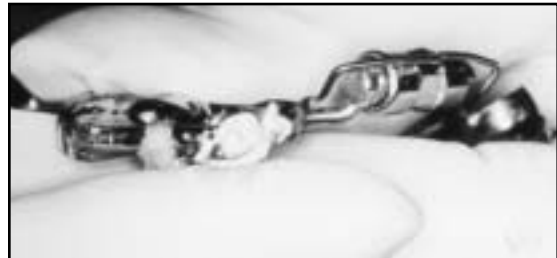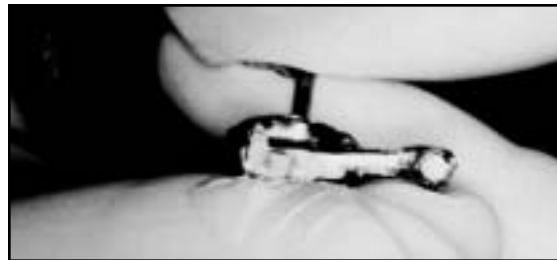Step 7. Fill the crowns/bands preferably with a glass ionomer.

Step 8. Crown Placement Only
Place Vaseline or ChapStick on the occlusal surface of the teeth receiving crowns. *If occlusal removal or vent holes are present in the crowns prior to insertion, do not place on the teeth.*

Step 9. To avoid saliva contamination, cement the mandibular appliance first and then cement the upper.

- **Cementing a Banded Expander Herbst**
Clean off excess and let cement set.

- **Cementing a Crown Expander Herbst**
Before the glass ionomer sets, clean up immediately with the air/water/suction syringe. If occlusal removal or vent holes are present in crowns, let the glass ionomer set and make sure there are no voids around the margins of the holes.

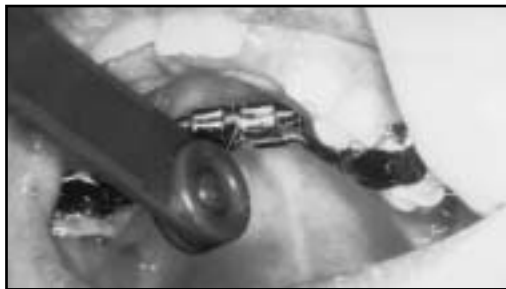

Post-Insertion Instructions to Patient/Parent

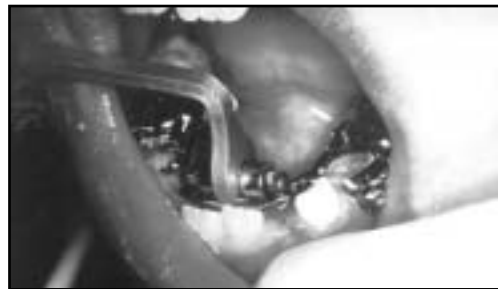Expanders are usually turned several times before the patient leaves the office. The assistant makes the first turn of the expander with the parent watching. Then the parent should turn it. This ensures that the parent is turning it correctly. If upper and lower expanders are present, review the procedure for both. The amount of turns and amount of time required for maximum expansion depends on:

- The maximum expansion allowed by the screw, which is usually 7 to 12mm.
- The number of turns required to fully open the screw. (Because of the variations in design, follow the manufacturer's guideline or ask the laboratory to provide the information pertaining to each expander.)
- The expansion desired for the patient.

Note: Maxillary expanders are normally turned every day. Mandibular expanders, when present, are usually turned every other day and will have a tendency to ride up on the lingual if turned too quickly.



Maxillary expander activation.



Mandibular expander activation.

In addition to the information outlined in the Post-Insertion Instructions to Patient/Parent section, explain the following to the patient/parent:

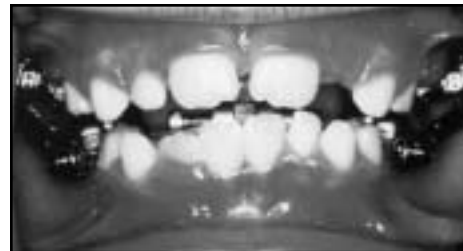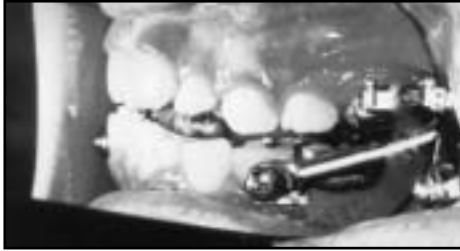1. The patient will salivate more until they become accustomed to the appliance.
2. Swallowing will be difficult at first because of the presence of the expander(s). The patient should practice with a glass of water taking small drinks to train the tongue to function properly while adapting to the expander(s) in the mouth.
3. Cutting food into small pieces and taking very small bites of food will ease the chewing process during the first week.
4. Food will have a tendency to get stuck in and around the expanders, including the lower lingual and/or sweep wires incorporated into mandibular expander designs. While eating, food can be dislodged from expanders by taking a drink of liquid and swishing it around in the mouth.
5. Speaking will be a little more difficult at first when expanders are present. Suggest that the patient read out loud for a day or two. This will help the tongue to adjust to the expander's position in the mouth.
6. Instruct the patient/parent on how to keep track of the expander turns on the expander score card. Provide a card for maxillary and mandibular expanders. Indicate on the card the schedule for turning the expanders.

Schedule the patient to be seen in four weeks to check if expansion is complete.

Expansion/Removal of Expander(s) and Continuation of Therapy

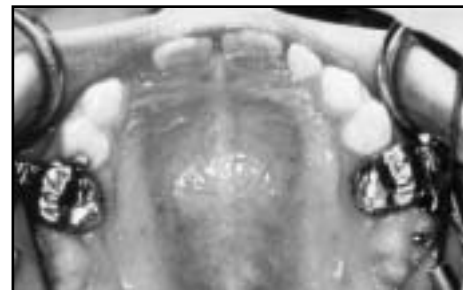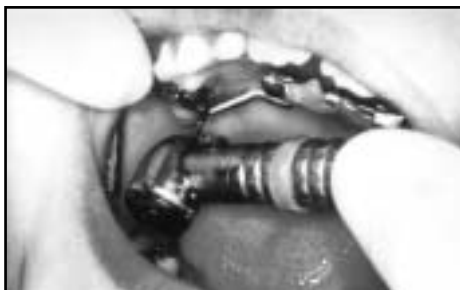Maxillary Arch

See the patient in one month. If the maxillary arch is not wide enough, the patient will continue expansion. If the maxillary arch is expanded so it is wider than the mandibular arch and the maxilla can accommodate all the teeth, remove the expansion screw and attach the rods and tubes, bringing midlines into an edge-to-edge occlusion.

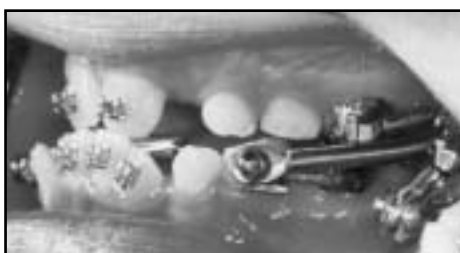

Note: If a lower expander is also incorporated, it almost always takes longer for the mandibular arch to reach full expansion. In this case, when the upper arch is expanded go ahead and engage the rods and tubes and continue lower arch expansion until it is completed.

1. Cut the expander(s) off the appliance. Because of hygiene considerations, it is prudent to remove the expander as soon as possible. Once the tube and rod assembly is engaged, they will hold the arch and keep the expansion from relapsing.



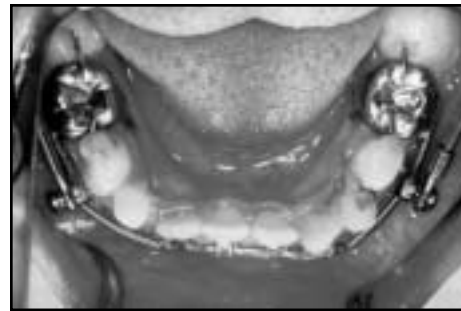
2. Attach the tube and rod assembly and advance as described above. The patient is usually scheduled to be seen again in ten weeks.
3. At this next appointment, check the patient and, if applicable, bracket the upper and lower incisors.



Mandibular Arch

Completion of mandibular expansion usually continues after the maxillary expansion has been achieved. The upper expander is removed and the tube and rod assembly is engaged, making the prescribed advancement. The lower expander is not usually cut out at the same time as the upper expander and almost always remains in the lower arch ten weeks beyond the upper expander's removal and placement of maxillary and mandibular brackets.

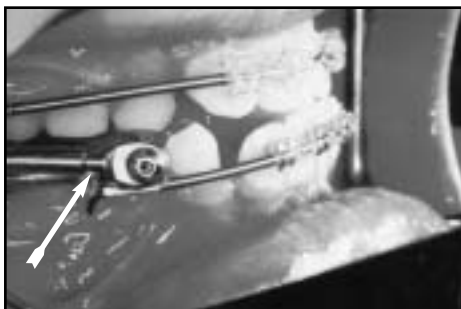
1. When lower expansion is complete, remove the lower expander. Bracket the lower incisors with *negative torque brackets* (-5° to -10°) and place an .019 x .025 Copper Ni-Ti archwire.



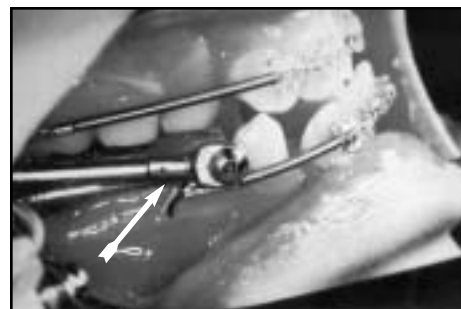
2. The .019 x .025 Copper Ni-Ti archwire along with negative torque brackets on the lower incisors will maintain the mandibular expansion and keep incisors from inclining. The rods and tubes maintain the maxillary expansion.

Note: If rotations are present that dictate the use of a lesser strength archwire, consider leaving the lower expander in another ten weeks or until it is possible to place the heavier Copper Ni-Ti archwire.

Once the tubes and rods are engaged on the Herbst appliance, the patient may be activated as necessary and treatment continued.



Patient requires activation. Note space between upper tube and eyelet of lower rod.



Patient activated with shim of appropriate length to achieve desired advancement.

Hybrid Herbst

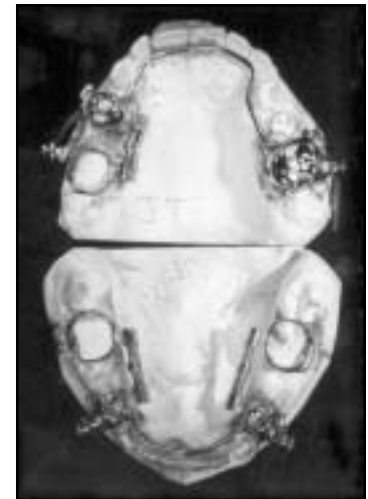
Technical and Clinical Considerations

The main thing to remember about Herbst appliances is that no matter how you modify them, they are basically managed the same way from a clinical standpoint. The delivery, activation and removal procedures are really no different, as outlined in the appropriate chapters. Of course there are differences in managing the hybrid appliance to achieve treatment goals.

In this chapter we will review a few of the exceptions and share clinical tips that should help transition the use of these appliances into your practice.

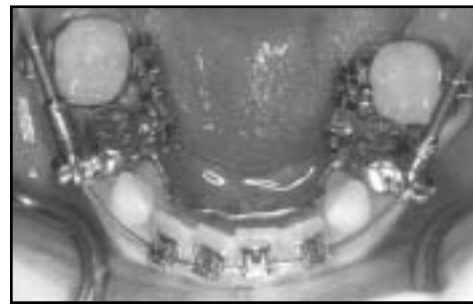
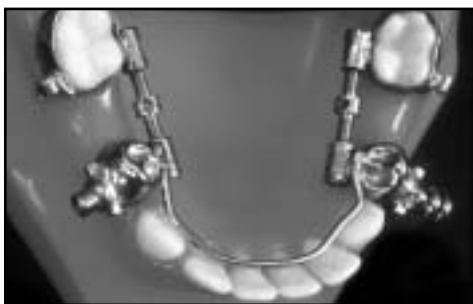Space-Closing Herbst

This Hybrid Herbst can be used in the mandibular and/or the maxillary arch for unilateral and bilateral closure of missing bicuspid space(s). By far the most popular design has been the use of small (mini) screws being incorporated into the appliance. The screws are open and will be closed during the space-closure phase of treatment. For ease of access, screws should turn toward the palate or inside. The patient will turn the screws 1/4 turn every day or every other day until closure is achieved. Space closure takes 6 to 12 weeks.



The Herbst is being used as anchorage to hold the incisors in place, allowing the space to be closed by forward movement of the molars without distalization of the incisors. Upper and lower 2-2 brackets and .019 x .025 Copper Ni-Ti or .020 square Copper Ni-Ti archwires need to be placed within two weeks of appliance delivery.

Symmetry of the arches can be maintained during closure as well as Class II correction with the Herbst, which can occur simultaneously.



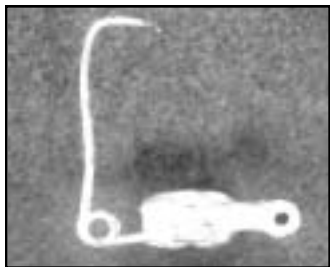
Note: Sometimes a second appliance may be required to complete closure. If this is the case, the appliance will be removed from the arch, impressions are taken for the second appliance as well as for an immediate invisible retainer. The patient will be given the retainer before leaving the office and should wear it until the second appliance can be delivered. This will prevent space from opening in the interim.

Intrusion Herbst

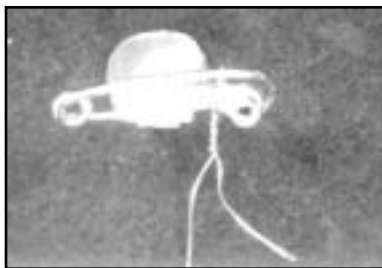According to Dr. Terry Dischinger, patients with a high-angle open bite respond well to the hybrid, open-bite intrusion appliance. The Herbst is used as anchorage to correct high-angle open-bite cases through impaction of the maxillary posterior teeth and repositioning the mandible. (See Dr. Dischinger's article on the Intrusion Herbst in AOA Appliances, etc., Vol. 5, No. 2 on Ormco's Web site at ormco.com/aoa.)

The hybrid Intrusion Herbst appliances are designed quite differently, depending on the dentition involved and treatment goals. Expanders can be incorporated if necessary, and brackets are always placed on the maxillary and mandibular incisors including the maxillary permanent cuspids, as added anchorage and to prevent incisal flaring.

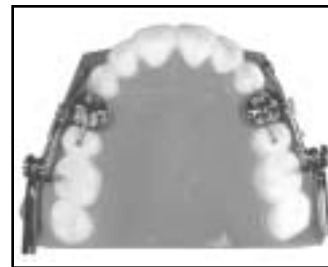
Clinical Management Tips: Activate the intrusion wire 90° and tie down with a ligature wire before cementation to ensure patient comfort during delivery. Cut the ligature off once the intrusion wire that rests on the molar's occlusal surface has been secured with composite.



Intrusion wire activated 90°.



Intrusion wire secured with ligature prior to delivery.



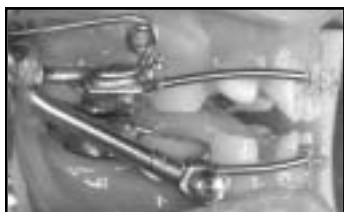Intrusion wire secured to molar's occlusal surface after delivery.

Mixed Dentition

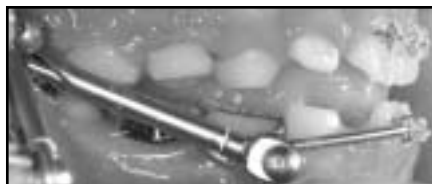Dr. Terry Dischinger has stated that a high-angle Class II open bite treated early to impact the maxillary molars allows autorotation of the mandible, creating a low-angle case.

Once the maxillary permanent molars are intruded, the maxillary first and second primary molars are extracted. After these teeth are extracted the appliance will be used like a standard Herbst to correct the Class II.

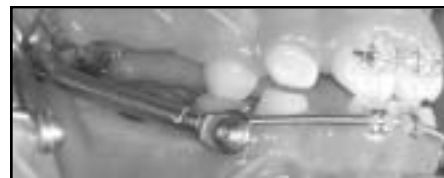Intrusion usually occurs in three to five months, with an additional three to five months for Class II correction.



Intrusion Herbst engaged. Intruding 1st permanent molar



Intruded 1st permanent molars w/primary 2nd molars in occlusion, holding bite open.



Mandible autorotated closed with extraction of primary 1st and 2nd molars.


Permanent Dentition

Permanent dentition open-bite intrusion Herbst treatment is more complicated than treatment in the mixed dentition. If required to intrude both maxillary first and second permanent molars, intrude the first molars first.

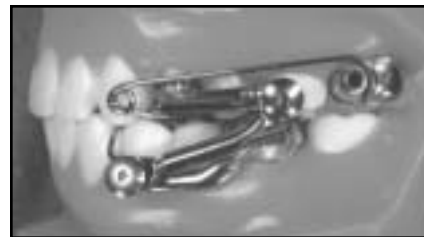
Note: If you intrude the second molars first, there won't be any way to hold them in place. When intruding second molars, a second upper intrusion appliance will be necessary. The lower Herbst appliance remains in place.

The maxillary intrusion appliance is designed differently, depending on whether or not permanent second molars are to be intruded.

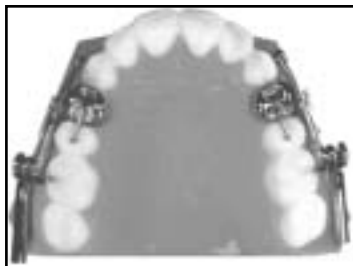
Intrusion of the first molars usually occurs in three to five months, with an additional three to five months to intrude second molars and three to five more months for Class II correction.



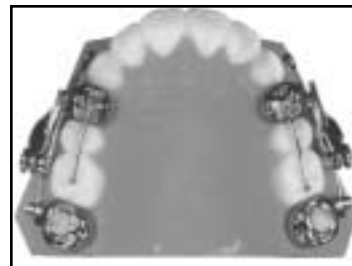
**Permanent dentition first molar intrusion Herbst.
(#1 of 2 upper Herbsts)**



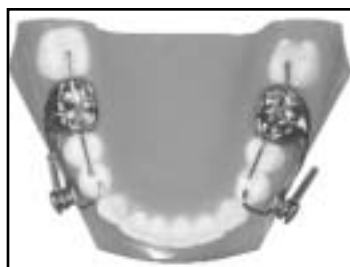**Permanent dentition second molar intrusion Herbst.
(#2 of 2 upper Herbsts)**



Occlusal of maxillary first molar intrusion Herbst.



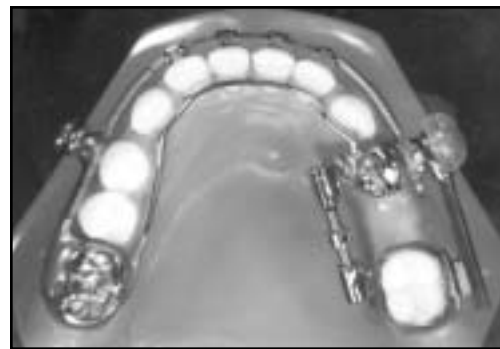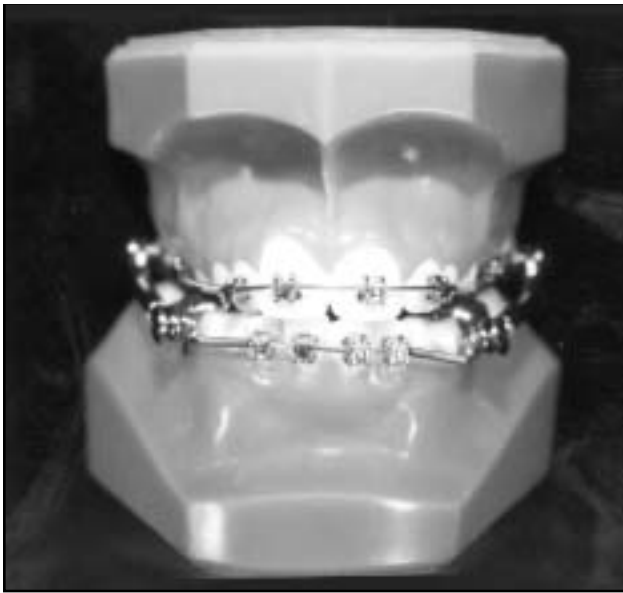
Occlusal of maxillary second molar intrusion Herbst.



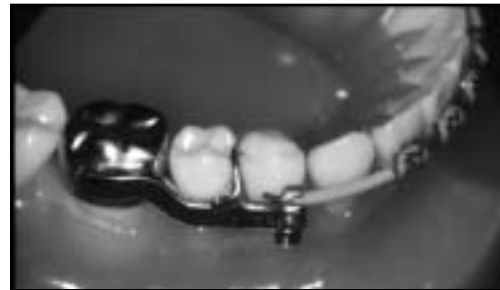The mandibular portion of the intrusion Herbst will remain in place throughout intrusion of the maxillary first and second molars.

Treatment Sequence and Herbst Activation

Treatment protocol during this phase of treatment is different depending on the treatment philosophy and mechanics being used by the clinician. Some clinicians prefer to expand the arches first (the majority of skeletal Class II malocclusions require maxillary and/or mandibular expansion), correct the AP with the Herbst and then place brackets on uncrowded Class I cases. Others like to incorporate expanders into the appliance, expand their patients and then continue their treatment plan of correcting rotations, aligning and leveling the arches. When brackets are used in conjunction with the appliance, they are usually placed sometime during the first ten weeks after insertion of the appliance to begin combined treatment mechanics and/or to counter the protruding effect of certain Herbst designs on the lower incisors.



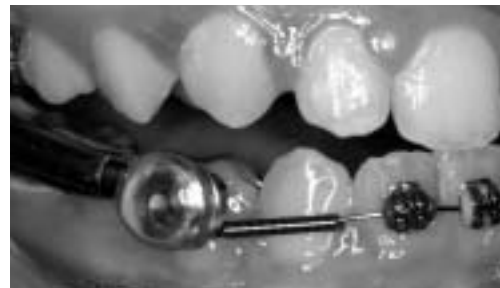Space closing or opening designs require brackets for anchorage on the upper and lower arches.



When indicated, negative torque brackets (-5° to -10°) are placed on lower incisors to counteract flaring.

Therapy usually takes about a year, but can be shorter or longer. The appliance is activated two to four times during treatment. Clinicians will activate the appliance 3 to 4mm approximately every 10 to 14 weeks, maintaining an edge-to-edge relationship. Some clinicians are of the belief that smaller 1 to 2mm incremental advancements of the Herbst elicits a dental change while larger advancements of 3 to 4mm promote more of an orthopedic change.

The amount of activation and frequency of appointments is dictated by the clinician's comfort in managing the appliance.



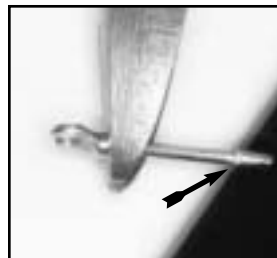

Activating or Advancing the Herbst Appliance

Before activating the appliance, check for loose crowns/bands. It is generally easy to tell if a band is loose by pushing on it. However, a crown may seem loose on the tooth when actually the molar is mobile. A crown is loose if you can wiggle it back and forth and it rocks or rotates. If in doubt and you don't want to force off the crown, cut a small hole in the occlusal surface with a high-speed handpiece. If saliva flows up through the hole, the crown is loose and will need to be removed and if possible recemented. If no saliva comes through, fill the hole in with glass ionomer. Then ask the patient if their tube and rod assembly has been falling apart frequently. This is a good indication that the tubes and rods may need to be replaced with longer ones.

Step 1. Unscrew the lower rods and remove. If you have previously secured the screws with Ceka Bond, take a pair of pliers with a flat end (How or Weingart pliers work well), grab the screw head and twist, breaking the seal. Then insert the allen wrench and unscrew. If you do not follow this procedure, the wrench may strip the screw threads or the insert channel in the screw head.

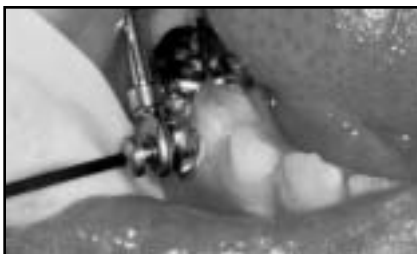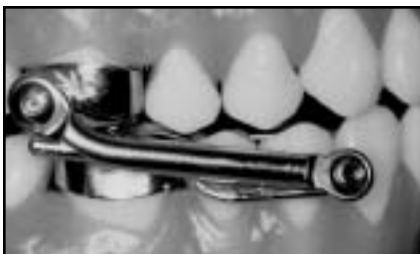Pearl: The ridges on allen wrenches tend to wear from use. Take a cutting disc and cut off the worn area to restore the hexagonal edge.

Step 2. Slide an advancement shim (whichever size is applicable) over the rod. Let the shim slide until it rests at the base of the eyelet. Crimp it down with pliers in an occlusogingival manner to the eyelet. This prevents tissue irritation. *To take the shim off, simply remove the crimp by crimping it slightly in a buccolingual manner and sliding it off the rod.* Slip the eyelet of the lower rod over the axle, and replace the screw using Ceka Bond to secure.



Score the rod 3mm from the end. If the score line is visible when the patient opens his/her mouth wide, you should replace the rod with a longer one. The Lab can score the rod or it can be done chairside.

Shims of various sizes.



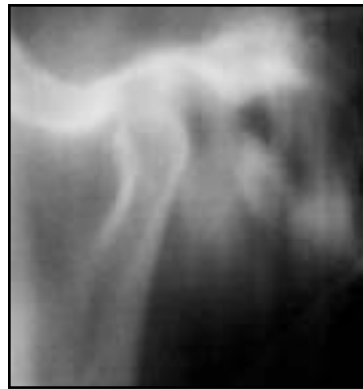Step 3. At each activation, check to make sure the midlines are still correct and the tubes and rods are functioning correctly. After several activations, the tubes and/or rods may need to be lengthened to keep from disengaging. If they need correction, refer to the Pre-Insertion Checklist, Section 2.

Final Activation and Determining When to Remove the Appliance

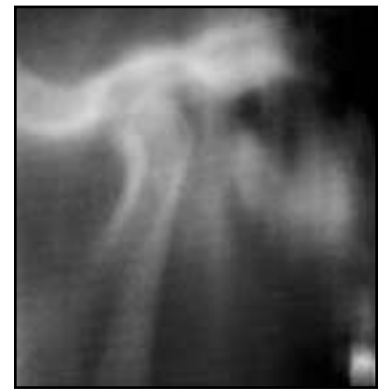Final activation has been taken as far as a Class III skeletal and dental position with the maxillary cuspids in an end-to-end relationship with the mandibular first bicuspid and held for an additional 10 weeks; while other clinicians activate to (in 2 to 4mm increments), or keep the patient at, an edge-to-edge Class I during Herbst therapy for about a year.

If available, take tomograms or transcranials to determine if the condyles are reasonably centered in the fossae. When the condyles are centered, schedule the patient for appliance removal.

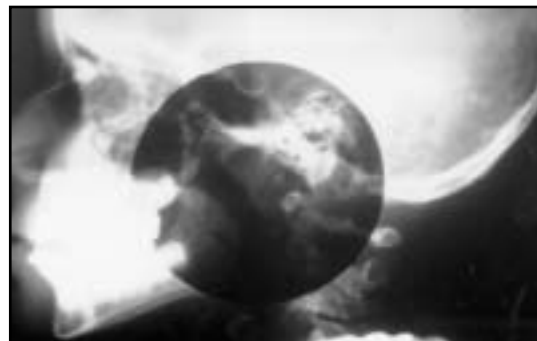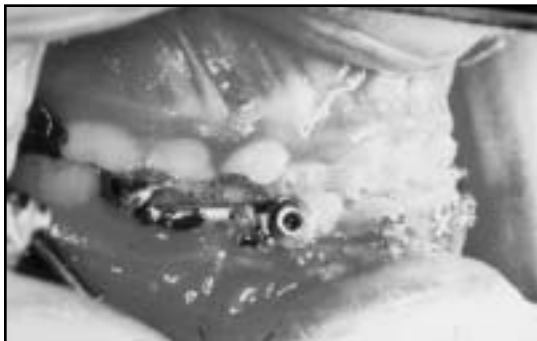If the condyles are reasonably central in the fossae, disengage the tubes and rods of the Herbst and take a post-Herbst cephalometric x-ray. Leave the appliance disengaged and schedule the patient for appliance removal as soon as possible (usually within a week).



Condyle not centered in fossa.



Condyle centered in fossa.

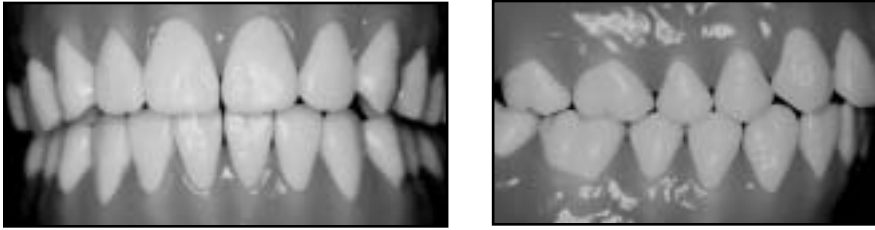


Note: If tomograms or transcranials are not available, the following are other options:

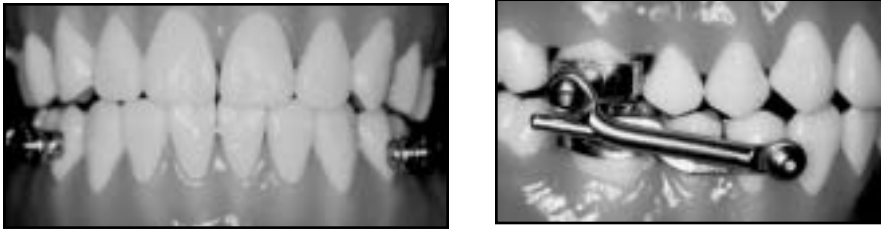
- Leave the appliance on an additional ten to twelve weeks, then disengage the patient, removing only the upper tubes and lower rods and waiting a few more weeks to determine if the patient relapses too much.
- Hold the patient in the desired corrected position for an additional five months.
- If the patient is older, has an open bite, has a high mandibular plane angle, or is a severe Class II, hold the patient in a slight overcorrected position longer than the additional five months.

Changes Resulting from Herbst Treatment

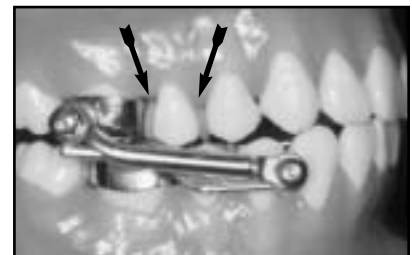Before Herbst treatment.



Herbst treatment completed and ready for appliance removal.



Pearl: When it is determined that the patient is ready to be rescheduled for Herbst removal and will be continuing with finishing treatment, it is advantageous from a production/scheduling standpoint to place separators at this time. At the next visit, remove the appliance, fit and cement posterior bands and bond the teeth as indicated. This sequence will save several appointments.

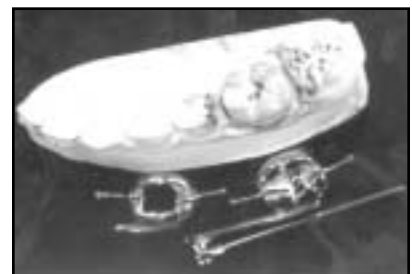

Breakage and Repair

Because of the availability of new materials and technology over the last few years, we don't see as much breakage of the banded or crown appliances. As discussed previously, stronger band materials along with the addition of support wires has dramatically decreased problems associated with the banded Herbst. Better fabrication techniques have increased the reliability of crown designs, making it very popular. Another factor in reducing breakage is the use of laser technology. This technology enables the incorporation of mini screws, archwire and extended tubes as well as a myriad of other accessories to the Herbst without causing degradation associated with high heat-soldering processes. However, breakage does occur and a section of the appliance may need to be repaired or replaced. Then work models should be taken and sent to the lab along with the broken piece.



Extended tubes laser welded to band.



Work model and replaced section of lower Herbst.

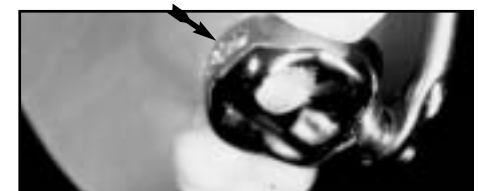
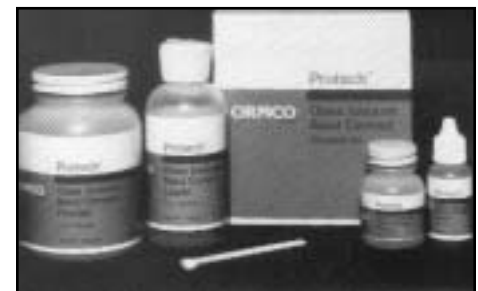Removal of the Crown/Banded Herbst

As the crown/banded Herbst appliance has increased in popularity, finding solutions to the more time-consuming aspects of managing the appliance has been addressed with rapid enthusiasm.

Through clinical experience, communication, and the willingness of orthodontic manufacturers to develop the auxiliary products to increase efficiency, great strides are constantly being made to perfect the procedure. A clinician once mastering the technique spends three to five minutes removing a crown/banded Herbst. Depending on state regulations for expanded staff duties and the removal technique being used, well-trained staff can remove banded and sometimes crown Herbst appliances. Listed in this section are a few of the current techniques being used today.

Before discussing the current removal techniques, let's reflect back on where the removal procedure actually begins. *For the crown Herbst, removal actually starts prior to cementation.*

1. If occlusal removal holes are not present in the crowns, using Vaseline or ChapStick on the dried occlusal surface will prevent the glass ionomer cement from forming a bond down in the grooves, making removal difficult.
2. Using a tinted glass ionomer such as Protech Gold (Ormco) helps to distinguish the cement from the tooth enamel when cutting crowns.
3. Placement of a horizontal slit to be used in conjunction with an occlusal removal hole later affords a purchase point necessary to accommodate certain styles of crown removal pliers.
4. Placing a vertical notch in the crown before appliance delivery simplifies the removal procedure by eliminating the need to use a bur subgingivally if the crowns are to be sectioned and if a crown splitter plier is to be used.



Horizontal slit and occlusal removal hole.

Vertical Notch



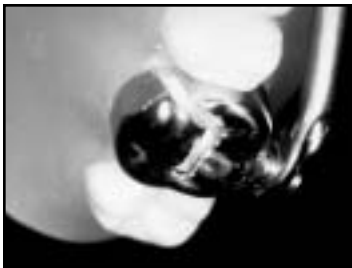
Crown Removal Cutting Technique

Step 1. Place a topical anesthetic on the gingival tissue in the areas where the crowns will be cut or where a crown splitter will be used.

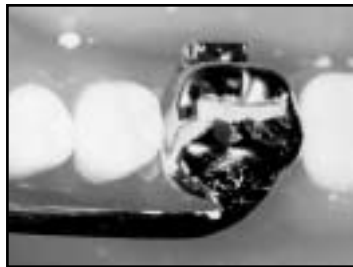Step 2. Remove the lower screw and rod assembly because they will be in the way during the cutting procedure. Leave the upper tubes assembled. They will be used as leverage when removing the cut crown from the tooth.

Step 3. If applicable, remove the composite material from occlusal rests to free them from the teeth.

Step 4. Using a bur, cut the crowns occlusally and down the mesioingival margin. On the upper crowns, make the cut occlusally and down the mesiopalatal cusp. On the lower crowns, make the cut occlusally and down the mesiobuccal cusp. *An 1171 or 557 bur works very well to cut crowns.*

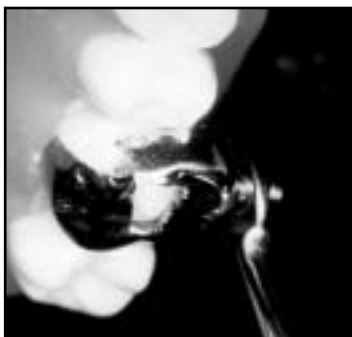


Maxillary crown cut.

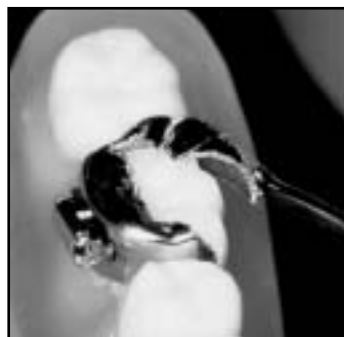

Mandibular crown cut.

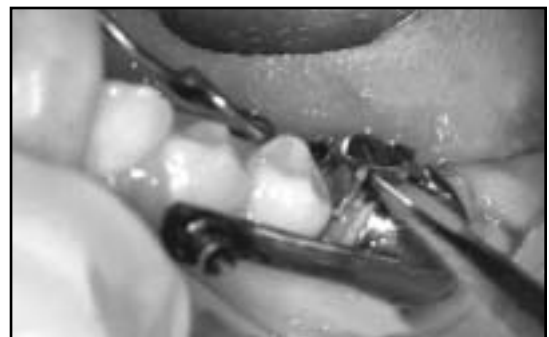Step 5. The crowns are then removed with a rocking and peeling motion using the attached upper tube and the lower cantilever for leverage. Simultaneously, pliers may be used to grab the crown, helping to complete the removal. A small screwdriver may also be used to get under a crown to help pry it off.



Peeling cut maxillary crown from tooth.



Peeling cut mandibular crown from tooth.



A small screwdriver may also be used to get under a crown to help pry it off.

Crown Removal Plier Technique

Step 1. Place a topical anesthetic on the gingival tissue in the areas where the crowns will be removed.

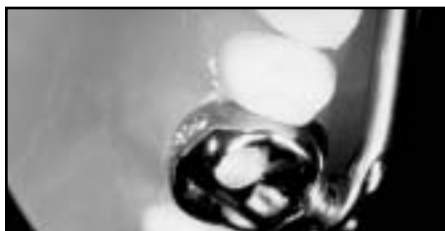Step 2. Remove the lower screw and rod assembly because they will be in the way during the cutting procedure. Leave the upper tubes assembled. Tubes will be used as leverage when removing crowns from teeth.

Step 3. If applicable, remove the composite material from occlusal rests to free them from the teeth.

Step 4. Place a crown removal hole 2 to 2.5mm in diameter in the occlusal surface of the crowns. *An 1171 or 557 bur works very well to cut crowns.* Place the tip of the plier into the occlusal hole and slide the lower lever under the gingival portion of the crown for the upper and under the cantilever arm for the lower. Apply pressure and the crown will snap off.

Clinicians have expressed that combining the previously described cutting technique with the crown removal plier technique makes removal of crowns much easier.

Maxillary

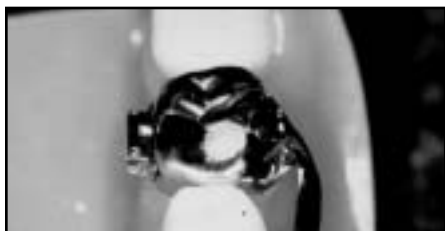

Crown with removal hole.



Crown removed with crown removing plier.

Mandibular

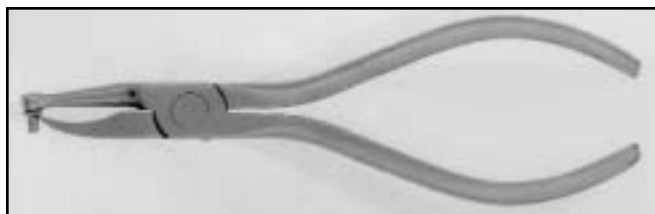


Crown with removal hole.



Crown removed with crown removing plier.

Pearl: On the upper crown, place a horizontal slit on the mesiolingual corner to act as a purchase point for the pliers. *(Many crowns are slightly subgingival and accessing the edge of it could be uncomfortable for the patient.)*



Chastant Crown Removing Plier

Crown Removal Slitting Plier Technique

Step 1. Place a topical anesthetic on the gingival tissue in the areas where the crowns are to be removed.

Step 2. Remove the lower screw and rod assembly because they will be in the way during the cutting procedure. Leave the upper tubes assembled. The upper tubes will be used as leverage when removing the cut crown from the tooth.

Step 3. If applicable, remove the composite material from occlusal rests to free them from the teeth.

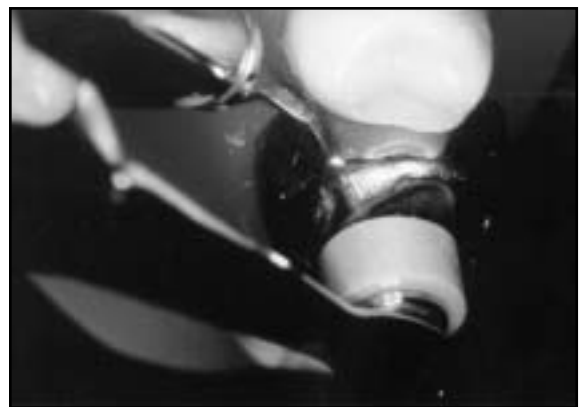Step 4. Place the sharp point of the blade of the crown slitting plier in the notch and the pad of the plier on the occlusal crown surface. The plier should be held at a slight angle to the occlusal plane.

- Maxillary crown: Hold the slitter slightly below the occlusal plane.
- Mandibular crown: Hold the slitter slightly above the occlusal plane.

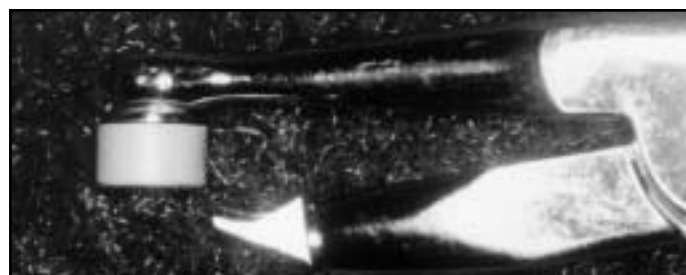This slight angling enhances attack of the point and blade of the slitter, keeping the point riding underneath the crown in an occlusal direction. As slitting occurs, the width of the blade forces the crown apart and the crown is removed easily. The crown usually comes off in the jaws of the slitter or is aided by peeling the crown from the tooth.



Removal notch placed in crown prior to cementation.



Maxillary crown removal with slitting pliers.



Crown Removal Slitting Pliers

Crown/Band Removal “Thumper” Plier Technique

All stainless steel crown appliances share the same problem. Difficult removal is the common denominator. Using the Thumper plier removal technique allows rapid and virtually painless removal of all stainless steel crowns and bands at the end of treatment. *Another advantage of this technique is if an appliance becomes loose on one side, it allows recementation without damaging the crowns.* Also, adding crown removal holes and notches to crowns during fabrication is not necessary when using this technique.

Step 1. Place a topical anesthetic on the gingival tissue in the areas where the crowns are to be removed.

Step 2. Remove the lower screw and rod assembly because they will be in the way during the cutting procedure. Leave the upper tubes assembled. The upper tubes will be used as leverage when removing the cut crown from the tooth.

Step 3. If applicable, remove the composite material from occlusal rests to free them from the teeth.

Note: Because of the shape of the teeth, upper crowns should be removed from the palatal side and mandibular crowns from the buccal side. The same positions would be used if removing bands.

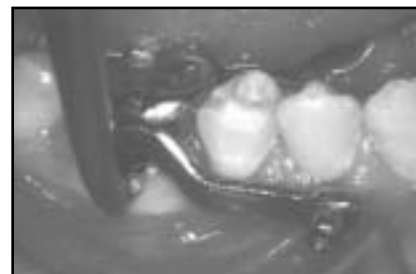Step 4. Cock the “Thumper” plier by pressing the end down against a hard surface. Engage or hook the tip of the blade against the margin of the crown, hold slight tension and trip the trigger. Usually two trips of the trigger is enough to loosen the crown/band.



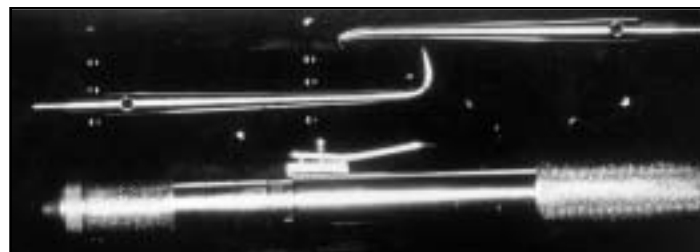Plier cocked on hard surface.



Tip of wide blade engaged against the palatal margin of upper crown.



Tip of wide blade engaged against the buccal margin of lower crown.



The “Thumper” is a German instrument (S-U Crown Butler) distributed in the U.S.A. by Thumper, Inc. c/o Dr. Joe Mayes Lubbock, TX.

Band Removal Technique

Removal of banded Herbst designs is fairly simple and rarely requires cutting a band. Most of the time a band removal plier is used and standard band removal techniques are applied. If the banded Herbst appliance is designed with a lingual arch, it is sometimes helpful to cut out the lingual arch prior to band removal.

Step 1. Place a topical anesthetic on the gingival tissue in the areas where the bands are to be removed.

Step 2. Remove the lower screw and rod assembly because they will be in the way during the removal procedure. Leave the upper tubes assembled. They are hard to remove and will not be in the way when using a band remover.

Step 3. Remove archwires and if applicable, remove composite material from occlusal rests to free them from the teeth.

Note: Because of the shape of the teeth, maxillary bands should be removed from the palatal side and mandibular bands from the buccal side.

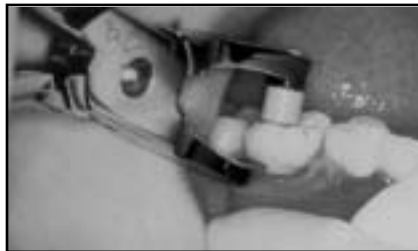Cement Removal

As discussed earlier, simplifying the removal of the cement for a crown Herbst started with cementation. If Vaseline or ChapStick was used on the occlusal surface of the tooth prior to cementation of a crown design appliance, most of the cement will have remained in the crown when removed. This occurs for several reasons: First, the crown was microetched, enhancing adhesion inside the crown, and second, Vaseline/Chapstick formed a barrier or shield between the tooth surface in the occlusal grooves. If these shields were not applied, or a removal/vent hole was incorporated during fabrication, which preclude the use of a shield, the cement will remain adhered to the occlusal grooves, making cleanup more time-consuming. Cement adhesion to the inside of the bands is also enhanced in banded Herbsts because of the microetching procedure.

Step 1. Place lip retractors for a clear working field.

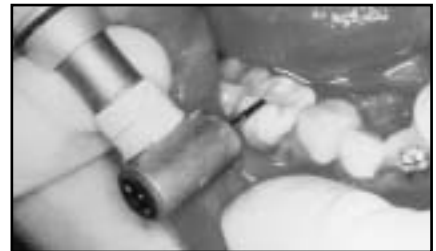Step 2. Dry the cement with a tooth dryer to help break the cement away from the tooth.

Step 3. Use a bond removal plier to break away as much of the cement as possible.



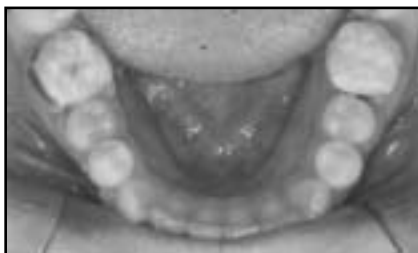Using bond removal plier to break away cement.

Step 4. Use a bur similar to the type used to remove bonding material in a slow-speed handpiece to finish the cleanup.

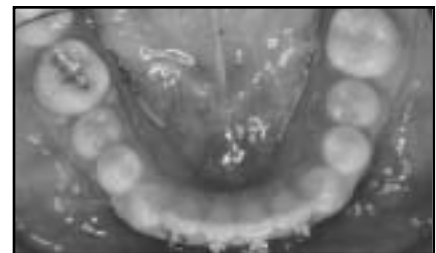


Using bur in slow-speed handpiece to finish cleanup.

Pearl: There is plenty of space between the molars and premolars when the crowns/bands are removed. This is a good time to place posterior bands and bond the teeth as indicated. This sequence will save several appointments.



Lower molars needing cleanup.



Lower molars cleaned up.

Note: Depending on the mechanics used during crown Herbst therapy, you may notice the first molars are intruded from having the crowns between the occlusion. The molars will elevate when braces and archwires are placed.

Continuation of Orthodontic Treatment

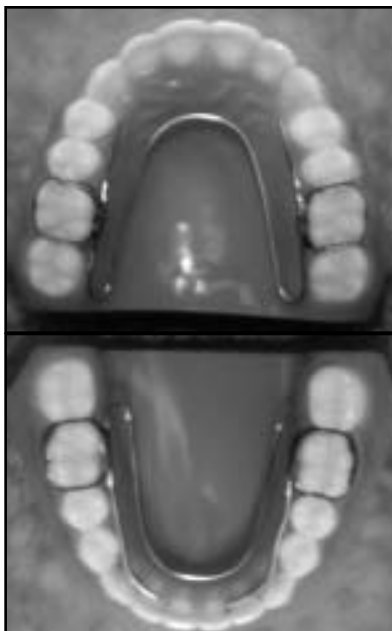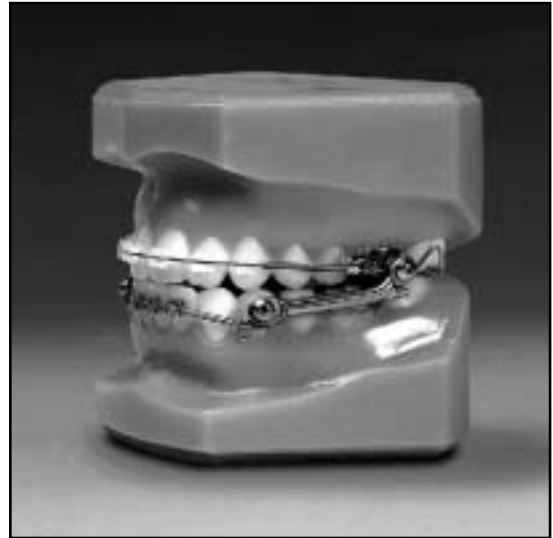Finalization of the occlusion is determined by a number of factors, such as whether or not you used orthodontic mechanics during Herbst therapy.

Some clinicians like to use brackets to control the torque of the teeth and to level and align them during standard Class II Herbst therapy. Intrusion and space closure/opening mechanics have recently been incorporated into treatment protocol requiring brackets to control incisal flaring and for added anchorage.

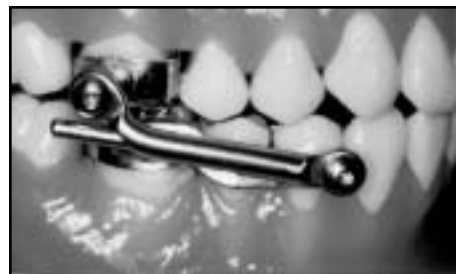When the Herbst is removed, the rest of the teeth will be banded or bracketed to finish detailing the occlusion.

Another philosophy is to simplify the correction of Class II cases by completing the patient's treatment in the following phases:

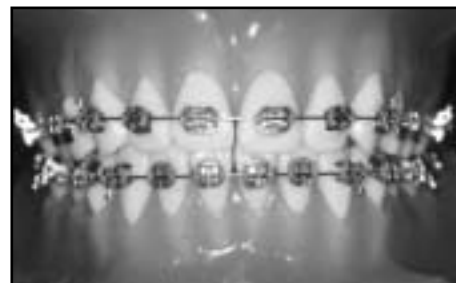1. Expand upper and/or lower arches.
2. Correct the AP with Herbst therapy.
3. Place brackets on uncrowded Class I cases.



Expansion of arches.



Correction of AP with Herbst.



Finishing with brackets in uncrowded Class I.

Appendix

Supply List

Herbst Auxiliary Products AOA/Pro

Allesee Orthodontic Appliances/Pro Lab
Wisconsin (800) 262-5221
International for Wisconsin (262) 886-1050
Connecticut (800) 826-2224
International for Connecticut (860) 741-3745

Demonstration Appliances for Consultation

*(2-Tone models on appropriate malocclusion)
AOA/Pro will fabricate individual appliances. Herbsts
or any other appliance required, per your prescription
on two-tone urethane models to enhance patient
consultations and staff education.*

Herbst Starter Kit

Assorted mechanism parts in box.
(shims, tubes, rods, screws, wrench, Ceka Bond)

Miscellaneous Herbst Parts

Available as individual units.
Upper Tubes
Lower Rods
Shims/Bushings
Allen Wrench
Screws *(hex and slot)*

Herbst Mechanisms Offered by AOA/Pro

Ormco Malu Flip-Lock Atlas Axle

CEKA Bond

Available in a tube.

Comfort Caps

All styles available.

Cope Plastic For Invisi-Retainers

5" x 5" sheets, .030 or .040, box of 25

Herbst and Auxiliary Products Ormco Corporation

or your Ormco representative
(800) 854-1741

Incisal Brackets

*Negative torque (-6°) Damon 2
Negative torque (-5° & -10°) Mini Diamond
and Orthos prescriptions*

Bonding/Cementing Materials

Enlight LV (for bonding brackets)
Demetron 501 Curing Light
Ortho Solo
Protech Gold Glass Ionomer (Intro Kit) #740-0255

Crowns

Ormco Crown Fit Kit #600-0100
Ormco CBJ Preform Kits
Ormco Crowns (extras or if fitting own crowns)

Pliers

AEZ:
CBJ Three-Jaw (cantilever bending) #803-0450
Crown Contouring #800-0160
Crown Removal (Chastant) #803-0610
Crown Slitter #803-0430
ETM:
Bird Beak #800-0139
Weingart Utility #800-0158

Wire

Copper Ni-Ti Archwires
Copper Ni-Ti Coil Springs
Damon Align Wire Series
Damon Stainless

Miscellaneous Suppliers

Local Dental Supply House

Allwrap
Fuji I Glass Ionomer
Fuji GC Ortho LC Capsule (for bonding rests)
3M Crowns (extras or fitting your own crowns)
1171 or 557 burs Brassler or contact local dental supplier

Danville Engineering (800) 827-7940

Microetcher

Suggested Reading and Course List

There are many outstanding articles that have been published concerning the effectiveness of functional appliances in orthodontics. I have selected a few that discuss the Herbst (or sometimes called Bite Jumper). They have been written within the last ten years, primarily in the United States. An extended list is available upon request.

Articles with Related Interest

Clinical Impressions (published by Ormco – access issues at www.ormco.com/ci)

- Mayes, Joe H.: Improving Appliance Efficiency with the Cantilever Herbst – A New Answer to Old Problems, Vol. 3, No. 2., 1994.
- Mayes, Joe H.: Simplified Treatment Mechanics (STM), Part I...or getting the overhead back below 50%!, Vol. 4, No. 4, 1995.
- Mayes, Joe H.: Simplified Treatment Mechanics (STM), Part II...or how to look just as forward to Monday as you do to Friday, Vol. 5, No. 1, 1996.
- Smith, John R. (Bob): A Treatment Efficiency Philosophy...That Really Works, Vol. 5, No. 1, 1996.
- Mayes, Joe H.: The Single-Appointment Preattached Cantilever Bite-Jumper, Vol. 5, No. 2, 1996.
- Mayes, Joe H.: The Cantilever Bite-Jumper System – Exploring the Possibilities, Vol. 5, No. 3, 1996.
- Chastant, Robert B.: Bite Jumpers: Effective Strategies for Streamlining Crown Placement and Removal, Vol. 6, No. 1, 1997.
- Mayes, Joe H.: The Molar-Moving Bite Jumper (MMBJ), Vol. 7, No.1, 1998.
- Smith, John R. (Bob): Matching the Herbst to the Malocclusion, Vol. 7, No. 2, 1998.
- Dischinger, Terry: Full-Face Orthopedics with One Multifunctional Appliance – No Cooperation Required, Vol. 7, No. 4, 1998.
- Hutta, Lawrence, Predictable Herbst Removal, Vol. 9, No. 1, 2000.
- Dischinger, Terry; and Dischinger, Bill: Treating the Class II Low-Angle Brachycephalic Patient, Vol. 10, No. 3, 2001, The AOA/Pro Corner.

AOA Appliances, etc.

(published by Ormco and Allesee Orthodontic Appliances/Pro Lab – access issues at www.ormco.com/aoa)

- Connelly, Harold: Cutting to the Chase, Vol. 4, No.1, 2000
- Dischinger, Terry: Open-Bite Intrusion Herbst, Vol. 5, No.2, 2001

Journal of Clinical Orthodontics

- Dischinger, T.G: Edgewise Herbst Appliance. Vol. 29, 738-742, 1995.
- White, Larry W.: Current Herbst Appliance Therapy. Vol. 28, No. 5, 1994.

Books

Orthodontic and Orthopedic Treatment in the Mixed Dentition

- James A. McNamara, Jr., D.D.S., Ph.D.; and William L. Brudon, Associate Professor Emeritus, The University of Michigan. Needham Press, P.O. Box 130530, Ann Arbor, MI 48113-0530.

In-Office “Hands-On” Courses

(With Emphasis on Noncompliant Treatment, Efficiency, Marketing and Profitability)

- Dr. Keith Black, Asheville, NC (828) 277-7103
- Dr. Terry Dischinger, Lake Oswego, OR (503) 635-9084
- Dr. Duane Grummons, Spokane, WA (509) 535-2011
- Drs. James Hilgers and Steve Tracey, Mission Viejo, CA (714) 830-4101
- Dr. Larry Hutta, Columbus, OH (614) 885-2000



As demand for nonextraction, nonextraction treatment continues to grow, the crown/banded Herbst appliance is an increasingly prescribed option for the correction of Class II malocclusions. Its multifunctional capabilities also include expansion in the maxillary and/or mandibular arches, space closure or opening bilateral or unilateral in either or both arches, as well as intrusion mechanics applied in the treatment of high-angle open-bite cases. Experience has taught us that each clinician may require a unique design and experience a considerable learning curve in the clinical management of these appliances. If questions arise, we welcome and encourage dialogue between your practice and our Herbst technical support team and customer support staff.

(800) 262-5221 or (262) 886-1050 (Sturtevant, WI Laboratory)
(800) 826-2224 or (860) 741-3745 (Enfield, CT Laboratory)

Paula S. Allen-Noble

(800) 990-3485 or (985) 727-2985 Fax: (985) 727-9801
E-mail: allenp@sybrondental.com
Mandeville, LA (home office)

Max A. Hall

(800) 262-5221 or (262) 886-1050 Fax: (262) 886-6879
E-mail: hallm@sybrondental.com
Sturtevant, WI (Wisconsin laboratory)

Copyright 2002 All Rights Reserved
Sixth Edition, Revised: June 2002

Allesee Orthodontic Appliances/Pro Lab

P.O. Box 725
13931 Spring Street
Sturtevant, WI 53177 U.S.A.
(800) 262-5221 or (262) 886-1050
Fax: (262) 886-6879

P.O. Box 2000
6 Niblick Road
Enfield, CT 06082 U.S.A.
(800) 826-2224 or (860) 741-3745
Fax: (860) 741-7655

AOA/Pro is a subsidiary of Ormco Corporation

Visit our Web site at www.ormco.com/aoa