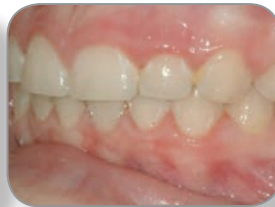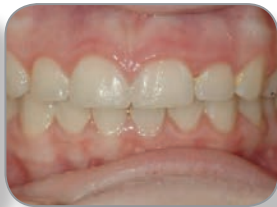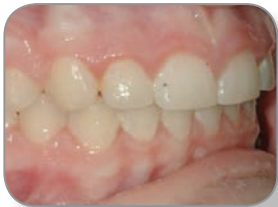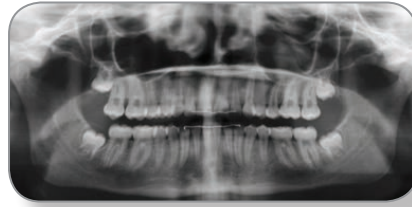


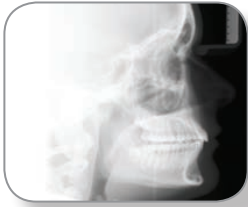# AdvanSync™ 2

CLASS II MOLAR-TO-MOLAR

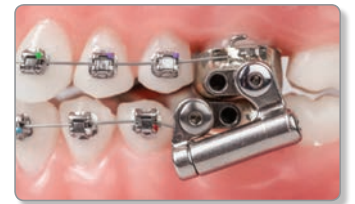

## Case Studies

Volume I

### Contents Include:

- Pretreatment Diagnosis
- Treatment Objectives & Plan
- Progression
- Treatment Time
- Case Discussion

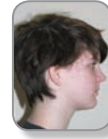
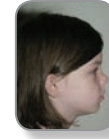
# TABLE OF CONTENTS

1. Class II, Division I - Dr. Janice Sommerville



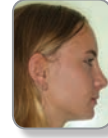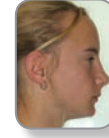3. Class II, Missing Premolars - Dr. David Cummins



6. Class II, Division I - Dr. Yutaka Takeuchi



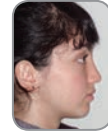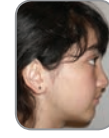9. Skeletal II Deep Bite - Dr. Ashley Smith



12. Class II, Division I - Dr. Sandra Hayasaki



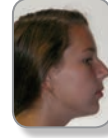15. Class II, Division I - Dr. Eric Wu



18. Class II, Deep Overbite - Dr. Bill Dischinger



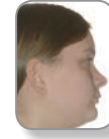22. Class II, Division I, - Dr. Stanley Robison



26. Class II, Division I - Dr. Andres Perdomo



29. Brachycephalic - Drs. Terry and Bill Dischinger



**This workbook is designed to aid in case selection and show what types of treatment can be achieved with the AdvanSync 2 appliance. AOA would like to thank all of the Doctors who have taken the time and effort to submit cases. Without your help, this case study publication would never have been possible.**

**Thank you!**

\* The opinions expressed in these case studies are those of the respective doctors. AOA is a medical device manufacturer and does not provide medical advice. Clinicians should use their own professional judgment in treating patients.

800.262.5221  
www.aolab.com

## A Herbst™ Journey

I had a Herbst™\* as a teenager. How are my memories of that time in my life? Well... not exactly great. Although as an adult, I look at the results it gave me compared to the upper bi extraction cases that were the norm back then, and I know it was worth it. But...

The second Dischinger to have a Herbst was none other than Terry Dischinger himself. We treated him when he was in his late 50s. He had always been a Class II open bite that would have required surgery. Eventually, he developed a modified Herbst appliance that intruded the maxillary molars while the Herbst was correcting the Class II. The results are similar to what we see in today's technology using TADs to intrude the maxillary molars and autorotate the mandible. He claims his experience was an easy process, but my dad is kind of that way. It sure beat surgery though, but in watching from the other side, it didn't look all that comfortable.

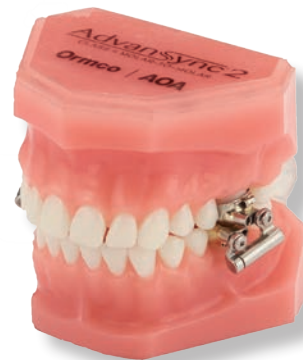Shortly after finishing his treatment, we decided to see if we could make a smaller Herbst appliance. Our purpose in attempting this design change was to improve the comfort of orthopedic Class II treatment for our patients. I was two boys into my now current four-boy family, and it was obvious they were following the Dischinger growth pattern and would require Class II correction. So we set off on a journey, and let me tell you, it was a journey much harder and more frustrating than we had dreamed.

Thus came AdvanSync™ 2 with modified enhancements, and this is the product we are still using today and have been for nearly 5 years. AdvanSync 2 is almost half the size of the miniscope appliance that we had been using and half of the size of the flip-lock design we used prior to that. It is well over half the size of what I had as a kid, which I can assure you. Because of the smaller size, it fits more in the posterior of the mouth. A bonus that came out of the smaller design was the ability to bracket every tooth forward of the appliance. With this new design, we bond all the teeth, and sometimes the mandibular second molars as well. When we are finished with the Class II correction and the appliance is removed, most of the Class I orthodontics has been accomplished as well, which allows us to quickly move to the end of treatment making our orthopedic Class II cases much more efficient. Since moving to the AdvanSync 2 appliance, we have dropped our average treatment time by over 6 months.

Today, with most of our current patients, I am waiting 2 to 4 months before hooking up the arms. For younger patients, this helps them ease into treatment with less to adjust to.

Since starting my Herbst journey over 35 years ago, I have seen a great progression in the comfort and efficiency of treating skeletal Class II patients. It has been rewarding to see my patients, especially my own children and nieces, go through a better experience than I did.

Dr. Bill Dischinger

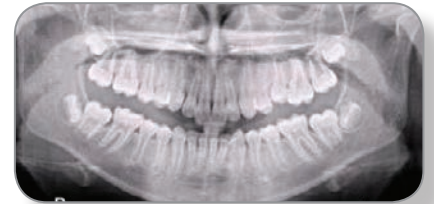
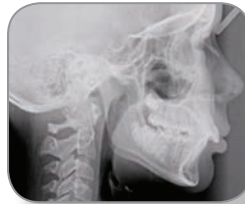
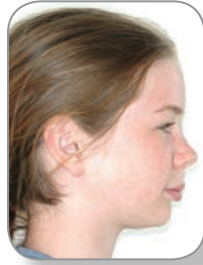
\* Herbst is a registered trademark of Dentaurum, Inc.

## Dr. Janice Sommerville, New Zealand

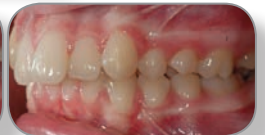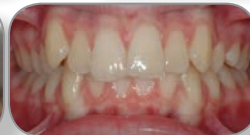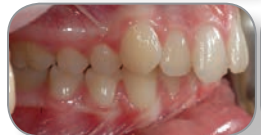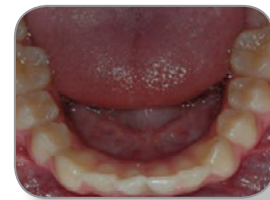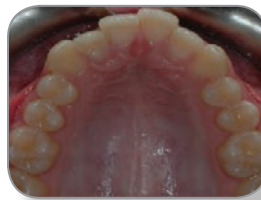### Pretreatment Diagnosis

Class II with average mandibular plane angle and lower facial height. Convex retrognathic profile. Lips together at rest, lower lip everted. 100% overbite, 6mm overjet. Moderate lower crowding. Mild upper anterior irregularities.

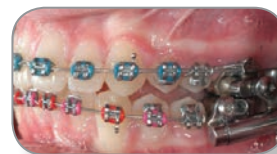
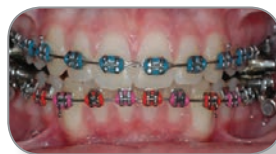
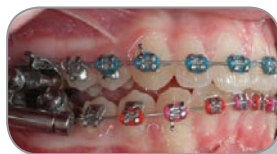### Treatment Objectives & Plan

- Correct the Class II malocclusion
- Correct overbite
- Correct overjet
- Reshape maxillary and mandibular arches



### Progression

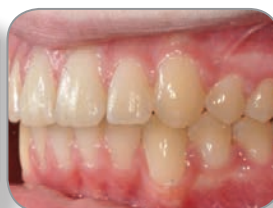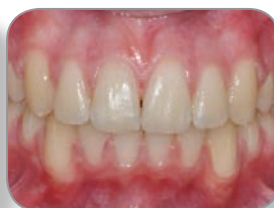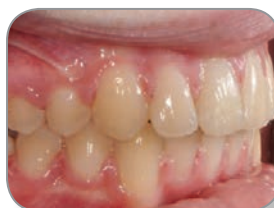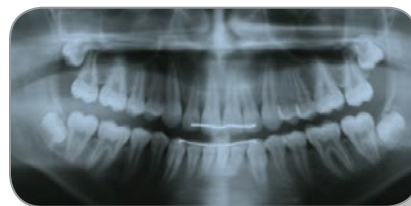


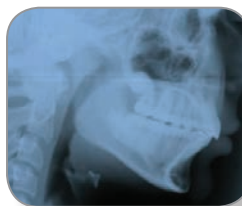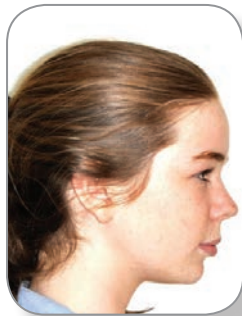**PEARL:** "Align teeth up to rectangular Cu Niti (16x22) archwires before fitting AdvanSync, replace the Cu Niti and maintain throughout the advancement phase.\* This archwire is strong enough to prevent breakage/tipping mesial to lower molars."

Dr. Janice Sommerville

## Treatment Time - 22 Months

- 1-26-2012 Placed Victory MBT .018 brackets upper and lower 5-5. Cemented molar band upper 1st/2nd molars and lower 1st molars. .014 Cu NiTi wires placed.
- 3-19-2012 Upper .018 Cu NiTi wire placed.
- 8-16-2012 Lower .018 Cu NiTi wire placed.
- 7-11-2012 Remove molar bands and cement AdvanSync 2 crowns on U/L 1st molars. Attach AdvanSync 2 telescoping rods.
- 8-28-2012 Lower .016 x .022 Cu NiTi wire placed. Progress photos taken.
- 10-17-2012 Upper .016 x .022 Cu NiTi wire placed.
- 12-05-2012 Activated AdvanSync 1mm each side.
- 02-20-2013 Activated AdvanSync 1mm each side.
- 4-17-2013 Activated AdvanSync 1 mm each side.
- 6-10-2013 Remove AdvanSync crowns and telescoping rods. Band upper 1st molars and lower 1st/2nd molars.
- 7-24-2013 Upper .016 x .022 stainless steel wire placed. Power chain upper 6-6.
- 10-1-2013 Lower .016 x .022 stainless steel wire placed. Start Class II elastic wear 1/4 inch 4.5 oz.
- 11-20-2013 Check finishing elastics. Lower impression for bonded lingual retainer.
- 11-21-2013 Deband. Placed upper bonded lingual retainer wire 2-2 and lower 3-3. Removed all brackets. Took upper alginate impression for a Hawley retainer. Took final x-rays and photos.





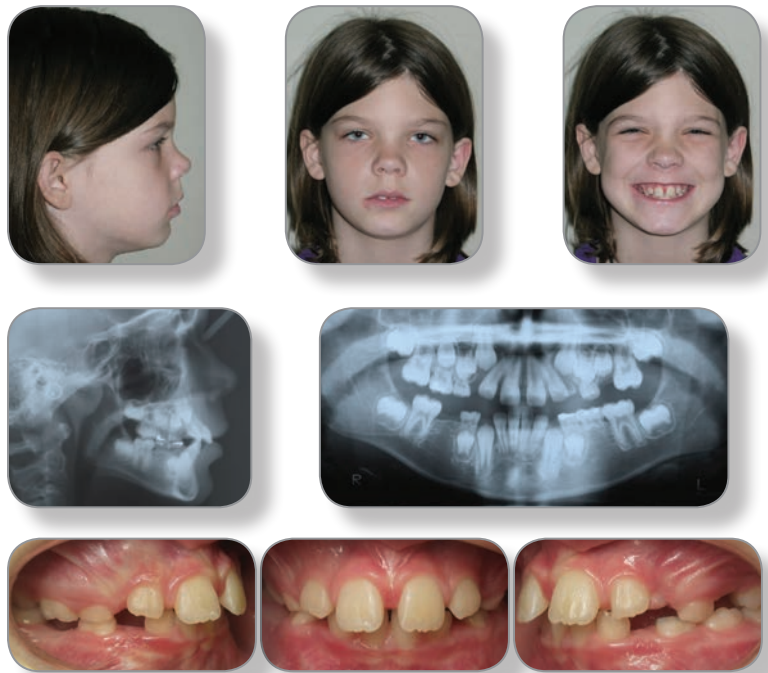# Class II, Missing Premolars

3

Dr. David Cummins, Bellingham, WA.

## Pretreatment Diagnosis

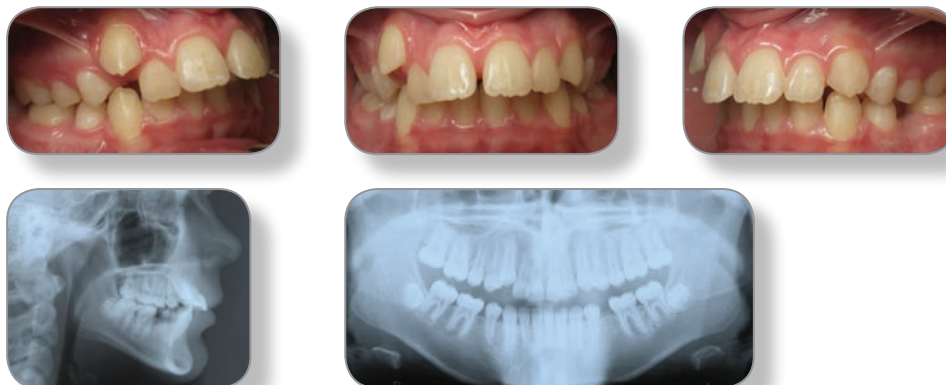Young female with Class II molar relationship. Mandibular retrusion with protrusive maxillary incisors. 33-50% overjet. 6-8 mm overjet. Spacing of the maxillary incisors and inadequate space for the maxillary canines to erupt. Congenitally missing the mandibular second premolars. The mandibular right deciduous second molar is missing and the left is severely resorbed.



## Treatment Objectives & Plan

- Class II, Division 1 malocclusion with congenitally missing mandibular second premolars will be treated in two phases.
- Simultaneous Class II correction and closure of the spaces of the congenitally missing mandibular second premolars in the second phase.

## Progression



## Treatment Time - 39 Months

### First Phase Treatment Plan (9 months)

1. Limited treatment.
2. Bond and align the maxillary arch.
3. Consolidate space in the maxillary incisors.
4. Open space for the maxillary canines.
5. Remove the mandibular left deciduous second molar.

### Second Phase Treatment Plan (30 months)

1. Bond and align the maxillary arch.
2. Deliver AdvanSync 2 and bond and align the mandibular arch.
3. Allow the maxillary molars to distalize to create space for the maxillary canine and reduce maxillary incisor protrusion.
4. Move the telescopes to the mesial hole in the maxillary crowns and the distal hole in the mandibular crowns to close the second premolar space.

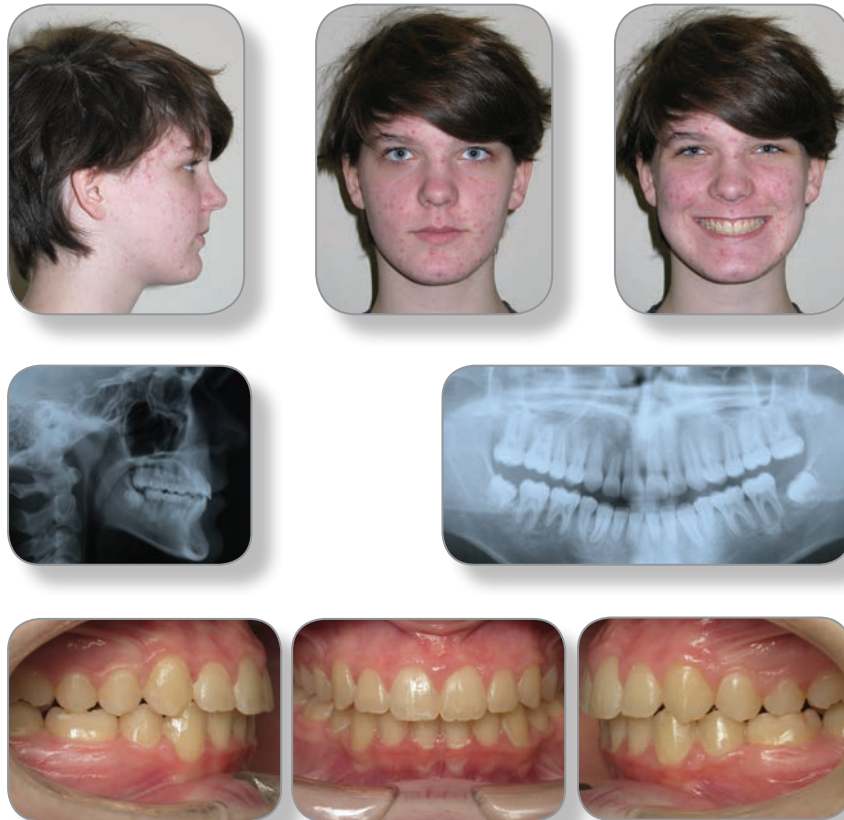
### Second Phase Treatment Sequence

1. Direct bonded maxillary brackets.
2. Rectangular stainless steel upper archwire with negative incisor torque.
3. Delivered AdvanSync 2, direct bonded lower 4-4, stopped upper archwire tied back, telescopes in distal holes of mandibular crowns.
4. Rectangular lower arch wire.
5. After 5 months activated AdvanSync 2 mm both sides.
6. After 7 months activated AdvanSync 2 mm both sides.
7. After 9 months moved telescopes to mesial holes of maxillary molar crowns and removed tie backs.
8. Removed mandibular crowns after 11 months, stopped upper archwire, bracketed lower molars.
9. Started Class II elastics at 12 months.
10. Removed maxillary crowns at 14 months, brackets maxillary molars.
11. Closed remaining spaces.
12. Added lingual buttons to mandibular molars to assist in protracting 7's.

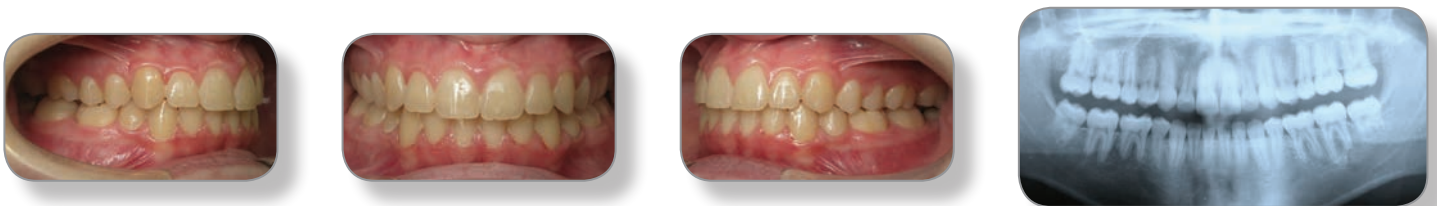## Case Discussion

At the end of the first phase the decision was made to remove the mandibular left deciduous second molar and plan to close space for the mandibular second premolars in the second phase.

Complete Class II correction and closure of the spaces for the missing premolars was achieved. Good root parallelism was maintained between the mandibular first molars and first premolars. An interesting residual benefit is the improved orientation for the mandibular third molars. If the third molars erupt, they will provide improved occlusion for the maxillary second molars. This represents a very powerful new treatment option. Closing space for missing mandibular second premolars in Class II malocclusions is typically avoided. The Molar-to-molar design of the AdvanSync 2 allows for simple and predictable mandibular space closure in Class II malocclusions. I have begun treatment planning all missing mandibular premolar Class II cases this way. This treatment offers great value-added for the patient, by avoiding the cost and continued maintenance of implants and crowns.



During a retainer check visit it was noted that the mandibular third molars did indeed erupt fully into occlusion.





## Dr. Yutaka Takeuchi, Ichikawa, Chiba Japan

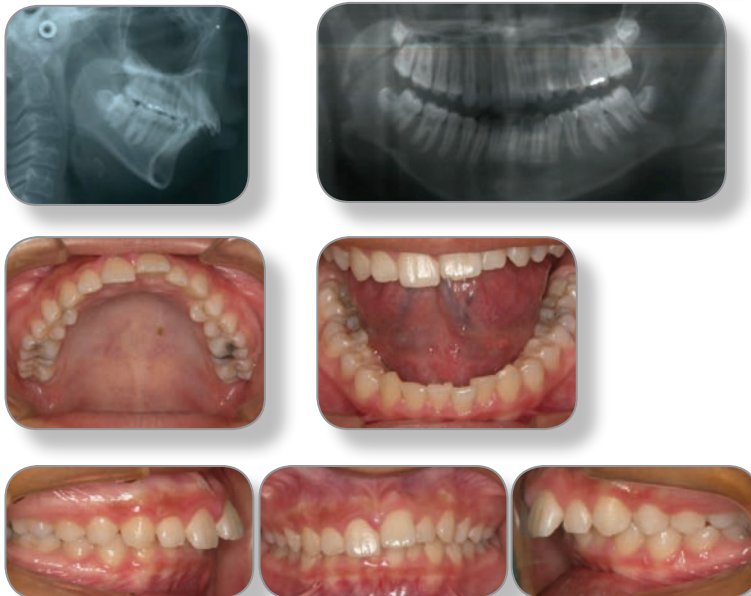### Pretreatment Diagnosis

Class II, Division I with lesser growth and retroposition of the mandible, narrow dental arches, dental compensation, minor crowding and difficulty in lip closure.

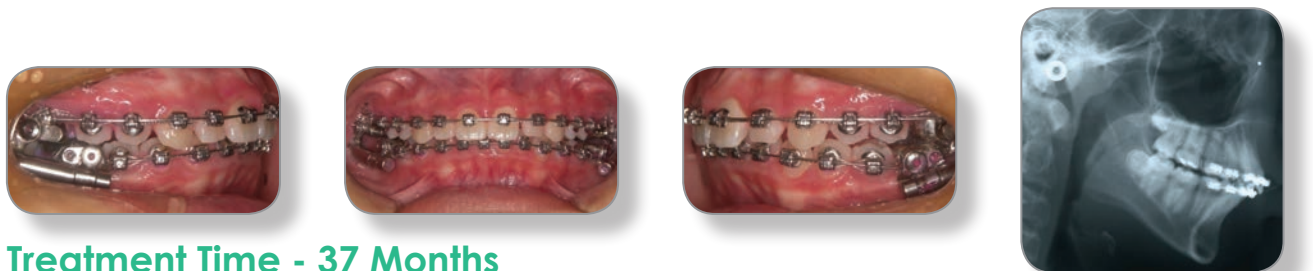

### Treatment Objectives & Plan

- Correct the Class II malocclusion
- Eliminate strain of the mentalis muscle
- Eliminate crowding
- Reshape maxillary and mandibular arches
- Flatten Curve of Spee
- Correct mouth breathing



### Progression



### Treatment Time - 37 Months

- 2-14-11 Placed Damon Q™ brackets U 5-5, L 5-5. Cemented AdvanSync 2, crowns on U & L 1st molars. U .014 Cu NiTi and L .013 Cu NiTi. Laced U 6-6.
- 3-26-11 .014 Cu NiTi placed on L.
- 7-30-11 Reactivated AdvanSync 2, 4mm.
- 9-13-11 U .014 x .025 Cu NiTi, L .016 counterforce NiTi, laced L 6-6.
- 12-25-11 Tomo to check if condyle is centered in fossa. Ready to remove AdvanSync 2.
- 12-27-11 Removed AdvanSync 2, sectionalized archwires, ceph and pan.

## Treatment Time (Cont)

- 1-6-12 Bonding U & L 6's. U .014 x .025 Cu NiTi, L .018 counterforce NiTi. Laced L 6-6.
- 5-30-12 U .019 x .025 TMA. L .017 x .025 NiTi REV. Laced L 6-6.
- 2-25-13 Bond tubes L 7's, .014 Cu NiTi overlay wire placed L 5-7.
- 3-24-14 Debond. Placed bonded lingual retainers. Removed all brackets. Took alginate impressions for wrap around type retainer for U.
- 3-26-14 Delivered wrap around type retainer. Took final X-rays and photos.

## Case Discussion

Damon Q brackets are used simultaneously with the AdvanSync 2. Upper arch has plus torque brackets on the incisors because the appliance tends to upright the incisors. The lower arch has -11 degree torqued incisor brackets to counteract tipping of the lower incisors. Anteroposterior relationship between the upper and the lower jaws was corrected with AdvanSync treatment. At the end of active treatment, Class I molar relationship, good interdigitation, good alignment of the teeth, proper overjet and overbite and excellent profile are obtained.

Active treatment time was 3 years and one month including 9 months of AdvanSync 2 treatment. Active treatment time was prolonged because it took another 6 months to correct lingual tipping of the lower second molars and the patient did not come for more than 6 months.

The first wires in our archwire sequence are upper and lower Cu NiTi (.013 or .014). Ends of the lower arch are cinched back. The patients are seen every 12 weeks. This is our normal interval between appointments. U6-6 were laced to prevent U6's moving distally and get maximum orthopedic effect on the upper arch.

The second wires are usually .014 x .025 Cu NiTi. On the upper arch the figure 8 lace is maintained, but a surgical hook is placed between the 1st molar and the second bicuspid. A steel ligature is placed between the hook on wire and the hook on the crown. The wire is cut flush with the distal of the archwire tube. The lower .014 x .025 is placed in the lower incisor brackets and into the archwire tube on the lower 2nd molar. Deep bite cases are more often seen in Japanese than in Caucasian. Anterior bite opening or removal of anterior interference are significantly important through treatment. When counterforce wire is used on the lower arch, figure eight lacing is strictly necessary to prevent the lower incisor from dumping forward.

### PEARL:

1. "For patients with proclined lower incisors, it is preferable to start the AdvanSync 2 treatment at the time when rectangular wires are inserted.\*
2. For patients with weak (hypofunction of the) orbicularis oris muscle, it is strongly recommended to enhance the muscle activity (myofunctional therapy) prior to or at the same time as the AdvanSync 2 treatment.\*
3. For patients with clockwise rotation of the mandible, it is preferable to remove\* anterior and/or posterior occlusal interference if it exists prior to the AdvanSync 2 treatment."\*

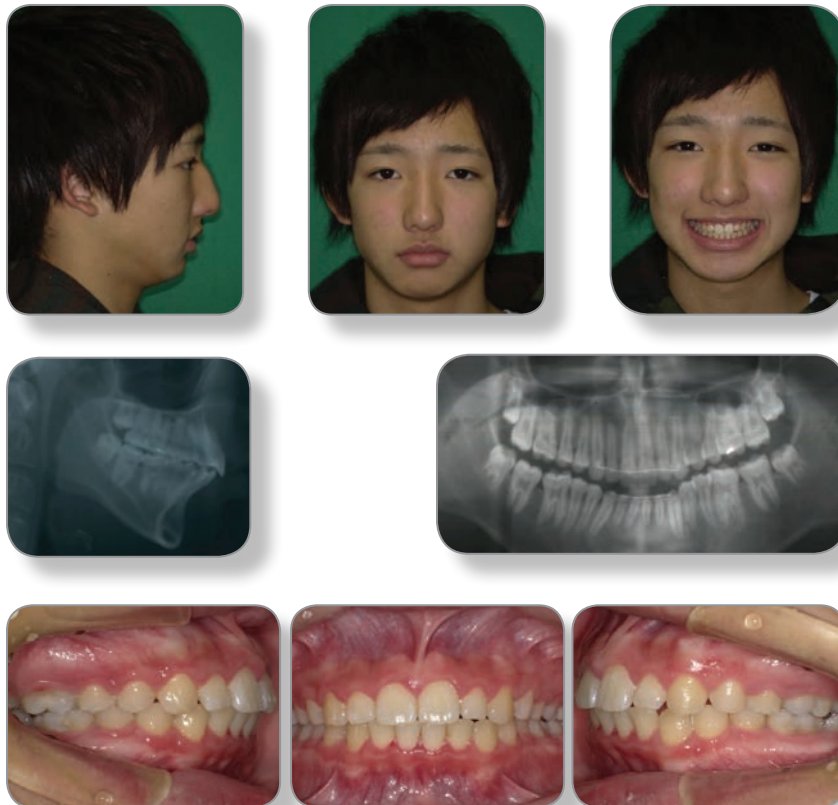Dr. Yutaka Takeuchi

## Case Discussion (Cont)

The third wire at six months after removal of the AdvanSync 2 on the upper arch is a .019 x .025 TMA. If more torque for the upper incisors is necessary, then a pre-torqued TMA .017 x .025 is placed. The figure 8 and the tie-back hooks are still present to prevent upper molar distalization. If the molars are distalized, the orthopedic effect is greatly decreased. We want to move the mandible to the maxilla with minimal movement of the upper teeth for maximum orthopedic effect. The lower archwire is .017 x .025 TMA and is placed with ends cinched. The goal for the wire sequence is to get the upper and lower arches leveled so the case can be overcorrected into the Class III dental position, so when the appliance is removed the mandible will rebound into a Class I.

Sometimes a .017 x .025 TMA needs to be bent stepping down the lower incisors. Sometimes the upper incisors are stepped up and then also the cuspids.

Therefore, in cases with deep bite or severe crowding, it might be needed to set a multibracket appliance prior to the AdvanSync 2 treatment. Thus AdvanSync 2 is not set simultaneously with brackets. It does not mean that treatment time gets longer and it does still mean "Class II treatment in Class I time".



# Skeletal Deep Bite

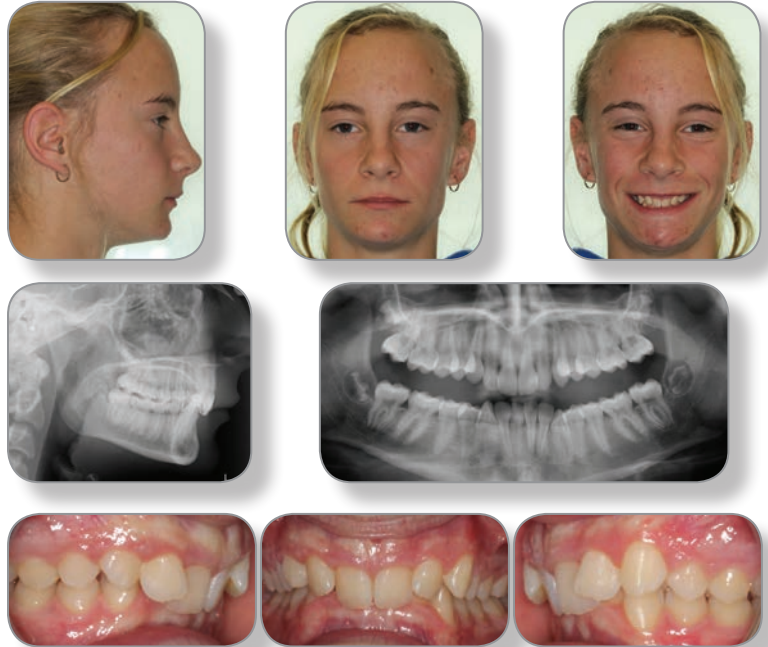Dr. Ashley Smith, Toowoomba, Australia

Treated with AdvanSync 2 and Insignia™

## Pretreatment Diagnosis

Skeletal Class II, Brachyfacial patient, 13 years old. Chief concern is the traumatic deep bite. (Patient has already commenced peak growth) She lives 2 hours from our practice.

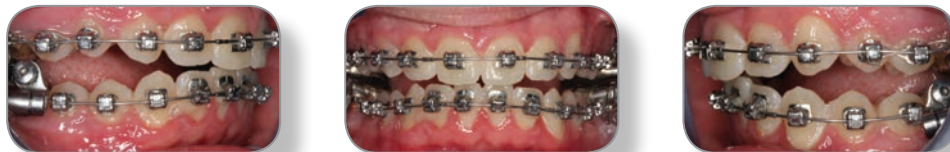Skeletal II Brachyfacial Profile. Lips are retrusive to the nose and chin and have a thin contour. Upper centrals are over erupted by 2 mm and retroclined 25 degrees.



## Treatment Objectives & Plan

- Treat non-extraction using Insignia (SL). Develop collapsed arches with Damon® mechanics, keeping the occlusion unlocked with:
  1. Composite resin, bite ramps on the first premolars.
  2. Then with the AdvanSync Appliance.
  3. With anterior Bite Turbos after the AdvanSync has been removed.
- Insignia design will hold the height of the upper laterals and align smile arc. The Insignia overlays must show the 36 46 moving mesial 3mm and the arches expanding as the curve of Wilson is leveled.

## Progression





## Treatment Time - 20 Months

### Bonding

U/L: Insignia SL, placing U & L .013 Damon® Cu NiTi arch wires with composite ramps on premolars to unlock bite.

**1.5 Months** - 1st visit.

U/L: Transitioned to .014 Damon Cu NiTi.

**2.5 Months** - 2nd visit.

U/L: Transitioned to .018 Damon Cu NiTi and fit AOA AdvanSync 1 week after separator placement. Archwires now pick up all second molars. U: Ligate upper first molars to first premolars.

**4 Months** - 3rd visit.

Transitioned to first Insignia archwire and activate AdvanSync 2mm/side.

U: .016 x .025 Damon Cu NiTi (Insignia).

L: .014 x .025 Damon Cu NiTi (Insignia).

**6 Months** - 4th Visit.

Activate AdvanSync LHS 4mm RHS 2mm.

**9 Months** - 5th visit.

Remove AdvanSync, Bond first molars with Insignia brackets using jigs, add Bite Turbos.

U: .018 archwire Damon Cu NiTi.

L: .014 x .025 Damon Cu NiTi (Insignia).

1/4 inch 2 oz Class II elastics

**10 months** - 6th visit.

Transitioned to U: .016 x .025 Damon Cu NiTi (Insignia)

L: .021 x .025 35 degree Cu NiTi (Insignia).

**11 Months** - 7th visit.

U: .018 x .025 Damon Cu NiTi (Insignia).

Chain upper cuspid to cuspid under the archwire, continue light Class II elastics.

**12 months** - 8th visit.

U/L: Transitioned to .021 x .025 - 35 degree Cu NiTi (Insignia) ligate upper cuspid to cuspid under archwire.

**13 Months** - 9th visit.

Breakage of bracket, continue light Class II elastics. Lower first molars replace with Titanium bracket.

**16 Months** - 10th visit.

U/L: Transitioned to .021 x .025 TMA, (Insignia) elastics night time only now - lower arch wire smoothed at lower first molars site as torque of Titanium was not a close match to original Insignia Torque.

**18 Months** - 11th visit.

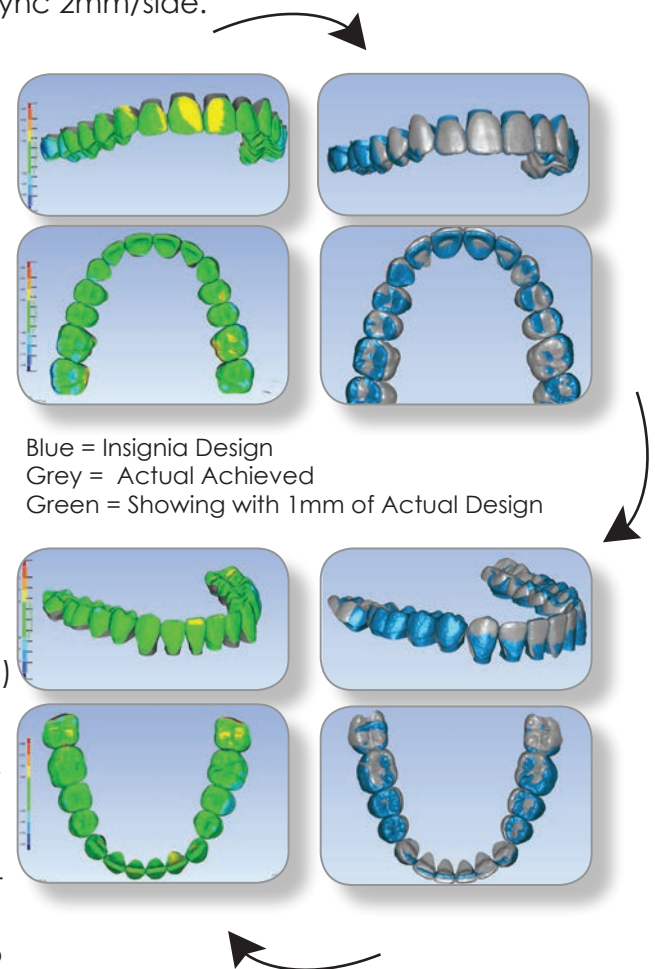
L: Transitioned to .019 TMA (Insignia) small detail bends 32 41.

**19th Month** - 12th visit.

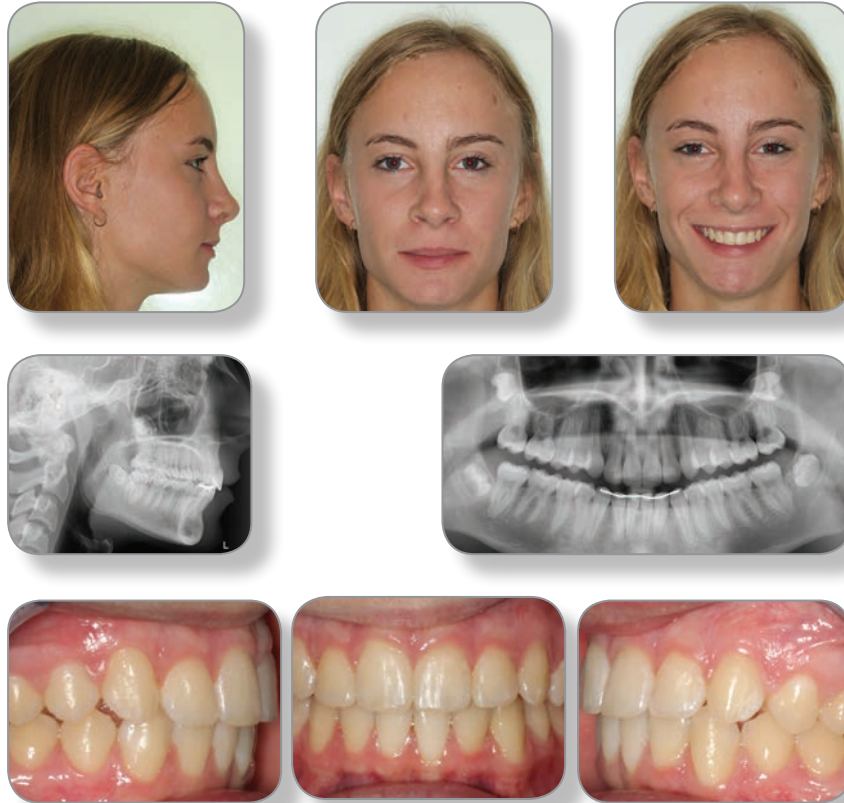Detail bends 11.

**20 Months** - 13th visit.

Remove all appliances. Incisal edges reshaped and polished. Bonded U 2-2 (Everstick) and L 3-3 flex (reliance) Also 1 mm essix clear retainer. Upper only, therefore allowing the lower dentition to settle.







## Case Discussion

All treatment objectives were achieved and the patient is pleased with her orthodontic result. The patient now has improved lip support, and the bite depth and buccal occlusion is much improved.

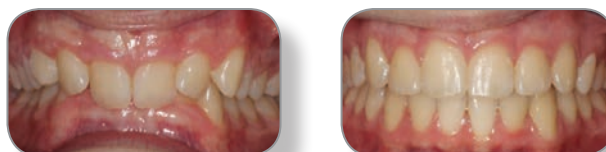The incisor proportions and gingival relationships are close to ideal as are the connectors and embrasures.

Ligating the AdvanSync upper first molar crowns to only the upper first premolars, has allowed some distalizing of the upper posteriors whilst leaving some overjet to allow for further lower arch advancement. All my AdvanSync cases are treated this way.

Wherever possible I ensure the archwire includes the 7's. Having the 7's all on the archwire helps minimize the intrusion of molars which can be an iatrogenic effect of AdvanSync treatment.

Starting this treatment with U/L .013 Damon Cu Ni-Ti archwire for 6 weeks then transitioning to only the U/L .014 Damon Cu Ni-Ti for 4 weeks keeps the forces very light allowing good arch development. It is also important to keep the deep bite unlocked to assist arch development.

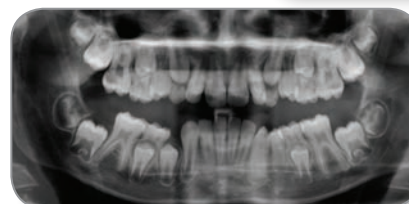
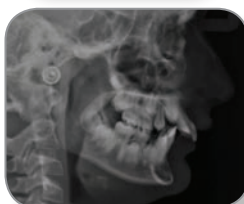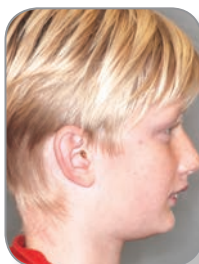In deep bite cases it is important to place anterior bite turbos on the day the AdvanSync is removed and support the change with light (2 oz) Class II elastics.



## Dr. Sandra Hayasaki, The Netherlands

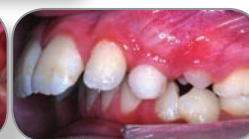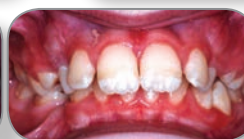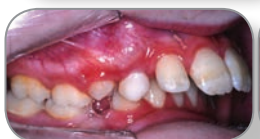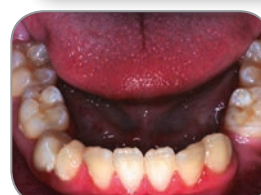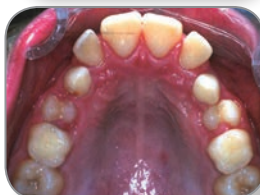### Pretreatment Diagnosis

Full step Class II, Div. I, convex profile due to a retrognathic mandible, slight facial asymmetry, full “lip-trap”, hyperactive mentalis muscle, accentuated curve of Spee, 100% overbite, deep mental labial fold, mandibular incisor inclination retroclined, maxillary incisor inclination proclination and narrow arches.



### Treatment Objectives & Plan

- Improve the oral hygiene
- Correct the Class II malocclusion
- Expansion of maxilla
- Correction of Curve of Spee
- Level and align
- Restorative treatment was planned to close the maxillary spacing between the upper left lateral incisor and the cuspid (Bolton discrepancy)
- Retention



### Progression

**PEARL:** After treating more than 600 patients with AdvanSync, my tip is: “Whenever treating Class II malocclusion with deep bite, to bond the second lower molars.\* This will help to open the bite and to advance the mandible and avoid relapse. The upper second molars are also important to bond in order to prevent a crossbite at the end of the treatment.”

Dr. Sandra Hayasaki

## Treatment Time - 28 Months

- 6-9-2011 Placed brackets and AdvanSync 2 crowns on U & L 1st molars, .014 Cu NiTi wires placed.
- 8-30-2011 New arch wires U & L .018 Cu NiTi.
- 9-11-2011 Rods were hooked up and figure 8 lace the upper arch from 6-6.
- 10-18-2011 New arch wires U .014 x .025 NiTi, L .017 x .025 NiTi reverse curve.
- 12-13-2011 Activation 4mm both sides.
- 2-14-2012 New arch wires U .019 x .025 NiTi, L .019 x .025 NiTi with step downs to correct Curve of Spee.
- 4-12-2012 Activation 4mm both sides.
- 5-8-2012 New arch wire U .016 x .025 SS (expanded).
- 6-21-2012 Activation 4mm both sides.
- 8-30-2012 Overcorrection held for 4 1/2 months.
- 1-10-2013 Removed AdvanSync 2.
- 1-17-2013 Bonding U & L 6's.
- 2-14-2013 Finishing elastics full time.
- 4-18-2013 Check finishing elastics.
- 6-13-2013 Placed bonded lingual retainers. Removed all brackets, alginate impressions for full cover retainers.
- 10-20-2013 Final X-rays and photos.
- 10-17-2013 Delivered full cover retainers.

## Case Discussion

The patient was treated with AdvanSync 2 on his first molars simultaneously with a fixed appliance Damon Q (positive torque upper incisors and negative torque lower incisors). At the placement appointment, the crowns were cemented but the rods were not yet placed. The reason is that we first needed to correct the accentuated curve of Spee by leveling the arches, otherwise the patient would not be able to occlude on the molars. This would most probably cause a relapse of the Class II malocclusion.

The leveling of the arches begins with placing the premolar brackets more gingivally at the same height as the tube of the AdvanSync 2 crowns. This step will avoid a lateral open bite when the AdvanSync is activated in a later phase.

The archwire sequence continued, and after 3 months, as soon as the axles of the crowns were parallel to each other, the rods were placed. At this point, the "figure 8 ligature lace" in the upper arch from 6-6 was placed in order to prevent the upper molar distalization.

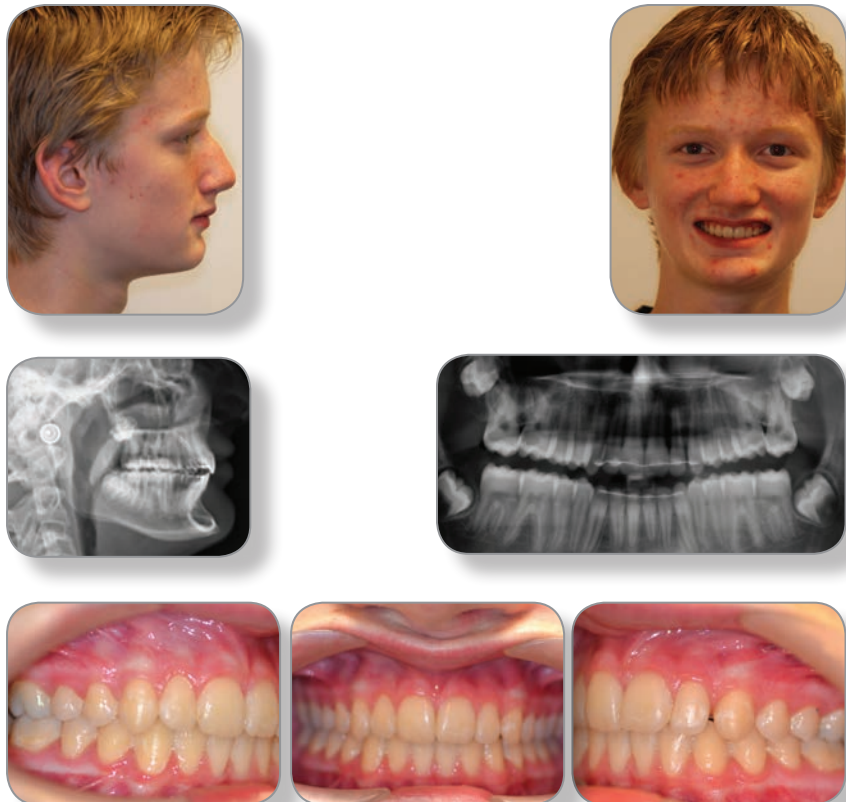
The AdvanSync 2 was activated every 2 months as long as the anterior/posterior correction was needed in order to obtain adequate overcorrection.

## Case Discussion (Cont)

The overcorrection was held 4 1/2 months and then the AdvanSync 2 was removed. About 1 week later, the brackets on the U & L 6's were placed and the traditional orthodontic finishing phase took place.

Once the AdvanSync 2 was removed, the mandible rebounded into a Class I within a few weeks.

Fixed retainers were placed in both arches and also invisible retainers were used at night time.

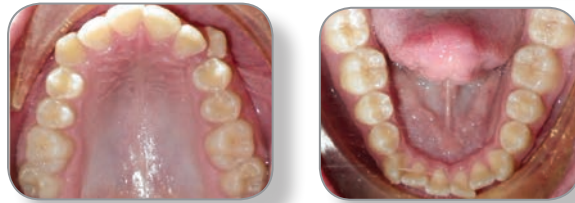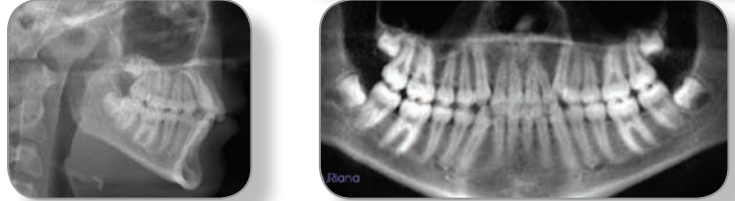




Dr. Eric Wu, Palo Alto, CA

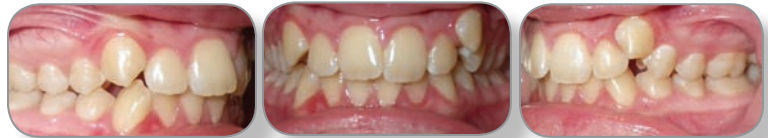## Pretreatment Diagnosis

Convex facial profile, dolichocephalic facial type, retrusive mandible/chin position, Class II, Division I with high mandibular plane angle, Class II dental cuspids and molars, 4 mm of overbite, 3 mm of overjet, narrow upper and lower dental arches, severe crowding in the upper arch, mild crowding in the lower arch, insufficient incisor show upon smiling.

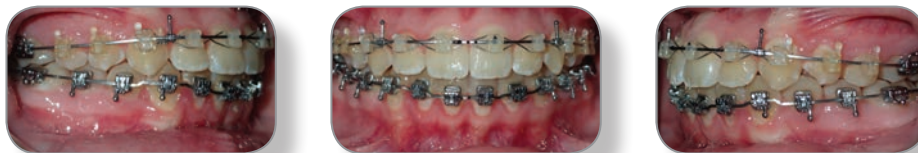

## Treatment Objectives & Plan

- Advance lower jaw and improve chin position
- Correct the Class II malocclusion
- Obtain correct overbite and overjet
- Broaden maxillary and mandibular arches
- Eliminate both maxillary and mandibular crowding
- Improve smile arc and incisor show upon smiling



## Progression



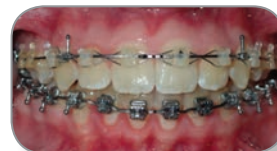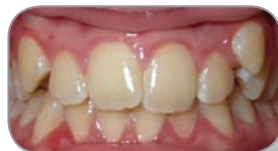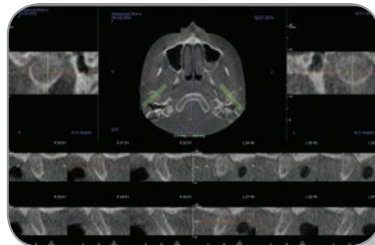


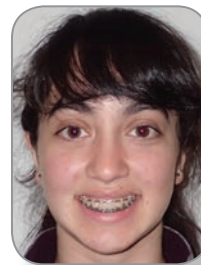
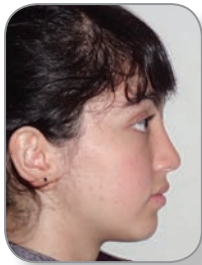## Treatment Time - 22 Months

- 4-16-2015 Placed brackets upper 5-5 only, open coil springs placed for crowded teeth.
- 7-28-2015 Engaged upper cuspids, cemented AdvanSync 2 with crowns on U/L first molars with a lower lingual arch connecting the lower crowns, .014 Cu NiTi wire placed.
- 9-21-2015 U .018 x .018 Cu NiTi, activated AdvanSync 2, 2 mm each side.
- 11-10-2015 U .020 x .020 Cu NiTi, activated AdvanSync 2, 2 mm left side only.
- 3-9-2016 Progress CBCT taken to verify condylar position prior to removal of AdvanSync 2 appliance, removed AdvanSync 2, bonded upper and lower first molar brackets and lower 5-5, open coil springs placed in lower arch for crowded teeth, upper and lower .014 Cu NiTi wires placed, Class II shorty elastics Parrots U3 - L5's night time only started paired with anterior "rainbow" elastic Ostrich L3-U1-U1-L3.
- 4-21-2016 Bonded upper and lower 7's repositioned upper 3-3 brackets for smile arc, upper and lower .014 Cu NiTi wires placed, continued night time Parrots U3-L5's night time only and anterior "rainbow" elastic Ostrich L3-U1-U1-L3.
- 6-9-2016 U/L .018 x .018 Cu NiTi wires placed, Figure 8 lace U 3-3, continued short Class II elastics Parrots U3-L5's night time only and anterior "rainbow" elastic Ostrich L3-U1-U1-L3.
- 7-21-2016 U/L .020 x .020 Cu NiTi wires, Figure 8 lace U3-3, continued short Class II elastics Parrots U3-L5's night time only and anterior "rainbow" elastic Ostrich L3-U1-U1-L3.
- 9-6-2016 Upper .019 x .025 Cu NiTi and Lower .020 x .020 TMA, discontinued anterior "rainbow" elastic, continued short Class II elastics Parrots U3-L5's night time only.
- 10-25-2016 Repositioned U2-2 brackets for smile arc enhancement, placed Upper .018 x .018 Cu NiTi, adjusted lower archwire with detailing bends, short Class II elastics Parrots U3-L5's night time only.
- 12-20-2016 Upper .020 x .020 TMA, continued detailing bends on the lower wire, short Class II elastics Parrots U3-L5's night time only.
- 1-2-2017 Detailing bends on the upper wire, short Class II elastics Parrots U3-L5's night time only.
- 2-21-2017 Debond appliances.

## Case Discussion

The lower arch was intentionally left unbounded initially to minimize lower incisor proclination and to maximize the amount of Class II correction/lower jaw advancement. A fixed lower lingual holding arch was utilized in the lower arch to help stabilize the lower crowns and maximize lower jaw advancement. Note that the lower lingual holding arch was fabricated intentionally short of the cingulums of the lower anterior teeth to prevent proclination of the lower incisors. In this case, upper arch was tied back 6-6 to prevent space from opening between upper first molars and bicuspid. H4 Go brackets were utilized in the upper arch and H4 metal brackets in the lower arch. Short, light Class II elastics were utilized at night time only post removal of the AdvanSync 2 appliance. The case has been finished and debonded; however, final records have not been taken yet as I have been having difficulty getting her to schedule her records appointment!



**PEARL:** "If you use a lower lingual holding arch, make sure you request it to be made a few millimeters short of the cingulum of the lower incisors\* to prevent lower anterior flaring!"

Dr. Eric Wu

## Dr. Bill Dischinger, Lake Oswego, OR

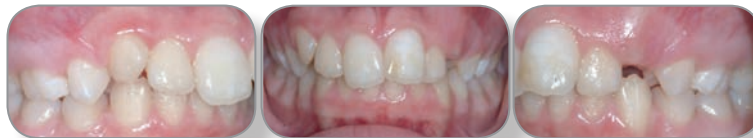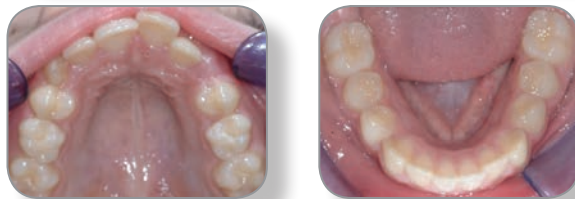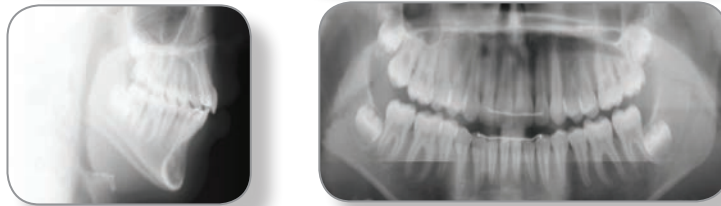### Pretreatment Diagnosis

Class II, Division I with high mandibular plane angle and lack of pogonion. Constricted arches with moderate crowding and moderate to severe overbite.

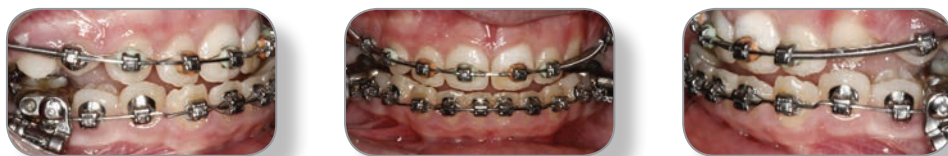

### Treatment Objectives & Plan

- Correct the Class II malocclusion
- Correct the overbite
- Develop and broaden both arches, particularly the maxilla
- Eliminate the maxillary crowding
- Improve the profile. With the lack of pogonion, we don't expect to perfect the profile with the chin position, but we can improve it.



### Progression



**PEARL:** "In some cases, mandibular arch leveling prior to attaching the AdvanSync 2 arms to the crowns needs to be done.\* Due to the severity of the overbite and lack of overjet due to the lingually inclined maxillary incisors, the incisors will be in an edge to edge position, propping the posterior occlusion open if the arms are hooked up. In this position, the arms will orient themselves into a more vertical position, leading to molar intrusion and no advancement of the mandible over time"

Dr. Bill Dischinger

## Treatment Time - 20 Months

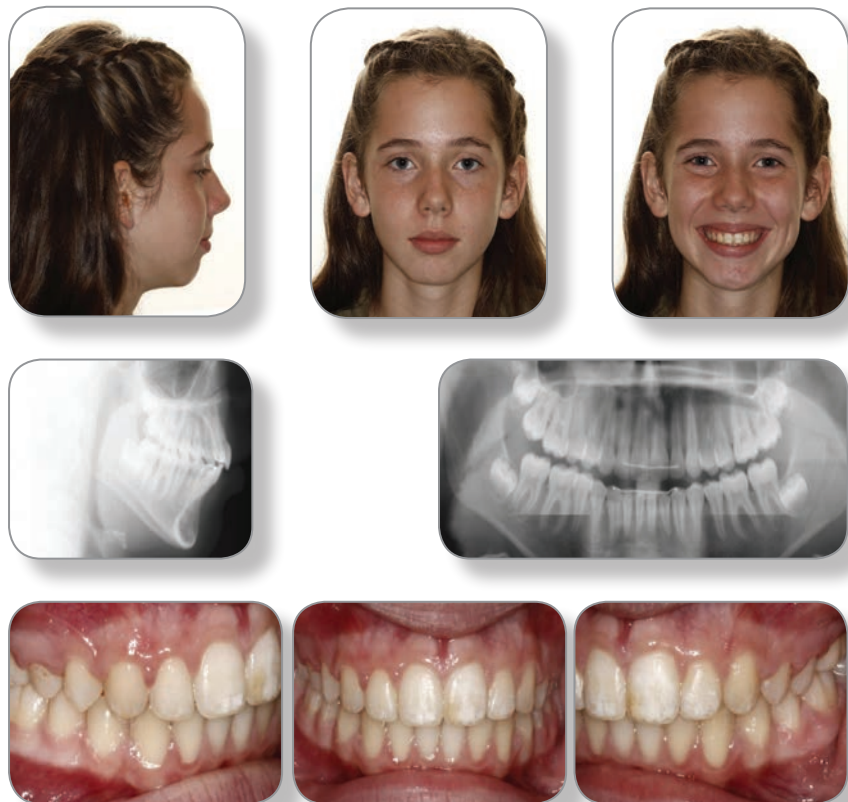- 2-9-2015 Initial visit/records.
- 3-2-2015 New start. Indirect bond lower 5-5 and upper 4-4. AdvanSync 2 crowns on 6's. Placed open-coil springs upper 2-4. Upper and Lower .014 Cu NiTi.
- 4-13-2015 Placed lower .014 x .025 Cu NiTi. Figure 8 laced lower 3-3. Activated upper open-coil springs on both sides. Maintained with .014 Cu NiTi on upper arch.
- 5-21-2015 Placed upper .014 x .025 Cu NiTi. Closed coil springs for all spaces and crimped tie back hooks to tie back upper arch and prevent molar distalization. In addition, figure 8 lacing 6-6 is placed in the maxillary arch to fully ensure no distalization of the molars occurs.
- 6-29-2015 Bonded UR3 with a high torque bracket. Placed lower .017 x .025 TMA with step down bends L 2-2 and 3-4. New upper archwire; .018 Cu NiTi. Maintain figure 8 lacing to prevent distalizing of upper arch. Placed AdvanSync 2 arms.
- 9-14-2015 New upper .014 x .025 Cu NiTi. Maintain figure 8 lace upper arch to prevent distalization. Activated 4mm on both sides with AdvanSync 2 arms.
- 10-17-2015 Activated 4mm both sides and placed upper .019 x .025 NiTi with 20 degree labial crown torque pre torque wire.
- 11-16-2015 Activated arms by moving upper screw of AdvanSync 2 arms to mesial hole in upper crown. Final overcorrected position.
- 2-8-2016 Progress Tomo - looks good; condyle in fossa. Ready for AdvanSync 2 removal.
- 2-15-2016 Remove AdvanSync appliance and sectioned archwires upper and lower 5-5.
- 2-22-2016 Pan and rebond after AdvanSync 2 removal. Bonded lower 6's and 7's, upper 6's, UL 3 and UR 5. Repositioned 4's shorter and L3's mesially rotated. Placed .018 U & L.
- 4-4-2016 Re-laced upper arch 6-6 and lower 3-3. Placed upper .018 x .025 Cu NiTi and Lower .014 x .025 Cu NiTi.
- 6-6-2016 Placed U .019 x .025 Stainless Steel Wire and L .014 x .025 Stainless Steel.
- 7-28-2016 Placed L .017 x .025 TMA with minor detail bends. Class II elastics were started at night time only.
- 8-29-2016 Placed U .019 x .025 Stainless Steel wire. The lower .017 x .025 TMA wire was sectioned 3-3.
- 9-12-2016 Impressions for lingual bonded retainers. Ostrich elastics night-time only.
- 9-26-2016 Bracket removal. Placement of upper and lower lingual bonded retainers. Final records; Ceph, panorex and photos. Deliver suck down clear retainers.

## Case Discussion

This case is an example of one that needs to have some mandibular arch leveling prior to attaching the AdvanSync 2 arms to the crowns. In a case like this, there is not adequate overjet to allow advancing the mandible to an ideal Class I molar/canine relationship. If advanced to Class I (as the arms will automatically do when hooked to the crowns due to the pre-fabricated length of the arms and the predetermined positions of the axles on the crowns), the incisors will be in an edge to edge position, propping the posterior occlusion open. In this position, the arms will orient themselves into a more vertical position, leading to molar intrusion and no advancement of the mandible over time. We begin treatment by placing the crowns on the molars to act as posterior buildups. This allow us to place all brackets in both arches from second premolar to second premolar.

In the maxillary arch, high torque brackets are placed on the incisors as the AdvanSync appliance will tend to upright or lingually incline the maxillary incisors. We also used high torque brackets on the maxillary canines as their pretreatment position had more lingual inclination than we want. In the mandibular arch the -11 degree torque brackets are used to offset the labial force placed on them from Class II mechanics. In this case, we had brackets on the canines as well which were high torque to upright them. Initial .014 Cu NiTi wires were placed with open coil spring from the maxillary laterals to first premolars, bypassing the canines. The springs were used to create space for the canines. At this point, the upper arch is not figure 8 laced together, allowing the arch to develop and the incisors to properly torque. The mandibular wire is annealed and bent over behind the archwire tube on the crowns.

Six weeks into treatment, a .014 x .025 Cu NiTi was placed in the lower arch. This is slightly faster than our normal wire change sequence, but the goal is to level the lower arch quickly to allow the arms to be hooked up as early as possible. The mandibular wire is annealed and bent over behind the archwire tube on the crowns.





## Case Discussion (Cont)

At just shy of 4 months, a .014 x .025 wire is placed in the upper arch. The entire maxillary arch has an .010 ligature wire placed to figure 8 lace the arch together from first molar to first molar. This prevents the maxillary molars from distalizing when the AdvanSync arms are attached, allowing all movement to occur in the mandible. In addition, a crimpable hook is placed on the wire between the Advansync crown and the brackets on the second premolars. A tie back ligature is placed. This additional tie back is done to ensure no molar distalizing occurs. In the mandibular arch, a .017 x .025 TMA wire is placed with some vertical bends. We put in step down bends between the laterals and canines and between the canines and first premolars. We call this a step down wire. It helps to intrude the anterior teeth, leveling the curve of spee. At this time, the AdvanSync arms were also placed as enough leveling had occurred to allow advancement of the mandible into Class I without premature contact on the incisors.

Over the next 6 months, the AdvanSync was activated, moving into a Class III overcorrected position and held overcorrected for 12 weeks. At that time, radiographs of the temporomandibular joints are taken to ensure that the condyle is centered in the glenoid fossa prior to removing the appliance. If an office is unable to take joint films, we recommend holding the overcorrection for 4.5 months prior to removing the appliance.

Upon removal of the AdvanSync 2 appliance, the posterior teeth are bonded and any teeth requiring repositions is done. From that point forward, normal orthodontic mechanics, archwire sequencing, etc. are done to finish the case. Most overcorrected mandibles will take 6 - 12 weeks to relapse back into a Class I position.

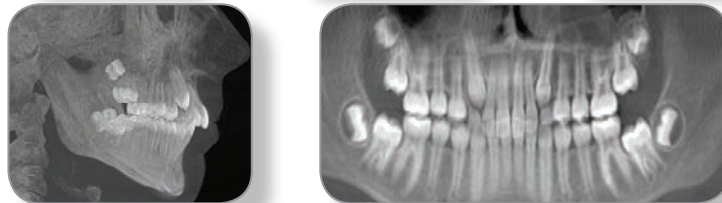
The AdvanSync was in place without the arms attached for 4 months, and with the arms attached for another 9 months. Following removal of the AdvanSync an additional 7 months of orthodontics was performed, completing full treatment in 20 months.

Our treatment goals were achieved with a very nice Class I occlusion, broadened arches and ideal smile. The profile was greatly improved. Total treatment of 20 months was very efficient.

## Dr. Stanley Robison, Frederick, MD

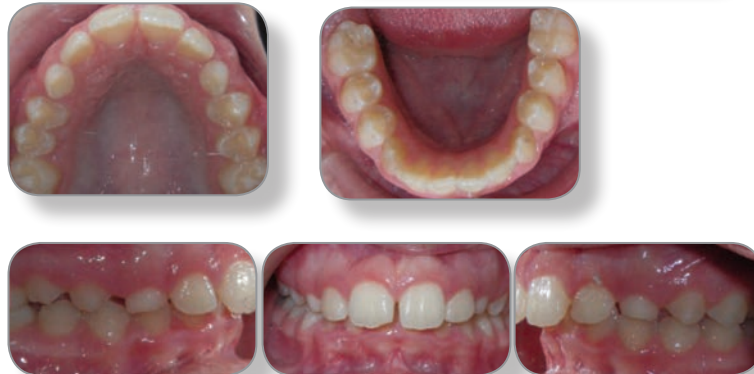### Pretreatment Diagnosis

Class II, Division I malocclusion  
 Occlusal cant to the right  
 Severe overjet  
 Severe overbite  
 Mild upper and lower crowding  
 Upper primary canines are overretained

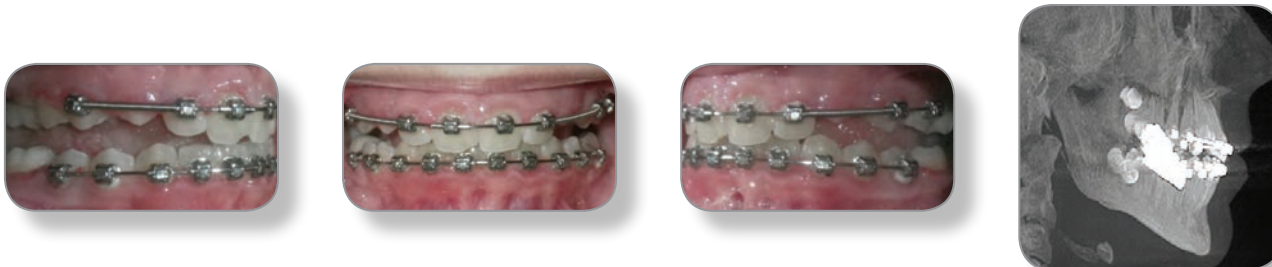

### Treatment Objectives & Plan

- Comprehensive Treatment
- Estimated treatment time 30 months
- Attempt non-extraction therapy
- Full upper and lower Damon braces
- AdvanSync 2 Herbst™ Appliance
- Upper and lower lingual bonded retainers and Damon splint
- Achieve Class 1 by Mandibular repositioning and reciprocal movements
- Reduce overjet by advancing mandible
- Reduce overbite by intruding upper and lower incisors and leveling arches
- Resolve crowding by arch development

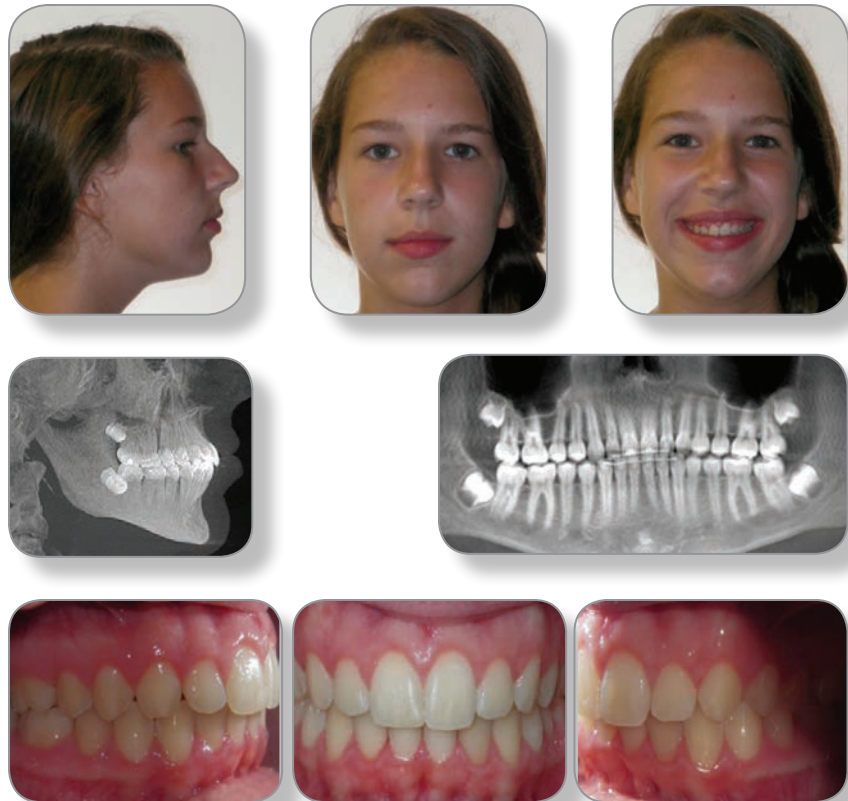

### Progression



## Treatment Time - 26 Months

- 5-14-2013 Placed brackets Upper and Lower 5-5 (less U3's). Fit bands on Upper and Lower first molars. .014 Cu NiTi wires placed. OCS placed in U3 spaces.
- 7-30-2013 Advanced Upper and Lower AW's to .014 x .025 Cu NiTi wires.
- 9-23-2013 Advanced Upper and Lower AW's to .018 x .025 Cu NiTi wires.
- 10-31-2013 Advanced Upper and Lower AW's to .019 x .025 Stainless Steel Wires. Replaced OCS's with CCS's. Laced upper arch. Delivered Herbst arms and activated 2 mm on both sides.
- 12-19-2013 Advanced arms 4 mm on both sides.
- 2-26-2014 Evaluated patient to advance arms. Soft tissue impingement and patient discomfort prevented advancement. Removed 4 mm on left arm, placed screw into the anterior hole on the upper left band to compensate.
- 4-29-2014 Took iCAT scan to confirm centralized condylar position. Removed AdvanSync 2 appliance on both sites. Clipped Upper and Lower archwires distal to second premolars. Bonded Upper and Lower 6's and 7's.
- 5-15-2014 Placed .014 Cu NiTi on upper and lower arches.
- 8-7-2014 Bonded erupted upper canines. Replaced .014 Cu NiTi.
- 9-18-2014 Advanced Upper and Lower AW's to .014 x .025 Cu NiTi.
- 10-16-2014 Advanced Upper and Lower AW's to .018 x .025 Cu NiTi.
- 11-20-2014 Advanced Upper AW to .019 x .025 TMA and Lower AW to .017 x .025 TMA. Begin full-time Class II Elastics (Moose) on both sides.
- 1-8-2015 Detailing, continue full-time Class II Elastics.
- 3-12-2015 Detailing, continue full-time Class II Elastics.
- 4-9-2015 Detailing, continue full-time Class II Elastics.
- 5-14-2015 Detailing, continue full-time Class II Elastics.
- 6-15-2015 Detailing, Evaluate for deband and discuss retention plan.
- 7-1-2015 Debond Upper and Lower arches. Placed upper and lower lingually bonded retainers. Impression for Damon splint.
- 8-18-2015 Delivered Damon splint.



## Case Discussion

The Damon System was used in conjunction with the AdvanSync 2 molar to molar Herbst appliance to correct this Class II malocclusion. High torque brackets were used on the upper incisors and the upper and lower canines. Low torque brackets were used on the lower incisors. 3/4 crowns were used for the appliance and full bonding upper and lower 5-5 except for the unerupted U3's. Initial leveling and aligning were accomplished with .014 Cu NiTi, .014 x .025 Cu NiTi, and .018 x .025 Cu NiTi wires while space was made to facilitate the eruption of the U3's. I use the .018 x .025 Cu NiTi wire as a "transition" wire so that it facilitates the insertion of the Stainless Steel wires. When the Stainless steel wires were delivered, the open coil springs, which were used to create U3 spaces, were replaced with closed coil springs to hold the spaces and the Herbst appliance was activated by insertion of the arms. The upper arch was laced.

Note that I did not deliver the Herbst arms until the patient was in stainless steel wires. In my hands, I feel I get better results when I treat a Herbst case similarly to how I treat a surgical case. I level and align, advance to stainless steel wires and then I deliver the Herbst arms (analogous to surgery). Following Herbst removal, I do the finishing and detailing the same way I would do after surgery is complete.

For this patient, I was not able to overcorrect into a full Class III with anterior crossbite as is the ideal due to tissue impingement on the left side. To maintain the activation we had achieved, it was necessary to remove a 4mm spacer on the left side. To compensate for the loss in advancement, I placed the upper portion of the appliance into the anterior screw hole. Unfortunately doing so increases the vertical vector of force, but it is better than early removal of the appliance.



## Case Discussion (Cont)

After the final Herbst activation I wait a minimum of 3 months before evaluation for removal. I will go 6 months or more for an older teenager or an adult.

Before removal, a CBCT scan is taken and the joints are evaluated to ensure equal joint space surrounding the condyle. If the condyle is positioned forward in the glenoid fossa, the Herbst is left in longer.

The progress photos for this patient were taken the day of Herbst removal. Note the bilateral posterior openbite. This side effect is something I see for all patients treated with AdvanSync 2 due to the vertical force vectors inherent in a short Herbst design such as this. However, the posterior openbites close very quickly after Herbst removal. Also, note that the patient immediately relapsed from edge to edge incisal relationship (as seen in progress radiograph) to Class I with normal overjet. If this patient had been overcorrected to an anterior crossbite, according to the ideal, she would have relapsed back to an edge to edge position or remained in a slight anterior underbite. That underbite would have relapsed back into Class I within a week or two.

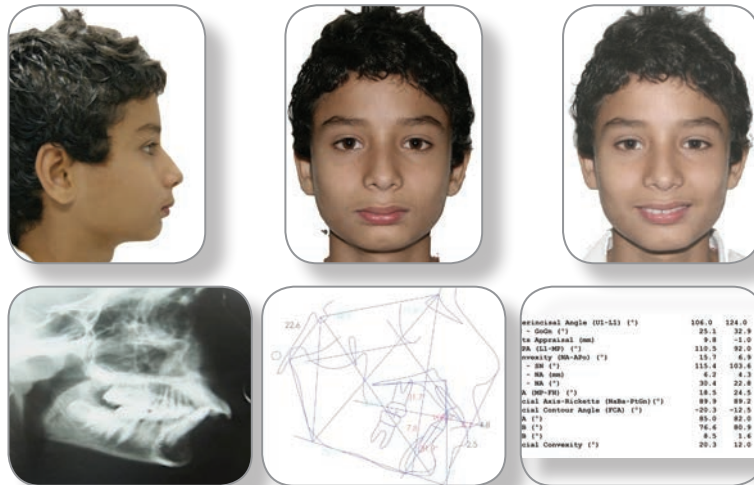
I had the patient continue with Class II elastics following Herbst removal to prevent Class II relapse.

I retained the patient with lingual bonded retainers and a Damon Splint.

Dr. Andres Perdomo, Bogota, Colombia

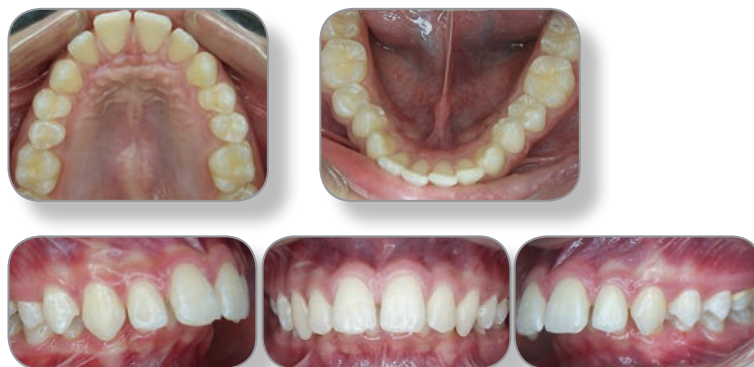## Pretreatment Diagnosis

Class II, Division I, Class II Skeletal relationship (ANB = 8.5 degree), short lower anterior facial height, convex profile, 100% overbite, deep mental labial fold, spacing at the upper jaw and mild crowding at the lower jaw.

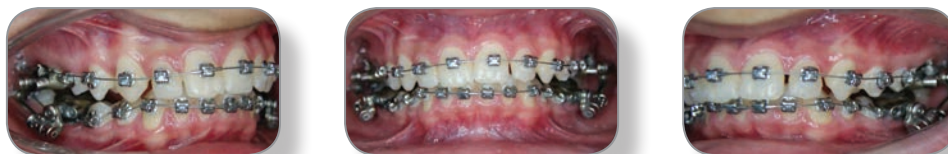

## Treatment Objectives & Plan

- Correct the Class II malocclusion (dental and skeletal)
- Correct convex profile
- Increase lower anterior facial height
- Eliminate deep mental labial fold
- Correct overbite
- Close upper spaces
- Eliminate lower incisor crowding



## Progression - 6 months



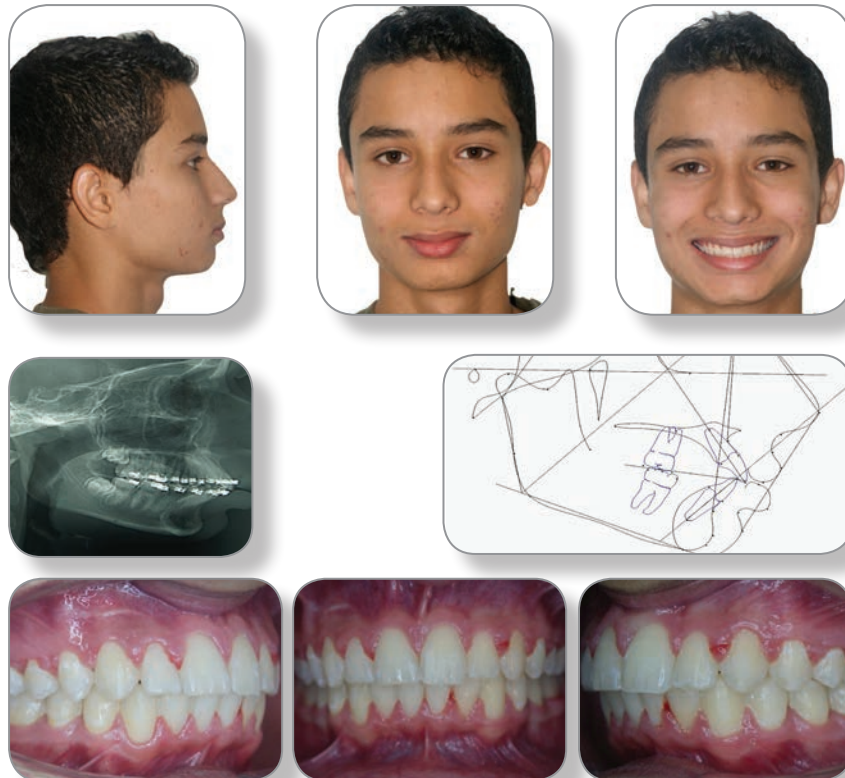
**PEARL:** "Key methods to avoid flaring of the lower incisors\*, the most common side effect of mandibular propulsion.

- Utilize low torque (-11°) on the lower incisors.
- .019 x .025 Cu NiTi 20° wire, place at the lower incisors creating an additional negative moment.
- Placement of TADS between lower premolars in combination with stainless steel ligatures from the TADS to the lower incisors to avoid proclination.
- You can use the Insigna system as well, which provides customized bracket prescription. With activation negative torque compensation on the lower incisors, you can achieve negative torques up to -13°."

Dr. Andres Felipe Perdomo

## Treatment Time - 18 Months

- 11-22-09 Placed brackets U 5-5, L 5-5. Cemented AdvanSync crowns on upper and lower 1st molars. Tighten AdvanSync on the crowns and activate until get a Class I cuspid relationship .014 Cu NiTi wires placed.
- 03-20-10 Activated AdvanSync 4mm both sides. New archwires upper and lower .018 Cu NiTi.
- 05-14-10 Stainless Steel ligature from U6 to U3 bilaterally, elastic chain from UR3 to UL3 below the archwire.
- 06-28-10 New archwires .014 x .025 Cu NiTi upper and lower. Additional activation of 4mm both sides.
- 08-17-10 New archwires .018 x .025 Cu NiTi at the upper and .016 x .025 Cu NiTi at the lower teeth. Last activation until get an anterior crossbite.
- 11-30-10 Tomo to check condyle position, the AdvanSync is removed. Bonding upper and lower 6's. Repo LL 4 and LL 5 and LR 4 and LR 5. Archwires upper .014 x .025 Cu NiTi and lower .014 x .025 Cu NiTi.
- 1-15-11 New archwires upper .018 x .025 Cu NiTi and Lower .018 Cu NiTi Figure 8 lace upper Class II elastics 1/4 3.5 oz.
- 3-15-11 Upper .017 x .025 TMA and Lower .016 x .025 Cu NiTi.
- 5-20-11 Upper .019 x .025 TMA and Lower .016 x .025 Stainless Steel. Finishing elastics.
- 5-24-11 Debond. Placed bonded lingual retainers 3 x 3. Removed all brackets. Took alginate impressions for upper Essix retainer. Delivered Essix retainer. Took final x-rays and photos.



## Case Discussion

Angel was 14 years old when his parents brought him to my office. He had visited many Orthodontists and most of them proposed a similar treatment plan: Orthognathic surgery. Other Orthodontists offered him the option of upper premolar extractions plus screws at the upper jaw to intrude and retract the upper teeth simultaneously. Angel and his parents turned down surgery and extractions and chose AdvanSync 2 and Damon Q braces as a treatment option.

I started Angel's treatment with Damon Q braces, high torque at the upper incisors and low torque at the lower incisors, this torque prescription was chosen to avoid unwanted moments created by the AdvanSync and its mandibular propulsion. In this case, although he had an overjet of about 12 mm, I was pretty sure that the treatment would be successful, because I took advantage of his age. Angel was in his peak of pubertal growth and for me this is the best time to start Class II treatments. After placing the AdvanSync and braces, the goal in the first activation is to get a Class I cuspid relationship, in this case it was useful to place spacers in this first step because of Angel's initial overjet (12mm). Three months later the subsequent activation was of about 4 mm on both sides, and the next activations were similar until I got an anterior cross bite. Due to Angel's initial discrepancy spacers weren't enough to achieve an anterior crossbite, so I had to change the position of the AdvanSync screws to the distal casing on the lower crown. In this case I used AdvanSync 1 and this appliance didn't have mesial casing in its upper crown which was corrected in the AdvanSync 2 appliance. The most common side effect with AdvanSync is the flaring at the lower incisors and we have a lot of options to avoid this problem. My preferred one is the .017 x .025 and .019 x .025 pre torqued (20 degree) Cu NiTi wires, obviously we need to take advantage of the lower incisor prescription (-11 degree) but most of the time this prescription isn't enough to control the lower incisor position.

As Dr. Dischinger teaches; it is mandatory to place a figure 8 laceback from UR6 to UL6 to enhance the orthopedic effect created by AdvanSync and ensure more skeletal change than a dental one. In the case of Angel, I had to put on elastic chains at the upper teeth because I needed to close the spaces at the upper jaw, after that, I placed a figure 8 lace stainless steel ligature.

After 11 months of treatment, I removed the AdvanSync, when Angel achieved an anterior crossbite and maintained this position for about 3 or 4 months. It's advisable to take CBCT's to check the condyle position before you take off the appliance. After removing the AdvanSync, most of the time we must go back to round wires, to align and level, at this stage my advice to bond the lower premolars as gingival as possible to level the lower arch and close the posterior open bites, created by the appliance as soon as possible.

Treatment time takes 18 months, sometimes at the final stages I prescribe Class II elastics, although, I prefer, if it's possible, to avoid any procedure that involves patient's cooperation, for this purpose the overcorrection is essential. My retention protocol is lower fixed 3 x 3 retainer and an Essix retainer at the upper jaw. Sometimes (as with Angel's case) due to the big discrepancies, I prescribe an orthopedic device (FRII appliance) to be worn at night, to maintain the edge to edge position for about 12 months.



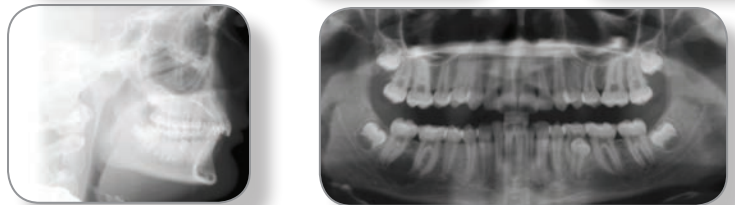# Brachycephalic

Drs. Terry and Bill Dischinger, Lake Oswego, OR.

Treated with AdvanSync 2 Hybrid Appliance

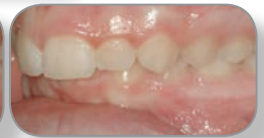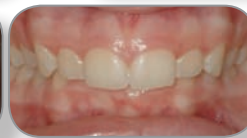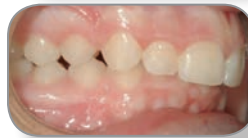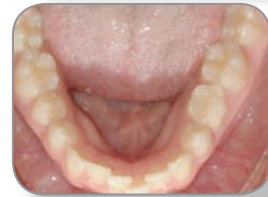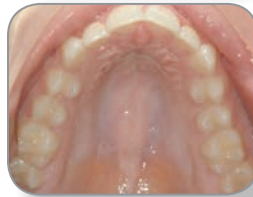## Pretreatment Diagnosis

Class II, Div II, with low mandibular plane angle, short lower facial height, a mandibular asymmetry, 100% overbite, deep mental labial fold, moderate mandibular crowding, and narrow arches.



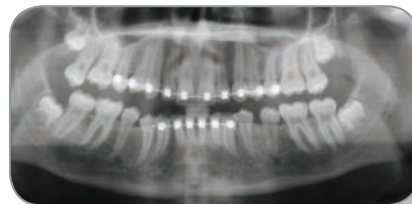
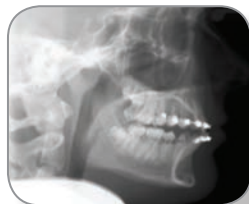## Treatment Objectives & Plan

- Correct the Class II malocclusion
- Correct overbite
- Correct asymmetry
- Eliminate deep mental labial fold
- Increase lower facial height
- Eliminate lower incisor crowding
- Reshape maxillary and mandibular arches



## Progression

Images 11 month progression.



**PEARL:** "AdvanSync, beautiful smiles and wonderful faces!"

Dr. Terry Dischinger

## Treatment Time - 20 Months

- 2-1-10 Placed brackets U 5-5, L 2-2. Cemented Brachy AdvanSync crowns on maxillary first molars and mandibular first premolars. Maxillary arch was figure 8 laced 6-6. .014 Cu NiTi wires placed.
- 3-29-10 Activated open-coil springs.
- 5-19-10 U .014 x .025 Cu NiTi. Closed coil springs for all spaces and crimped tie back hooks to tie back upper arch and prevent molar distalization. Also figure 8 lace. Sometimes lacing breaks or sometimes the hook comes loose. L .014 x .025 overlay activated AdvanSync 4 mm.
- 7-15-10 All brackets on wire lower arch .018 Cu NiTi.
- 9-22-10 New archwires U .016 x .025 pre-torqued Cu NiTi, L .014 x .025 Cu NiTi.
- 12-8-10 New archwires L .016 x .025 SS activated 4 mm both sides.
- 2-22-11 Tomo to check if condyle is centered in fossa. Ready to remove AdvanSync.
- 2-25-11 Removed AdvanSync, sectionalized archwires, ceph and pan.
- 3-5-11 Bonding U & L 6's & 7's, L 3's, 4's and 5's. Rebond L1's shorter, UR2 longer. U .018 Cu NiTi. L.014 Cu NiTi. Laced L 3-3.
- 5-4-11 U & L .014 x .025 Cu NiTi. Figure 8 lace U & L. Start box elastics U 3, 4, 5 to L 3, 4, 5.
- 7-9-11 U .019 x .025 TMA. L .016 x .025 SS.
- 10-3-11 Finishing elastics, retainer consult. Laced U & L 3-3, sectioned mandibular wire 3-3. Finishing elastics full time.
- 10-17-11 Check finishing elastics. Wear finishing elastics night only. Impressions for bonded lingual retainers.
- 10-24-11 Deband. Placed bonded lingual retainers. Removed all brackets. Took alginate impressions for full cover retainers. Delivered full cover retainers. Took final x-rays and photos.

## Case Discussion

The Brachycephalic appliance is designed to correct the problems found in the pretreatment diagnosis. When making the appliance, we make the lower cantilever as short as possible which minimizes breakage. To do this, we attach the arm to the mesial axle in the upper, moving the arm more forward, allowing the cantilever to be shorter. That is the difference in how the arms are attached in this version. In particular, this appliance is very good at correcting a Class II with a deep mental labial fold, improving that aspect of the profile. The maxillary design is the same as a typical AdvanSync case other than the arms being attached to the mesial axle. Damon System brackets are used simultaneously with the appliance. In the maxillary arch, high torque brackets are placed on the incisors as the AdvanSync appliance will tend to upright or lingually incline the maxillary incisors. We also used high torque brackets on the maxillary canines as the pretreatment position had more lingual inclination than we want. In the mandibular arch, brackets are typically only placed on the incisors with this brachycephalic design. The -11 degree torque brackets are used to offset the labial force placed on them from Class II mechanics. In this case, we had brackets on the canines as well which were high torque to upright them. Since finishing this case, we have discontinued placing brackets on the mandibular canines as we have found intrusion of the incisors to level the curve of spee occurs faster with the brackets left off on the canines.

## Case Discussion (Cont)

The initial wires placed were .014 Cu NiTi. We placed medium light NiTi open coil springs for the blocked out mandibular incisors. We activate the springs one half width of a bracket longer than the interbracket distance. These open coil springs are activated every 6 weeks until adequate space is made for the blocked out teeth. The mandibular wire is annealed and bent over behind the arch wire tube on the crowns. In the maxillary arch, the entire arch has an .010 ligature wire placed to figure 8 lace the arch together from first molar to first molar. This prevents the maxillary molars from distalizing, allowing all movement to occur in the mandible.

At the 6 week appointment, the open coil springs were removed and the .014 Cu NiTi was engaged in the mandibular incisors. The AdvanSync 2 appliance is not activated at this 6 week appointment.

After 3 months, the .014 Cu NiTi wires were replaced with .014 x .025 Cu NiTi wires in both arches. The figure 8 lacing is maintained. In addition, a crimpable hook is placed on the wire between the AdvanSync crown and the brackets on the second premolars. A tie back ligature is placed. This additional tie back is done to ensure no molar distalizing occurs. The mandibular wire is again annealed and bent over behind the archwire tube on the crowns. The AdvanSync appliance is activated 4mm on both sides to begin working towards overcorrecting the Class II.

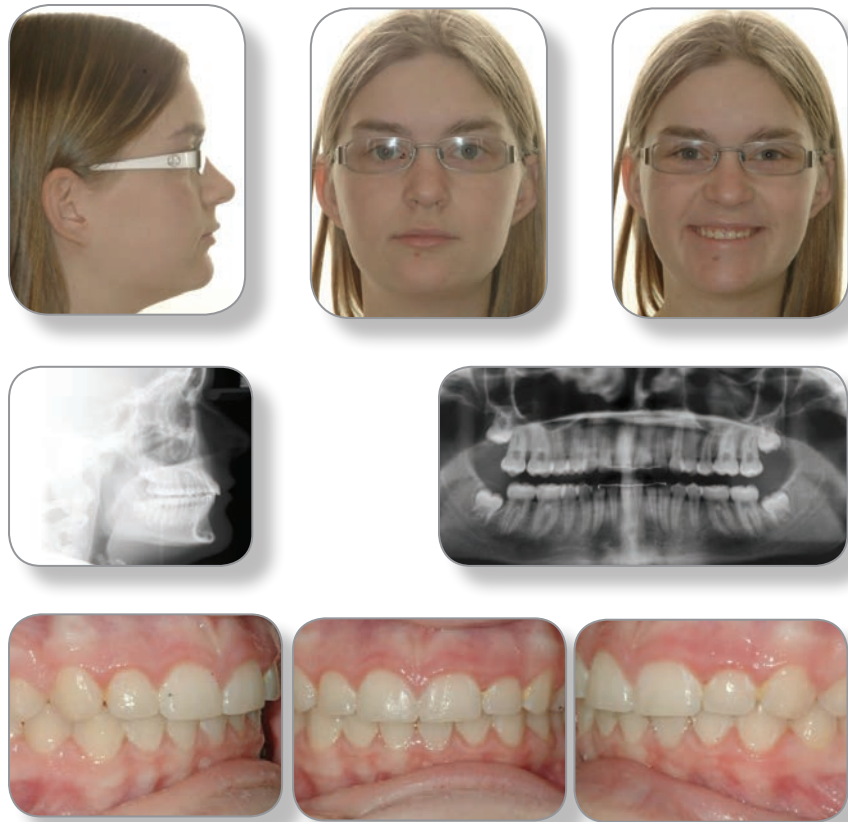
At six months, a .019 x .025 NiTi with 20 degrees of labial crown torque is placed in the maxillary arch. The figure 8 lacing is maintained. It is again tied back to the molars with a crimpable hook and ligature tie. The pre-torque wire is placed because the continued Class II force of the AdvanSync appliances places more lingual crown torque movement on the maxillary incisors. A .016 x .025 stainless steel wire is placed in the mandibular arch. The appliance is again activated, moving further into overcorrection.

The goal of the wire sequence is to level and coordinate both arches. If the mandibular arch is not leveled, it is not possible to overcorrect the mandible as the incisors will interfere with premature contact. Once the appliance is removed, if the arches have been properly leveled and coordinated, the finishing of the case is quite easy and can occur quickly.

The overcorrection of the Class II is held for 3 months. After that time, radiographs of the temporomandibular joints are taken to ensure that the condyle is centered in the glenoid fossa prior to removing the appliance. If an office is unable to take joint films, we recommend holding the overcorrection for 4.5 months prior to removing the appliance.

Upon removal of the AdvanSync 2 appliance, the posterior teeth are bonded and any teeth requiring repositions is done. From that point forward, normal orthodontic mechanics, arch wire sequencing, etc. are done to finish the case. Most overcorrected mandibles will take 6-12 weeks to relapse back into a Class I position.

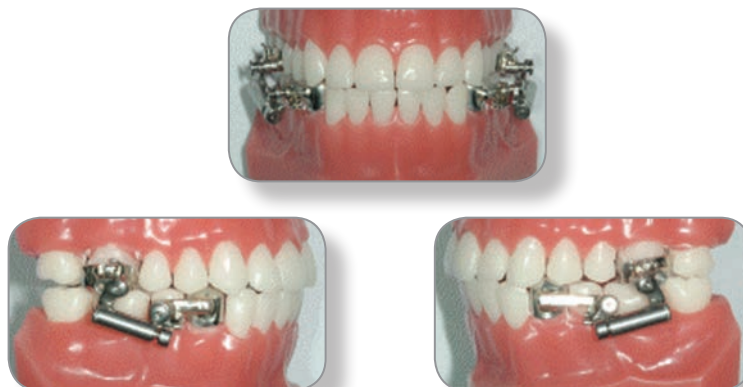The case presented here had the Brachycephalic AdvanSync 2 appliance in place for just over 12 months. Upon removal, braces were worn for an additional 8 months for a total of 20 months of treatment.



## AdvanSync 2 Hybrid Appliance

Dr. Pancherz in his revival of the Herbst appliance had pinched bands for the appliance with the bands on the upper 1st molar and on the lower 1st bicuspids. He found that a part of the Class II correction was from movement of the lower teeth forward. That movement was what I wanted with the low mandibular plane angle and deep mental labial fold.

The Brachy AdvanSync allowed us to correct the Class II, eliminate the mental labial fold and achieve a normal profile. We were also able to correct midline, overbite and increase the lower facial height. We were also able to eliminate lower crowding and attain broad arches and smile. We feel the Brachy appliance is the BEST treatment available for this type of malocclusion.





# Ormco<sup>™</sup> | AOA

13931 Spring Street  
Sturtevant, WI 53177  
(P) 800.262.5221  
(F) 262.886.6879  
[www.aolab.com](http://www.aolab.com)  
[www.aoaaccess.com](http://www.aoaaccess.com)