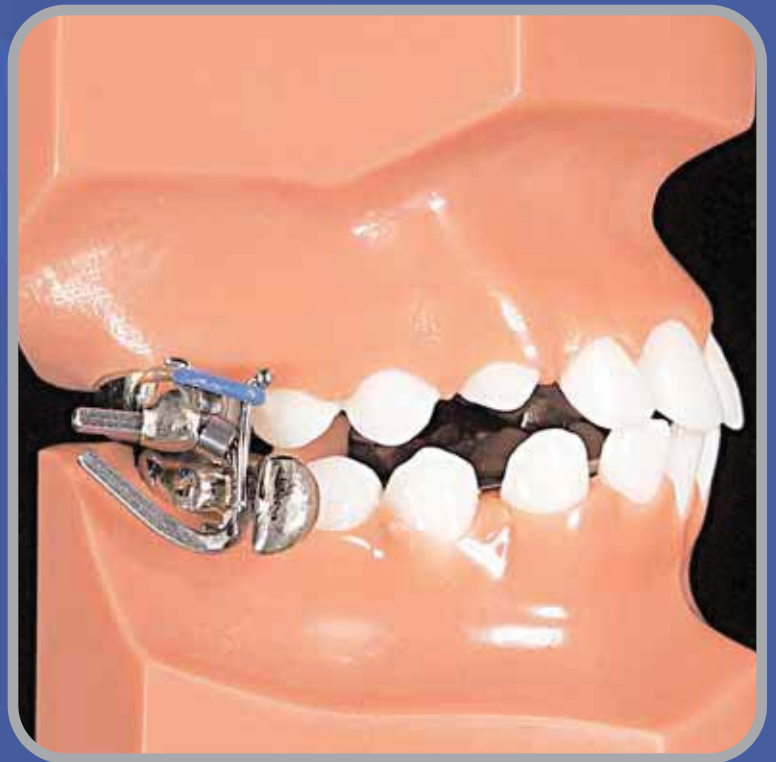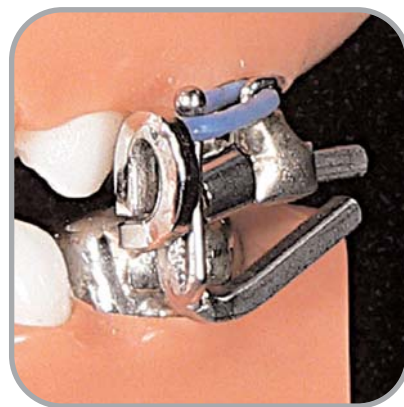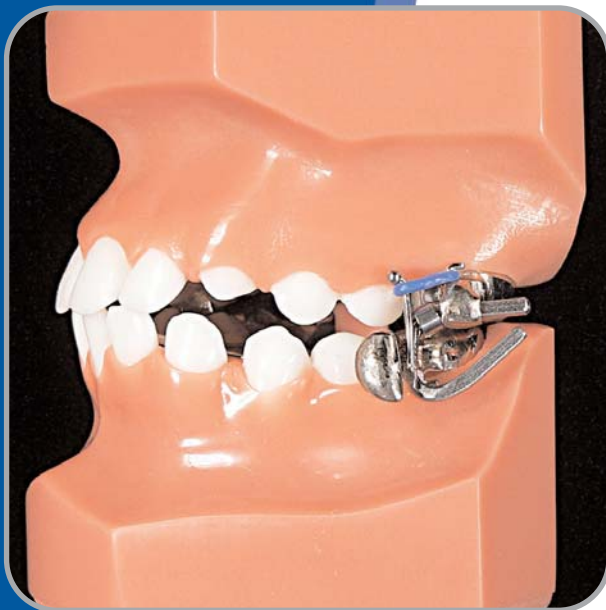


# Clinical Management of MARA





# Clinical Management of The MARA



**A Manual for Orthodontists and Staff**

Authored by Paula S. Allen-Noble  
in Partnership with Allesee Orthodontic Appliances  
AOA is a subsidiary of Ormco Corporation

## **Forward**

This manual has been written by Paula S. Allen-Noble in partnership with Allesee Orthodontic Appliances. It is a compilation of clinical protocol for the Mandibular Anterior Repositioning Appliance (MARA) currently being implemented by orthodontists and clinical staff who have successfully integrated the appliance into their practice.

The intent of the author is to share information concerning clinical management of the appliance, not dictate procedure or associated treatment mechanics. This manual has been created as a continuous “work in progress” and is dedicated to keeping the orthodontic practice as current as possible concerning clinical techniques and appliance design. Graphic illustrations have been dated and are reviewed before each reprint to reflect changes and modifications.

## **Acknowledgements**

Special acknowledgement of gratitude is given to Dr. Jim Eckhart for his endless and significant contributions to this project, for which I am most appreciative; as well as to the many orthodontic practices who, along with the dedicated AOA technicians and technical support personnel, in particular John Fuller and Gerald Engelbart, have participated in the research, continuing development and evolution of the MARA. David Allesee and Max Hall are commended for their continued support of this project. Without these colleague’s vision and desire for achieving excellence in serving the orthodontic community this manual would never of had the opportunity to be written as a “work in progress.”

Paula S. Allen-Noble  
In partnership with Allesee Orthodontic Appliances  
*July 2005*

# **Clinical Management of the MARA**

## **(Mandibular Anterior Repositioning Appliance)**

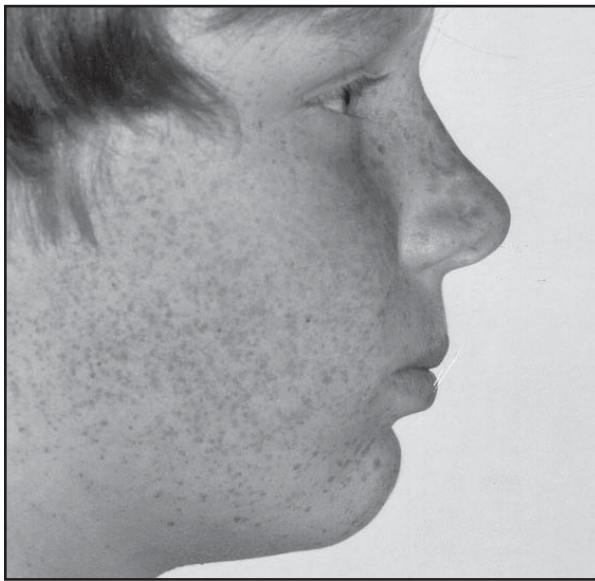### **Contents**

<b>Introduction of the MARA</b>	<b>1</b>
<b>Evolution and Overview of Current MARA Designs</b>	<b>4</b>
Current MARA Designs, Terminology and Accessories	<b>9</b>
MARA Accessories & Treatment Enhancements	<b>13</b>
<b>Prior to Fabrication: Preparation for the MARA</b>	<b>14</b>
Diagnostic Records and Impressions for Work Models	<b>14</b>
Bite Registration and Placing Separators	<b>15</b>
Requirements that Effect MARA Placement	<b>16</b>
Work Models for Appliance Fabrication	<b>17</b>
Crowns or Bands Furnished and Placed Indirect by Laboratory Tech	<b>17</b>
Sending models to lab and e-mara	<b>18</b>
e-MARA	<b>19</b>
Crowns or Bands Furnished and Fit Direct by Clinician or Clinical Staff	<b>21</b>
<b>Delivery of the MARA</b>	<b>24</b>
Pre-Insertion Check List	<b>24</b>
Clinical Insertion	<b>25</b>
Preparation and Cementation of MARA	<b>30</b>
Inserting MARA Elbows	<b>33</b>
Post-Insertion Bite Functioning Check List and Adjustments	<b>33</b>
Post-Insertion Instructions to Patient/Parent	<b>35</b>
<b>Expander MARA: Clinical Considerations</b>	<b>37</b>
Clinical Delivery	<b>37</b>
Post-Insertion Instructions	<b>37</b>
Completion of Expansion and Continuation of MARA Therapy	<b>38</b>
<b>Treatment Sequence and MARA Activation</b>	<b>39</b>
Activating or Advancing the MARA	<b>41</b>
Determining When to Remove the MARA	<b>42</b>
<b>Removal of the MARA</b>	<b>43</b>
Crown Removal Cutting Technique	<b>44</b>
Crown Removing Plier Technique	<b>45</b>
Crown Slitter Plier Technique	<b>46</b>
Cement Removal	<b>47</b>
<b>Continuation of Orthodontic Treatment</b>	<b>48</b>
<b>Appendix</b>	
Supply List for MARA Treatment	<b>49</b>
Suggested Reading List	<b>50</b>
Common Questions and Troubleshooting the MARA	<b>51</b>

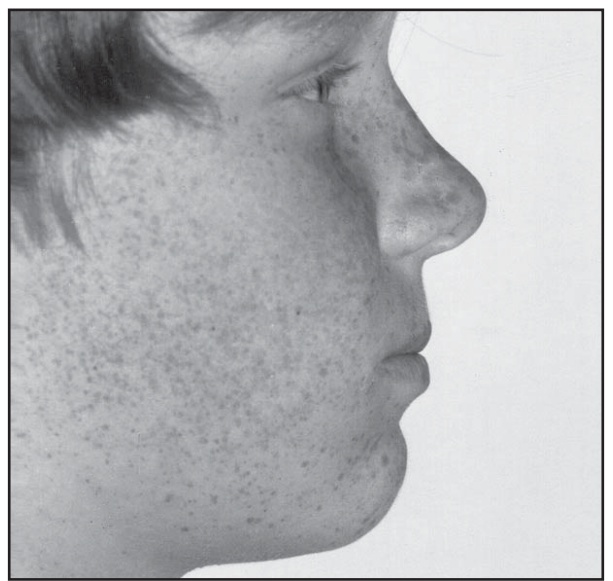
## Introduction of the MARA

A common problem presented to the orthodontist is correction of skeletal Class II malocclusions. In the past, most Class II malocclusions have been corrected with surgical procedures, headgear and/or elastic therapy.

In most cases, the improper bite is caused by a lower jaw that is too far back in relationship to the rest of the face. A good indicator of this type of malocclusion would be a case where the upper lip is balanced with the rest of the face by sliding the lower jaw forward, thus creating a more pleasing profile.



**Patient with typical Class II profile.**

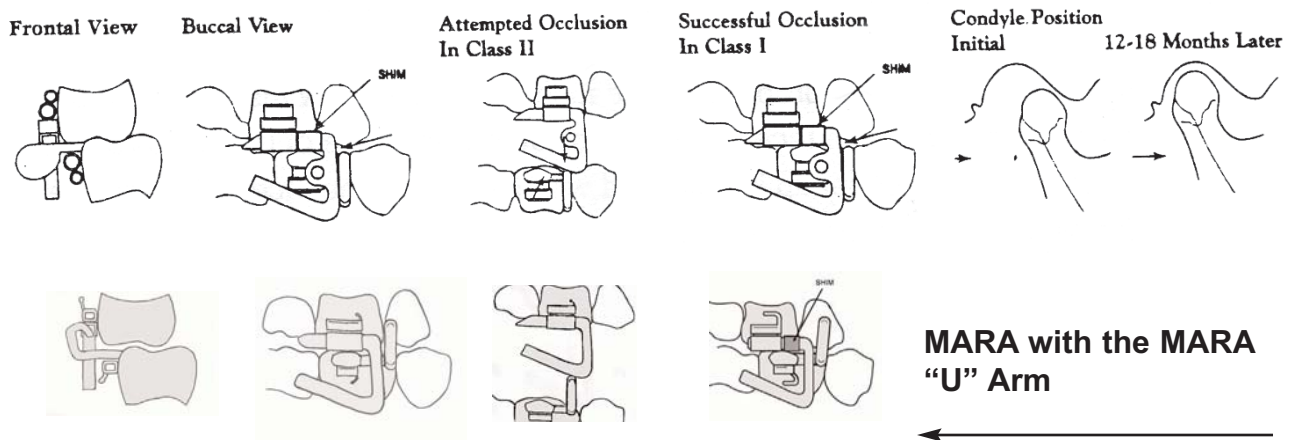


**Patient with lower jaw positioned forward and edge-to-edge.**

When the patient is still growing, it is possible to accelerate the growth of the lower jaw to catch up with the upper part of the face by using the MARA. The MARA is a functional appliance because it postures the patient's lower jaw in a forward direction. Over a period of months this forward posture of the lower jaw usually promotes growth in the same direction.

Because MARA's are permanently attached to the teeth for the duration of treatment, they address the lack of success that removable functional appliances have experienced in the past due to patient noncompliance. When the patient tries to bite in Class II, the fixed lower arms interfere with closing, allowing them to only close in Class I. The patient is forced to bite forward in front of the upper (elbow) and is guided by the appliance to habitually hold the jaw in a Class I relationship. Opening and closing movements occur easily and patients adjust to the appliance in a week or less.

### How the MARA works: MARA with a Standard Arm

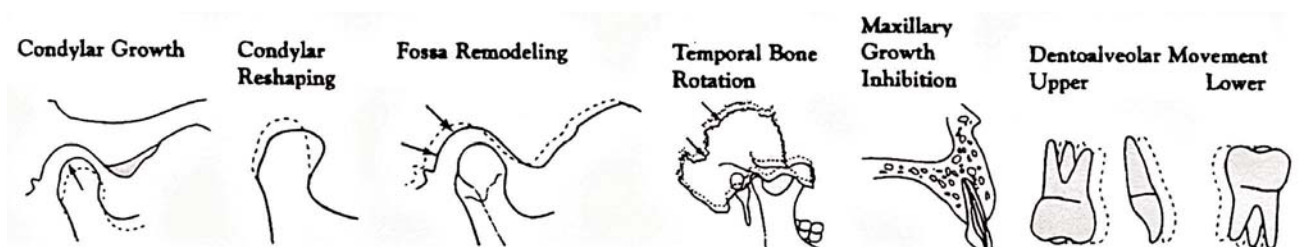


MARA's work well with all different types of dental and skeletal Class II problems, especially brachyfacial (low angle) deepbite Class II cases. However, cases with extremely short rami may not grow sufficiently, and high-angle cases may get more vertical face height increase as the Class II is corrected, unless some steps are taken to prevent it such as wearing a cervical collar at night.

It is a little more difficult appliance to use in the early mixed dentition because there is insufficient room in the cheek area, although many successful Class II treatments have been reported utilizing the primary second molars as anchorage. The appliance is mostly used in the late mixed dentition stage of development all the way through advanced adulthood. Adults are apparently capable of remodeling of the fossa and reshaping of the condyle, as well as significant dentoalveolar remodeling.

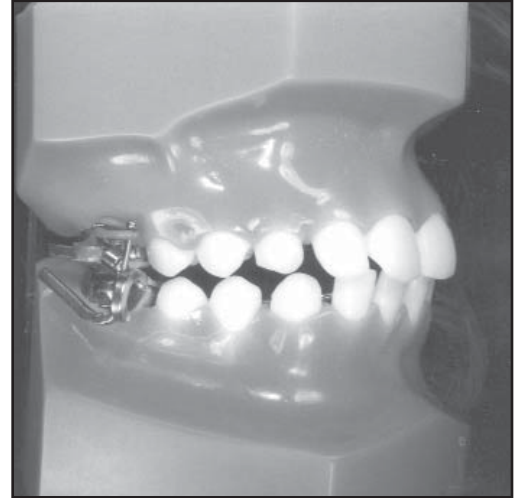
It is reported that the appliance produces remodeling similar to what the Herbst sometimes shows, except it has less vertical effect on the teeth: lower teeth move forward a little, upper teeth move backward a little, mandible (condyle) grows forward a little, maxilla growth is slightly restrained, glenoid fossa may remodel forward, and the temporal bone may rotate forward.

### Changes the MARA produces:

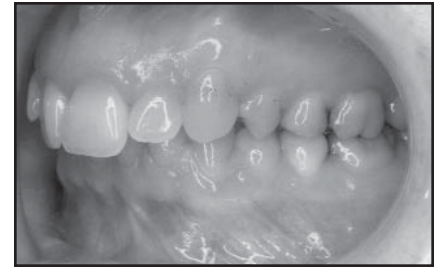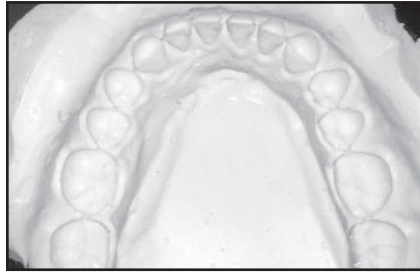

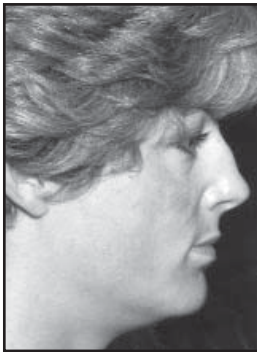
## Indications for MARA Treatment:

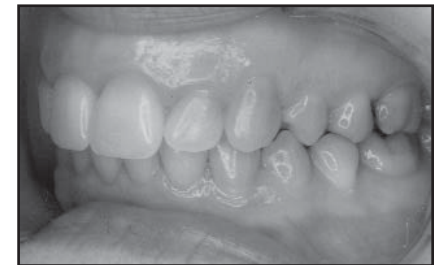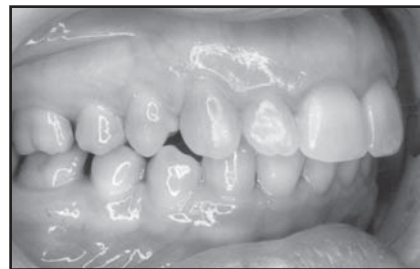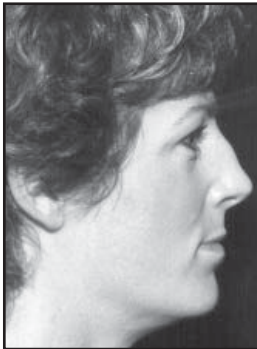1. The upper jaw is in good position and you want to advance the mandible (children).
2. It is desirable to inhibit maxillary anterior growth and produce an increase in mandibular length.
3. You want to recapture a prolapsed disc.
4. Adult cases, when lower jaw surgery is not an option, needing a good compromise Class II correction. While the result is mostly dental, some mesial migration of the fossa may occur.



## Adult Pre-treatment



## Adult Post Treatment

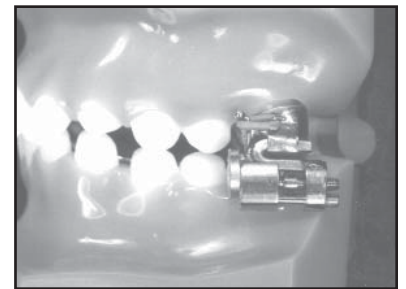
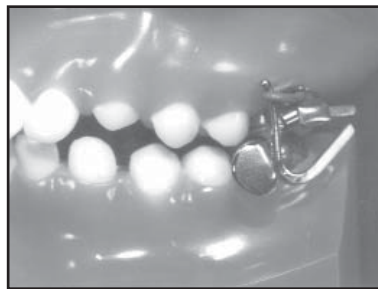
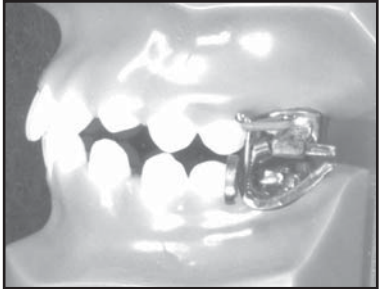


# Evolution and Overview of Current MARA Designs

Having utilized removable functional appliance therapy in the 70s and 80s, Dr. Jim Eckhart, Manhattan Beach, California, knew they worked but began searching for a way to avoid lost and broken appliances, which were expensive for parents and ineffective for his practice. By the late 80s, Dr. Eckhart was using the Herbst and had many successful treatments, but patient complaints were common because of lip/cheek irritation.

In 1991, he was attracted to an appliance created by Dr. Douglas Toll, of Germany, which he called the MARA (Mandibular Anterior Repositioning Appliance). It consisted of cams on the molars that guided the patient to bite into Class I. The appliance was low in bulk and easily tolerated by the patient. Drs. Eckhart and Toll began experimenting with ways to improve the appliance's reliability and provide greater flexibility in adjustment. By 1995, with the help of Ormco and AOA laboratory, a new design was provided for clinical trials. Clinical trials were successful and the MARA has been evolving ever since.

Over the years as demand for the MARA has increased the appliance has been modified simplifying even more an already simple alternative to the Herbst. The appliance comes in a variety of designs enhancing patient comfort and advancement capabilities as well as accommodating expansion in the upper and/or lower arches.

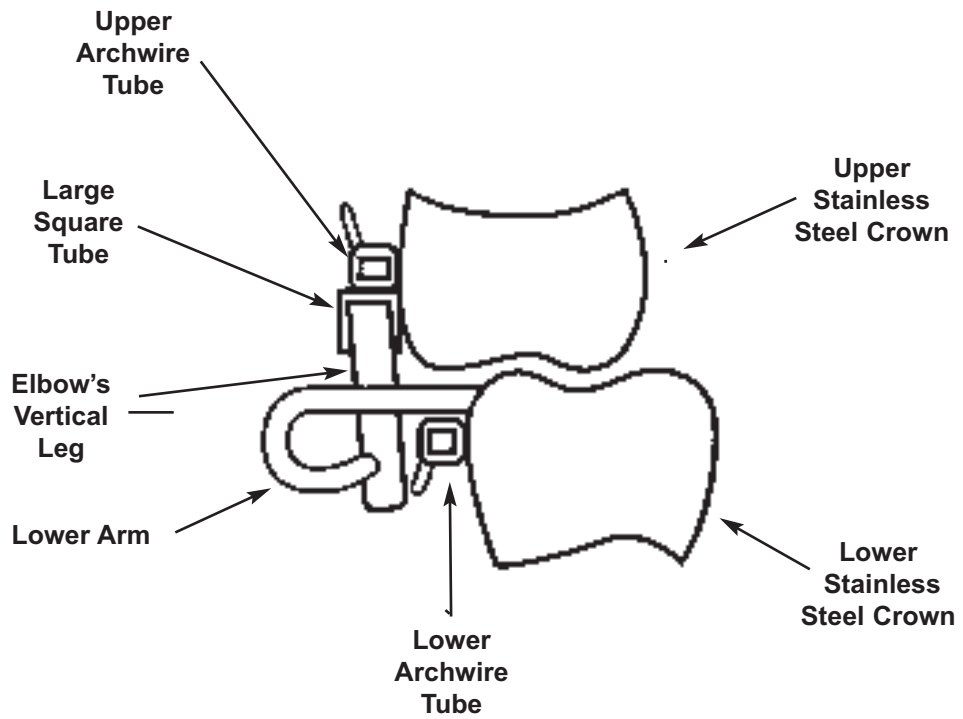
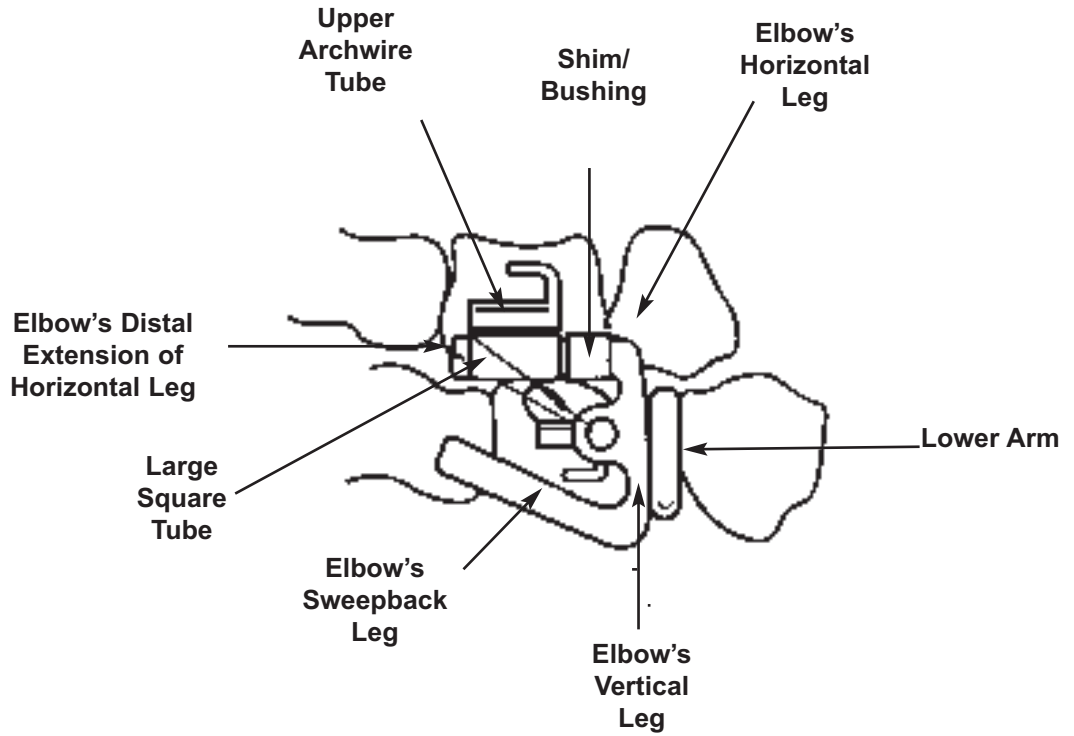


## Advantages of the MARA:

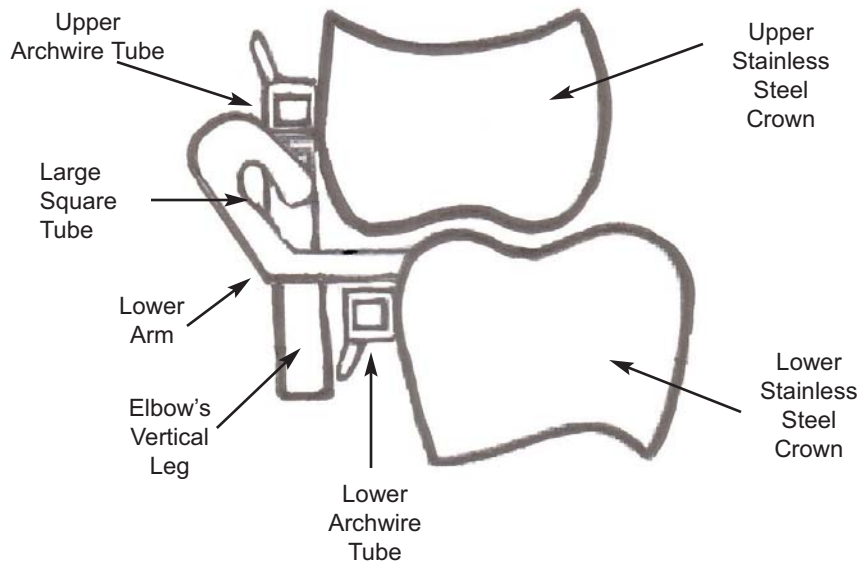
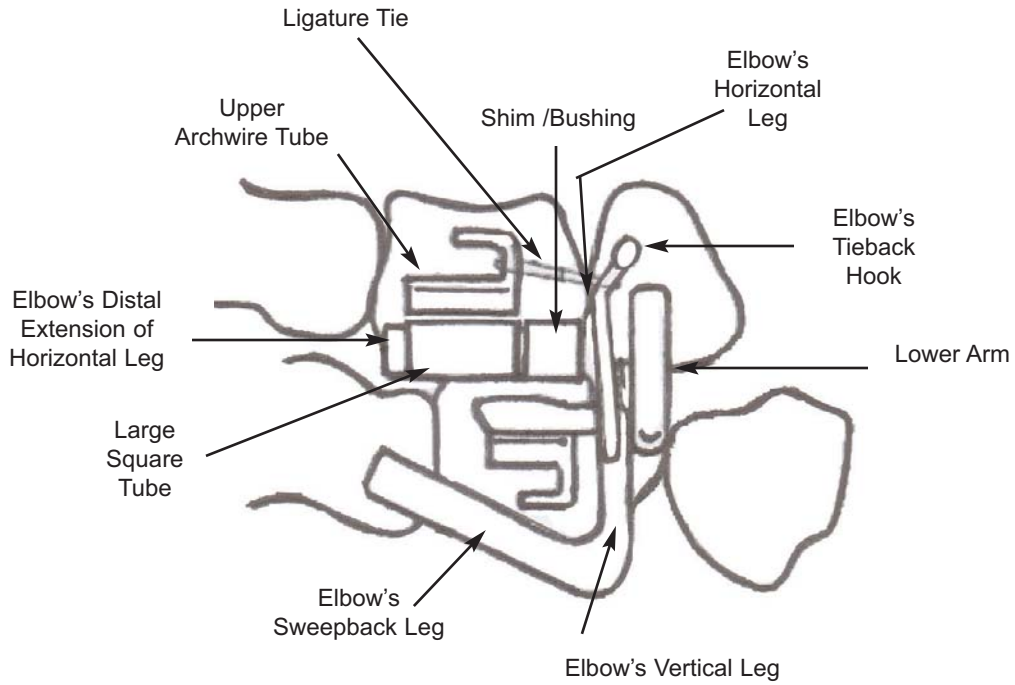
1. The patient's profile immediately looks better after the appliance has been inserted.
2. Class II malocclusions are treated more efficiently, making treatment much easier on the orthodontist, staff, patients and parents.
3. The MARA gives an immediate distal movement to the upper first molars and a simultaneous mesial to buccal rotation.
4. Stainless steel crowns are easier to fit, stronger, less expensive and have more retention than bands.
5. There are no removable parts, thus cooperation is not an issue; treatment time is predictable.
6. Breakage is minimal and speech and hygiene are not a problem.
7. Orthodontic appliances can be worn in conjunction with the appliance.



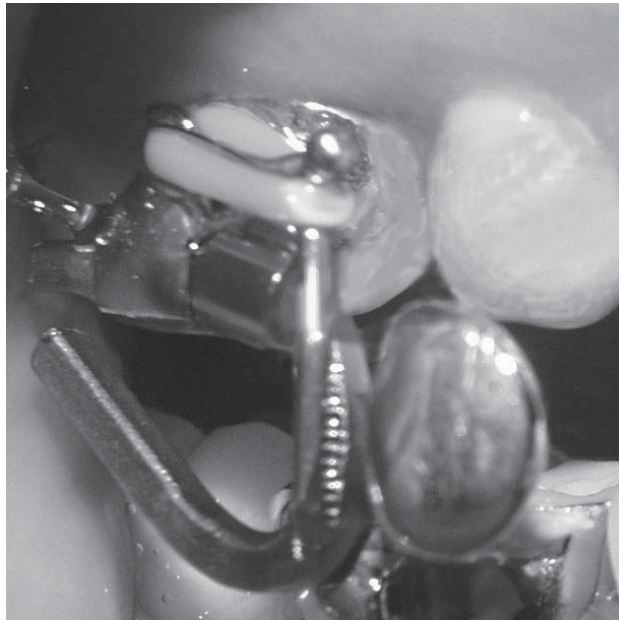
# Standard MARA



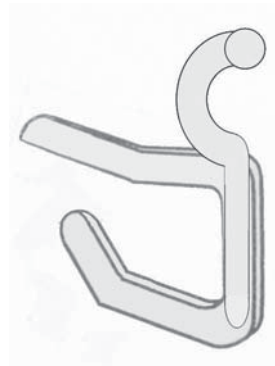
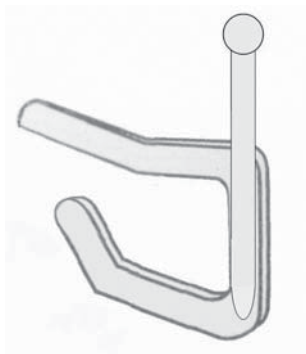
**MARA "U" (with the lower arm curling upward, for greater vertical engagement of the elbow's vertical leg)**



Diagrams are for clarification of terminology and are not perfect dimensional or positional reproductions.

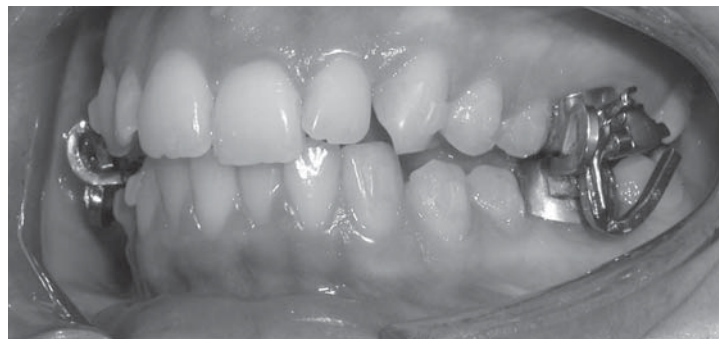
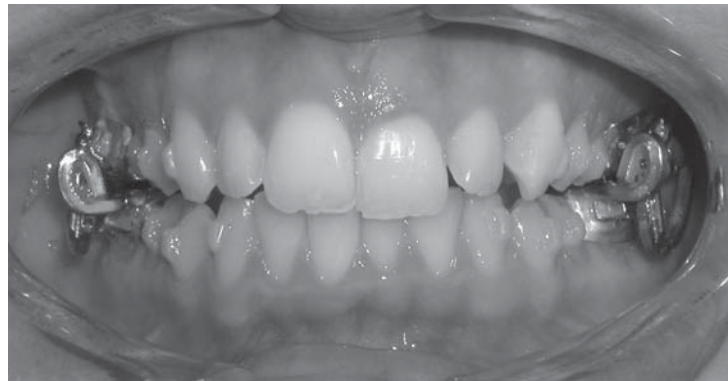
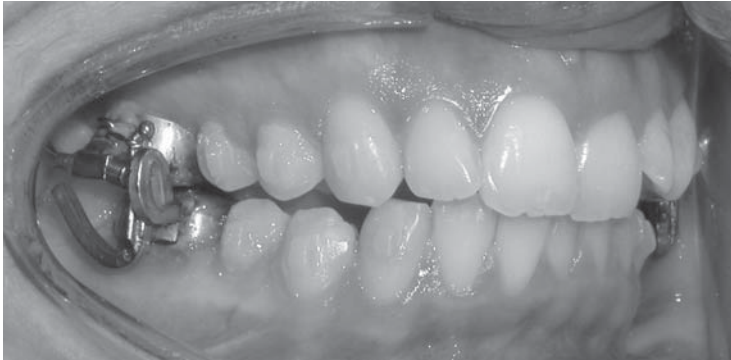The MARA U (with the lower arm pointing upward) with a buccal shield on the lower arm.



The ball hook on the elbow needs to be modified for the MARA U so that the upward-facing lower arm will not abrade the tieback ligature.

## MARA U



The MARA U has the lower arms curling upward, providing greater vertical overlap against the vertical leg of the upper elbow, preventing early disengagement and keeping the patient in Class I occlusion more effectively, especially in deepbite cases which tend to create posterior openbites when advanced.


## Current MARA Designs, Terminology and Accessories

The MARA can be modified to accommodate upper and/or lower expansion, a transpalatal arch, lower lingual arch adjustment loops, a buccal shield on the lower arm, orthodontic appliances, distalization of upper molars and the MARA can be used unilaterally as well as with asymmetric cases. Several variations in the advancement elbows are also available.

As the orthodontist becomes comfortable in his or her command of the appliance, the simplicity of design becomes more appreciated because there is little to master.

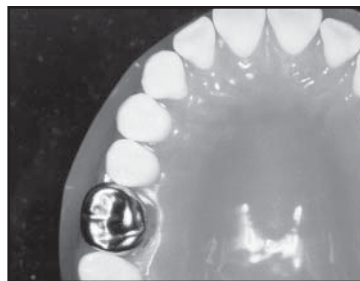
A basic MARA consists of:

1. Four crowns on the first molars.
2. The lower arms (square wire) soldered to the crowns.
3. Archwire tubes soldered to the crowns for the upper and lower archwires .
4. Upper elbow tubes soldered to the crowns.
5. Upper elbows shimmed to provide the desired advancement.
6. Lower lingual arch soldered to lower crowns (recommended). A lingual arch is useful because the upper elbows will have a tendency to cause the lower molars to rotate and tip mesial lingual, thus crowding out the second bicuspid and making the lower arms ineffective in abutting the upper elbows.

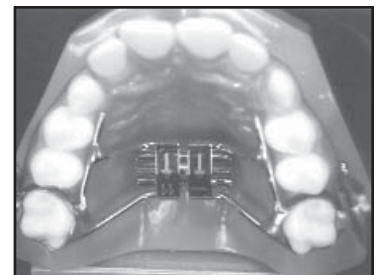


**Basic MARA**

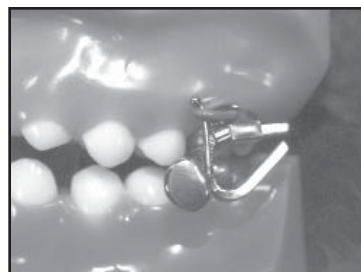Crown removal holes optional.




**Upper expander added to Crown MARA.**



**Upper expander added to Banded MARA.**




**"Simon Buccal Shield" added to lower arm of a MARA.**



**Modified removable screw advancement elbow.**

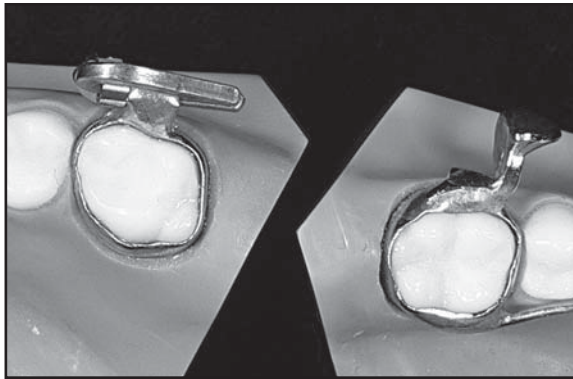


**Close up MARA "U"**



**Standard MARA elbow.**

**Band Design Modifications** - Bands require reinforcement and are prone to breakage. If using a band design, provide the laboratory with a thick blank band, or allow AOA

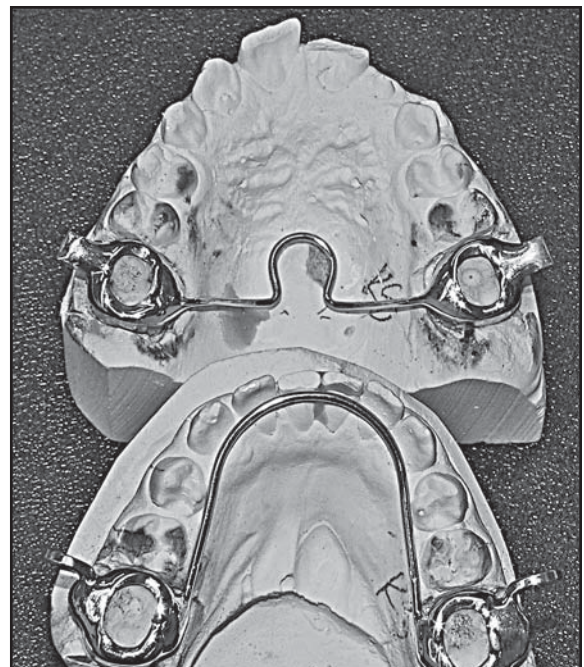


**Ormco UltiMax Band indirect fit by AOA.**

laboratory to provide and indirect fit a thick blank molar band to your work models. AOA routinely uses the Ormco UltiMax molar bands.

**Note: TMD symptoms have not been reported** from the design or advancements of the MARA and do not seem to be an issue. As with the Herbst, the MARA is frequently used to relieve TMD symptoms and is useful to recapture anteriorly displaced discs and to unload the joints. Dr. Toll, from Germany, recommends and routinely uses MRIs for a detailed position diagnosis and subsequent treatment modifications to obtain optimal disc repositioning.

**Note:** If there is concern that the occlusal coverage of the crown may cause TMD symptoms, the appliance can be modified by grinding the occlusal surface of the crowns. This still gives the strength benefit of using a crown instead of bands. The modification can be made by the laboratory or can be done in the office. If the modification is made in the office after fabrication, re-micro etch the crowns before cementing.



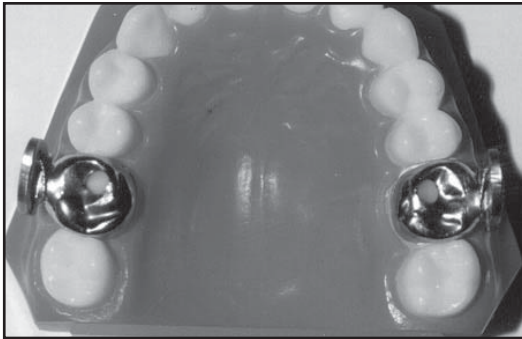
**2/3 Occlusal surface of crown removed.**

### **Design Modifications to Facilitate Crown Removal: (Optional)**

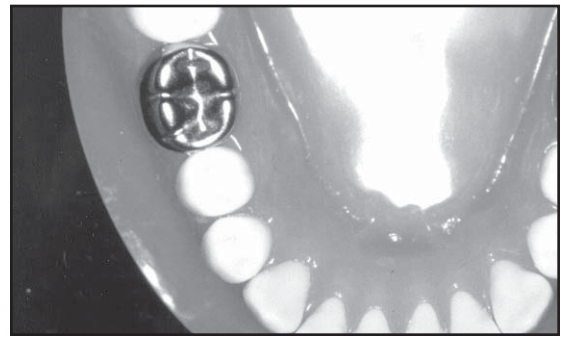
Adding occlusal holes, and horizontal removal slits to the crowns can simplify crown removal later. These modifications can be made prior to cementation at the chairside, or by the laboratory upon request.

#### *Occlusal Removal Holes (Optional)*

Occlusal removal holes are placed in the occlusal surface of the crowns to aid in removal of the appliance, especially if a crown removal plier (Ormco) is going to be used. This hole can be made by the clinician at the time of MARA removal, but some clinicians find it easier to have them placed by the laboratory technician during fabrication. An occlusal crown removal hole is about 1/8" in diameter.



**Maxillary occlusal removal hole located in the mesial lingual of the occlusal surface.**



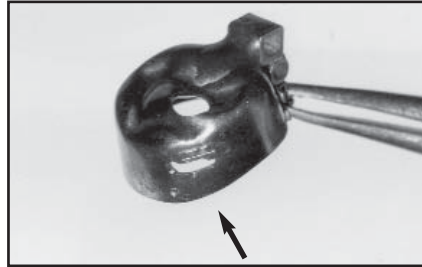
**Mandibular occlusal removal hole located in the mesial buccal of the occlusal surface.**

#### **Notes:**

Do not use Vaseline or ChapStick on the teeth if a crown removal hole has been precut in the occlusal surface of the crown. If there is a hole, the cement should set or cure before cleaning. Check for voids around the margins of the holes to avoid decalcification. *Provided that a barrier shield (Vaseline or ChapStick) is not used with occlusal holes, caries are virtually nonexistent when using glass ionomer cement with fluoride in it.*

### *Horizontal Removal Slit*

Horizontal removal slits are normally placed only on the mesial lingual corner of maxillary first molar crowns. They act as a purchase point for use with the Ormco "Chastant" crown removal pliers. The slit should be placed halfway from the gumline to the occlusal surface.



**Horizontal removal slit.**

### *Vertical Removal Notch*


The upper crowns may be pre-notched approximately 1.5 - 2mm on the mesiopalatal gingival, while the lower crowns may be notched 1.5 - 2mm on the mesiobuccal gingival just mesial to the lower arm. These notches will eliminate the need to use a bur subgingivally if the crowns are to be sectioned later. The notches aid in the removal of crowns when using the Ormco crown slitting plier.



**Maxillary crown  
vertical removal notch.**



**Mandibular crown  
vertical removal notch.**



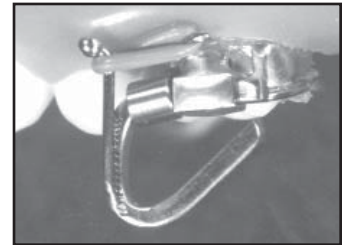


**Note:** To add vertical notches to the crowns yourself, rotate disc so any burs will be inside the crown. Be careful to stay within suggested guidelines. If the crown is notched too much it could weaken and split over time. It is also suggested to re-microetch the inside of the crown following this procedure.



# MARA Accessories and Treatment Enhancements

## MARA Accessory Kit

Every office should have a MARA Accessory Kit. Just enough spare parts to get you started. Introductory kit includes assorted elbow sizes (7 & 10mm), shims of various lengths (1-5mm) and torquing tool. Elbows, shims and torquing tools may be purchased separately from AOA.

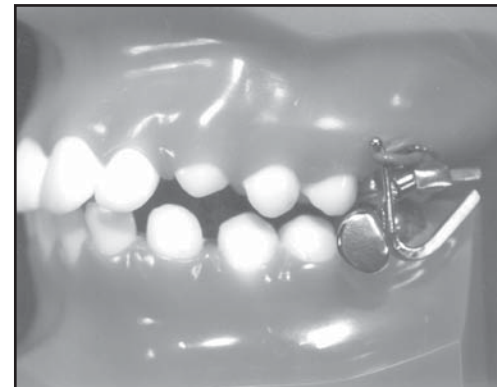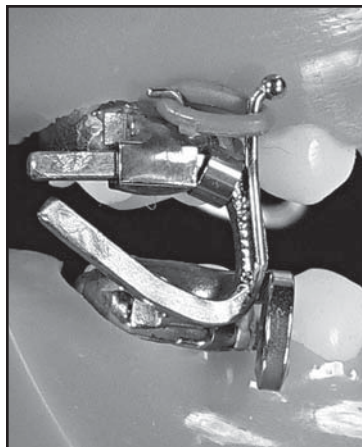

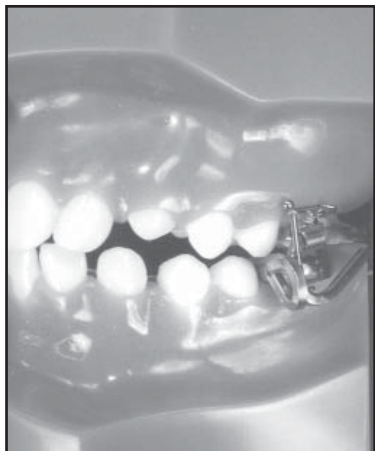
**MARA Crown Components** are available with presoldered MARA buccal attachments (upper tubes and lower arms). MARA crown components for all quadrants come in size 4,5,6,7,8, the most common sizes used. An inventory storage box is also available.

## MARA Demonstration Models

A demonstration model is always helpful initially when explaining to the patient and parent what the appliance looks like and how it works to correct the malocclusion. And after MARA insertion, the model is an extremely effective tool to use during the exit interview for clarification of any questions that may arise during treatment.

Demonstration models are custom fabricated to your specifications on the malocclusion of your choice. An effective marketing device is to have a typodont with a Herbst on one side and a MARA on the other, so the patient can see the smaller bulk of the MARA.



# Prior to Fabrication: Preparation for the MARA

## Diagnostic Records

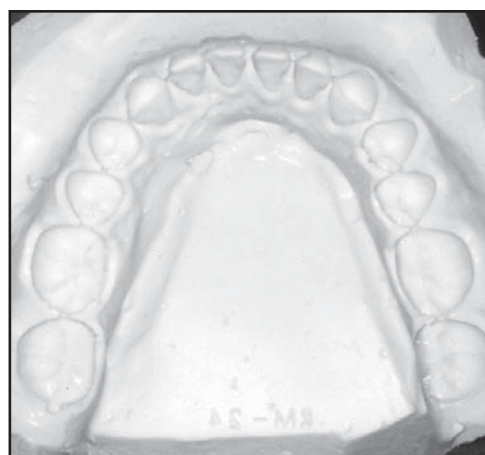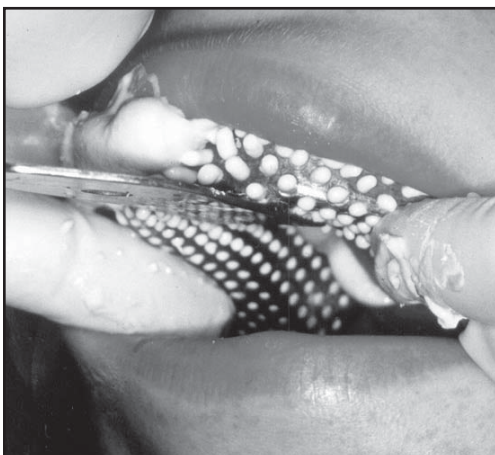Diagnostic records requirements are as diversified and unique as the clinicians' diagnoses.

Listed below is a compilation of recommended and optional records.

1. Cephalometric x-ray.
2. a) TMJ tomograms, transcranials, or TMJ oriented panorex.  
b) MRIs, *if economically feasible*.
3. Panorex.
4. Slides, photos or imaging.
5. Impressions for diagnostic study models.
6. Diagnostic wax bite.
7. A second set of impressions for MARA fabrication.

## Impressions for Work Models

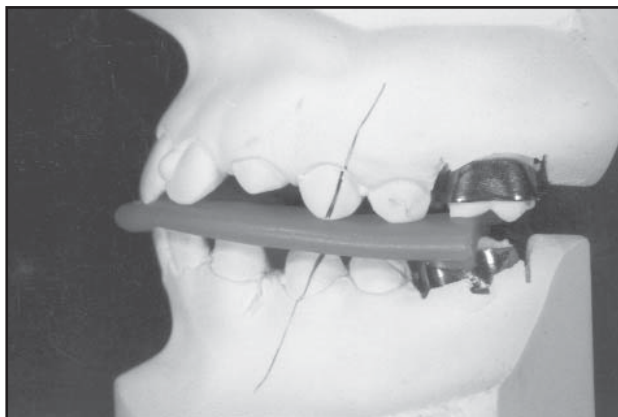
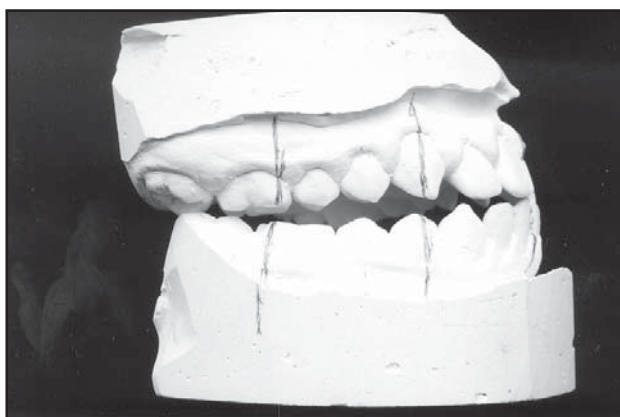
Maxillary and mandibular alginate impressions are required for the working models. Impressions must be free of distortions, bubbles and voids. Perforated or metal impression trays are recommended when taking impressions directly on the patient. It is important to keep in mind that the laboratory technician can only make an appliance to fit the models it receives, and it all starts with impressions.



## Bite Registrations

Wax or silicone bite registrations are not necessary when fabricating a MARA. Work models may be marked indicating the prescribed incisor and molar relationships in the advanced position. The amount of advancement to request depends on the severity of the Class II. If the case is 4-5mm Class II, advance it to end-to-end incisors. If the case is 8-9mm Class II, advance it only half way because to advance it the entire distance at once might strain the TMJ excessively and would probably lead to appliance breakage. It would also lead to the patient being able to bite behind the elbow in the retruded position, possibly locking up the appliance. The remainder can be advanced gradually over six months. The advancement marks should show the midlines centered over each other.

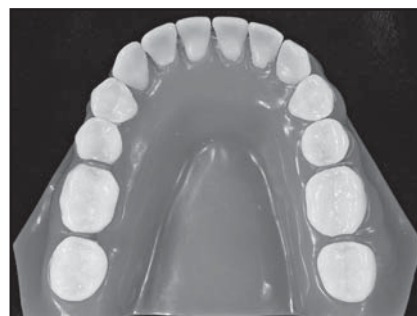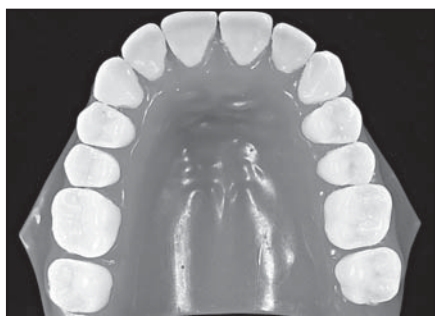
**Pearl:** While not necessary, a silicone or wax bite sent along with marked work models is sometimes of help to the laboratory technician when ascertaining the vertical leg height of the elbows.



## Placing Separators

MARAs only require separation of maxillary and mandibular first permanent molars. Separators are placed one or two weeks before appliance insertion.

**Note:** If the laboratory is going to indirect fit your crowns/bands, you do not need to separate the teeth before taking impressions for the work models. The lab will disc the model when fitting the crowns. Schedule the patient to return one week before appliance delivery to place or replace lost separators, if they were put in at the time you took impressions, so there will be space on delivery day.



## Requirements that Effect MARA Placement

1. The patient may present with a very small vestibule and not enough room in the back cheek area to accommodate the MARA's lower arm and upper elbow placed on the crowned permanent first molars. In this case wait until the patient is older - *don't treat patients too young*. Late mixed dentition all the way through advanced adulthood is appropriate. If you must treat a younger patient, consider either placing the MARA on the deciduous second molars or cantilevering the MARA forward 4mm from the permanent first molars.
2. The first molars must be well erupted. No operculum should cover the distal of the lower first permanent molar.
3. Make sure the maxilla is wide enough. Check that the upper and lower arches are coordinated when the mandible is placed in the advanced position. If not, expansion of the upper and/or lower arches may be indicated before or concurrent with MARA insertion.
4. The upper incisors should be uncrowded, properly torqued, and intruded if necessary, so they can serve as references for where to move the lower incisors.
5. Don't advance severe Class II patients too far initially. The patient will find it difficult to function in the advanced position and the appliance may lock up.

**Note:** The goal is to advance the incisors to end-to-end incisal relationship overcorrection. because some relapse is expected. *A medium 4-5mm Class II* can be advanced the entire 4-5mm initially. *A severe 8-9mm Class II* should be advanced halfway (4-5mm) at first. Hold the patient at the halfway advancement for about 2-3 months. Final advancement should be to the end-to-end incisal relationship and held for an additional six to nine months.

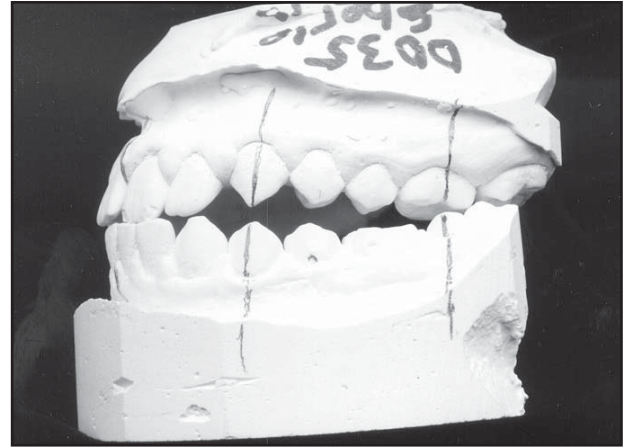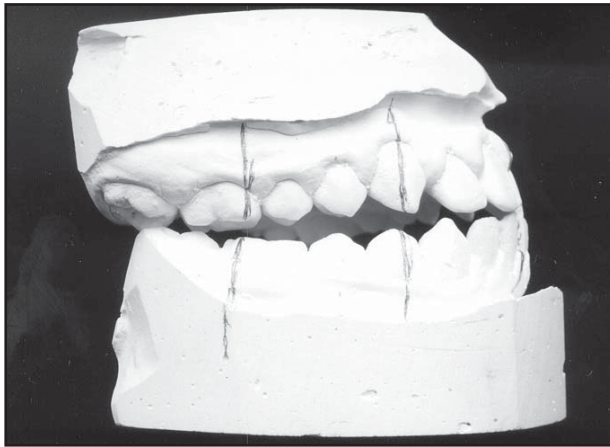
**\*Alert:** Mark guidelines on work models to reflect only the partial advancement in a case where a two-phase advancement will be necessary.

## Work Models for Appliance Fabrication

### Crowns or Bands Furnished and Fit Indirect by Laboratory Technician

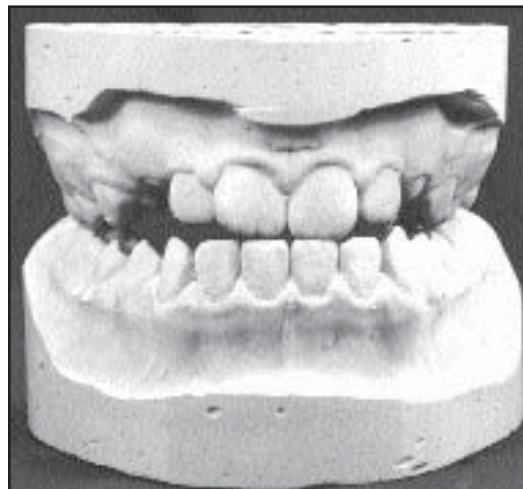
Impressions are poured in hard orthodontic stone. The models must be free of any voids or distortions. The work models are hand articulated into the advanced position, usually a Class I, edge-to-edge. Mark advancement guidelines on the models in pencil extending from upper to lower arch. Also mark midlines. The laboratory will use these lines to mount the models to the clinician's prescription.

**Note:** A wax bit construction bite helps if there is much interocclusal space between the molars when the mandible is protruded, because it allows more accurate judgement of the vertical height needed for the elbows.



**Note:**

If the patient's models are in a buccal cusp-to-buccal cusp relationship or in a lingual cross-bite when articulated into the advanced position, this is an indication that the maxillary arch is too narrow. The patient will need to have the upper arch expanded before placing the appliance, or an expander can be incorporated into the appliance during fabrication. If the patient's maxillary arch is too narrow, the upper elbows on the MARA will be unable to hang buccally to the mandibular crowns without excessive buccal flaring, which causes difficult engagement of the lower arms and cheek irritation. The laboratory should recognize the problem during the *fabrication process and call to discuss options.*



# Sending Models and Prescriptions to the Laboratory

## Prescription Considerations

Before shipping the work models to the lab, the models should be referenced to the prescription sheet for design specifications and inspected by the clinician or clinical coordinator to ensure that they have been marked properly. Prescription sheets should be filled out in detail. Drawing design modifications on the prescription sheet along with written instructions keep technical errors to a minimum.

**Pearl:** The #1 common cause of incorrect crown adaptation is the presence of the operculum tissue over the distal of the lower first molars. In this situation it is recommended that the lower first molars have an operculectomy or be sized with bands, which are sent along, allowing the lab technician to use them as an aid in identifying the molars' distal cusps being hidden under the tissue.

## e - MARA

The e-MARA order form allows you to by-pass mailing working models to the lab for fabrication of the MARA. By measuring the mesial-distal widths of the first molars on your study models, the correct size of stainless steel crowns for the MARA can be chosen from a table on the order form, and by using a clear acetate overlay template of lingual arch shapes (available from AOA), the correct size of LLA can be chosen, and the information can be entered onto an electronic order form and e-mailed to AOA or to the lab of your choice which makes MARA's for you from inventory purchased from AOA. After you have some experience fitting MARA's made by AOA on your models, this option may appear feasible and save you the time of mailing models.

**LAB USE ONLY**

**FUNCTIONAL R<sub>x</sub>**

Dr. \_\_\_\_\_ Acct. # \_\_\_\_\_  
 Address \_\_\_\_\_  
 City St Zip \_\_\_\_\_  
 Patient \_\_\_\_\_  
 Tel \_\_\_\_\_ Fax # \_\_\_\_\_  
 E-mail \_\_\_\_\_  
 Shipped \_\_\_\_\_ Placement Date \_\_\_\_\_  
 (PLACEMENT DATE SHOULD BE 1-2 DAYS BEFORE ACTUAL INSERTION DATE)  
 PLEASE WRITE SPECIAL INSTRUCTIONS

*(Dental arch diagram with labels: R, UPPER, L, L, LOWER, R)*

**Clasps**  
 Adams  Arrow  Ball  
 Other \_\_\_\_\_

**Labial Bow**  
 Standard  Buccinator

**Headgear Tubes**  
 .045  .051

**MARA –  Standard Design Includes**  
 Lingual Arch and 1<sup>st</sup> Molar Crowns  
 with .022 Archwire Tubes

Upper Expansion Screw  
 Single Guide Pin Screw  
 Trans Palatal Arch  
 Occlusal Wire Rests \_\_\_\_\_  
 Buccal Shields  
 Occlusal Holes  
 Standard  2/3 Crown

**e - MARA**

1001 Spring Street, P.O. Box 170, Channahon, IL 61018  
 815.521.2121, 815.521.0170 Fax 815.521.0170  
 AOA's Best Value! Call 815.521.2121  
 800.828.2828, 800.828.2829 Fax 800.828.2829

Address:  Home/Office  School/Work  
 Other \_\_\_\_\_  
 Address: \_\_\_\_\_  
 City: \_\_\_\_\_ State: \_\_\_\_\_ Zip: \_\_\_\_\_  
 Patient: \_\_\_\_\_  
 Shipped: \_\_\_\_\_ Placement Date: \_\_\_\_\_

**Product Note:** Please take reasonable care in preparing your models. We warrant only the accuracy of the Form Rx Overlay. Considerable effort is made to insure that the Form Rx Overlay is accurate. However, we do not warrant the accuracy of the Form Rx Overlay if you do not use it as intended. Please refer to AOA Form 1-2000-0017.

Occlusal Molar Mesial-Distal Width of Molars			
Upper 1 <sup>st</sup> Molar	Upper 2 <sup>nd</sup> Molar	Lower 1 <sup>st</sup> Molar	Lower 2 <sup>nd</sup> Molar
18 mm	18 mm	18 mm	18 mm
19 mm	19 mm	19 mm	19 mm
20 mm	20 mm	20 mm	20 mm
21 mm	21 mm	21 mm	21 mm
22 mm	22 mm	22 mm	22 mm
23 mm	23 mm	23 mm	23 mm
24 mm	24 mm	24 mm	24 mm
25 mm	25 mm	25 mm	25 mm

Please check off your MARA's form - include parts and sizes:  
 Upper Crown, Standard Design, Right side only  Upper Crown, Standard Design, Left side only  
 Upper Crown, Standard Design, Right side only  Upper Crown, Standard Design, Left side only  
 Upper Crown, Standard Design, Right side only  Upper Crown, Standard Design, Left side only

**AOA e-MARA**

1001 Spring Street, P.O. Box 170, Channahon, IL 61018  
 815.521.2121, 815.521.0170 Fax 815.521.0170  
 AOA's Best Value! Call 815.521.2121  
 800.828.2828, 800.828.2829 Fax 800.828.2829

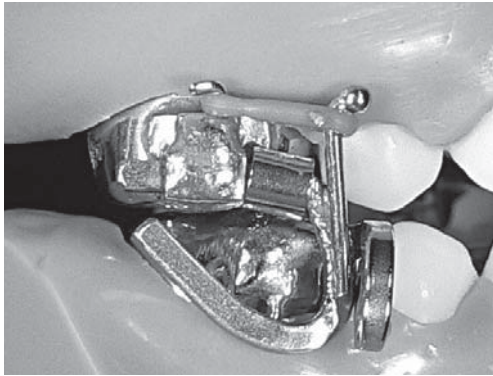
Address: \_\_\_\_\_  
 City: \_\_\_\_\_ State: \_\_\_\_\_ Zip: \_\_\_\_\_  
 Patient: \_\_\_\_\_  
 Shipped: \_\_\_\_\_ Placement Date: \_\_\_\_\_

**Product Note:** Please take reasonable care in preparing your models. We warrant only the accuracy of the Form Rx Overlay. Considerable effort is made to insure that the Form Rx Overlay is accurate. However, we do not warrant the accuracy of the Form Rx Overlay if you do not use it as intended. Please refer to AOA Form 1-2000-0017.

Occlusal Molar Mesial-Distal Width of Molars			
Upper 1 <sup>st</sup> Molar	Upper 2 <sup>nd</sup> Molar	Lower 1 <sup>st</sup> Molar	Lower 2 <sup>nd</sup> Molar
18 mm	18 mm	18 mm	18 mm
19 mm	19 mm	19 mm	19 mm
20 mm	20 mm	20 mm	20 mm
21 mm	21 mm	21 mm	21 mm
22 mm	22 mm	22 mm	22 mm
23 mm	23 mm	23 mm	23 mm
24 mm	24 mm	24 mm	24 mm
25 mm	25 mm	25 mm	25 mm

Please check off your MARA's form - include parts and sizes:  
 Upper Crown, Standard Design, Right side only  Upper Crown, Standard Design, Left side only  
 Upper Crown, Standard Design, Right side only  Upper Crown, Standard Design, Left side only  
 Upper Crown, Standard Design, Right side only  Upper Crown, Standard Design, Left side only

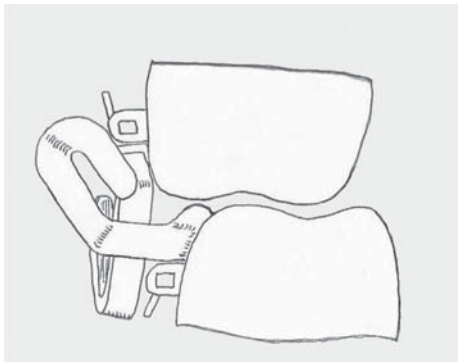
Standard MARA



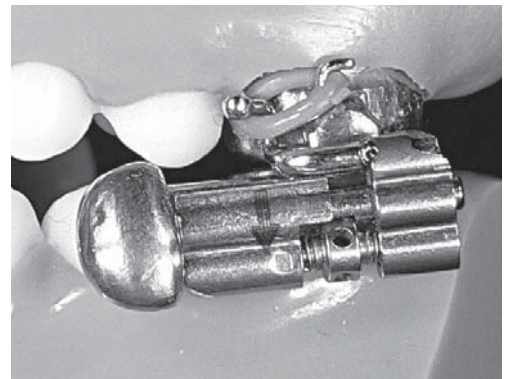
with buccal shields




MARA U (with lower arms pointing upward)




Jack-screw Upper Elbows



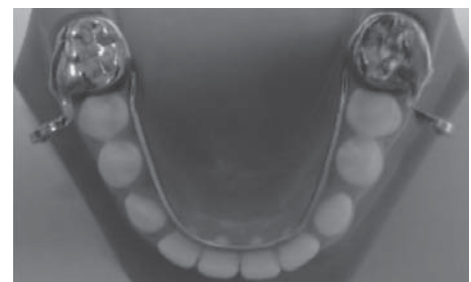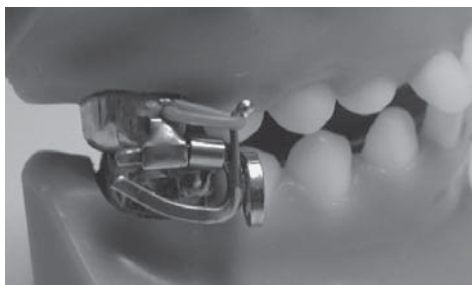Standard Upper Elbows



Long Horizontal Leg Elbow



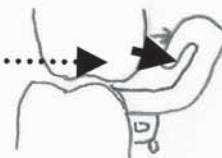
Cantilevered Lower Arms



Options offered on e-MARA electronic order form

## WHAT TO DO AT TRY-IN OF THE e-MARA

1. At try-in, you will have to do these steps in this order;
  - a. Verify the lower crowns fit (if too big, crimp the gingival margins and/or shim the inside of the crowns by welding in band matrix material...or re-solder a smaller crown from your inventory. If too small, re-solder a larger crown from your inventory.)
  - b. If the vertical loops impinge on the gingiva, adjust their torque.
  - c. If the anterior-posterior length of the lingual arch needs adjusting, adjust the vertical loops.
  - d. Adjust the lingual arch so it lies near the lingual gingiva and does not crowd the tongue, and rests on the cinguli of the incisors passively.
  - e. Adjust the torque of the crowns so they fit passively.
  - f. Adjust the posterior width of the lingual arch so it is passive.
  - g. If using the MARA U, adjust the lower arms so they clear the upper teeth.
  - h. Verify the upper crowns fit (if too big, crimp the gingival margins and/or shim the inside of the crowns by welding in band matrix material...or select a smaller crown from your inventory. If too small, select a larger crown from your inventory.)
  - i. Decide how much to advance the patient initially, select elbows with appropriate shims from your inventory, and adjust the torque and in-out of the vertical legs of the elbows.
  - j. Once these adjustments steps are done, the rest of the cementation is the same as a lab-constructed MARA.
2. The advantage of this process is that no models need to be sent to the lab, yet a reasonably accurate appliance can be ordered by e-mail, including a soldered lower lingual arch. This saves considerable time and cost. Additionally, extra parts can be ordered by e-mail to build up and maintain a modest inventory.





## Crowns or Bands Furnished and Fit Direct by Clinician or Clinical Staff

Fitting your own crowns will require keeping an inventory which is expensive. There are seven sizes of molar crowns of which four are used regularly (4,5,6,7). However because of the size limitation crowns will not fit precisely. There will be a little play in them when seated.

Since crowns are expensive and tend to distort when fitting, you may find it convenient to purchase a crown sizing "crown fit" kit to facilitate the fitting procedure. Ormco has a precontoured, pre-trimmed trial crown kit. These crowns have lasered size markings and can be sterilized and reused until they are beyond reshaping. When using the trial kit, you must then use Ormco crowns to fabricate your appliance. Once you have selected the size, simply notify the laboratory to use Ormco crowns and note on the prescription sheet the patient's Ormco crown size for an accurate indirect fit.



**The Crown Fit Kit from Ormco can be used to size crowns for any crown-bearing orthodontic appliance.**

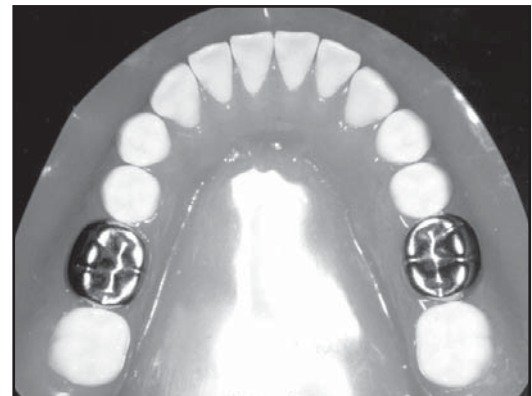
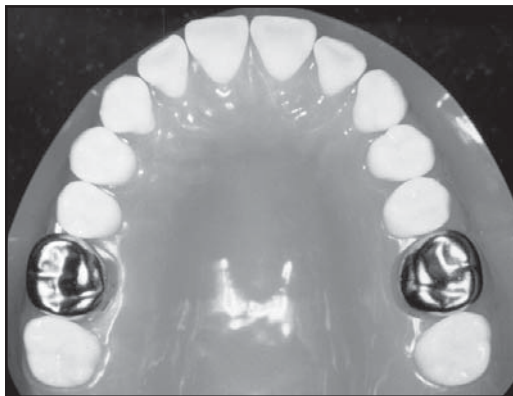
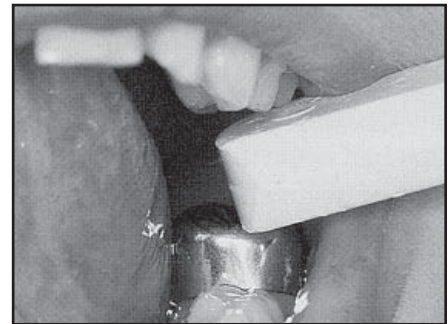

Molar bands come in a variety of sizes and most offices keep an inventory. However it is important to note that standard orthodontic band material thickness is .007 which is not strong enough to hold up to the forces the band will be exposed to during MARA treatment. It is highly recommended that you use a band material thickness of at least .010 to ensure maximum durability and minimal breakage. The only band available that currently meets this criteria is the UltiMax band (Ormco).

### Clinician/Staff Direct Fitting Bands

1. Remove separators from teeth. Separators should be placed one week prior to fitting bands.
2. Blank bands are fitted on the upper and lower first molars. Size bands to fit exactly if using the thicker .010 band. Bands fitted too large can contribute to loose appliances.

## Clinician/Staff Direct Fitting Crowns

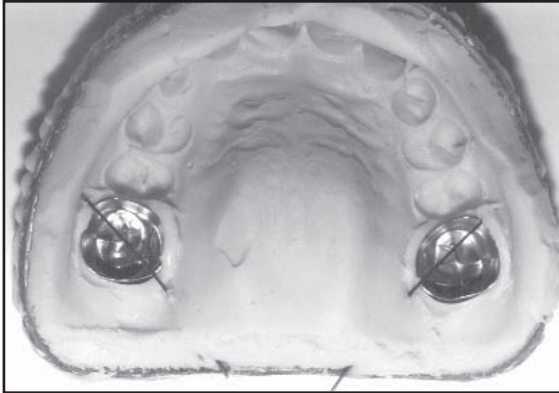
1. Fit crowns on teeth (one at a time and then removing them to prevent aspiration) checking size and length of crown. Starting with a size five crown and going up or down will help the novice in sizing.
2. The crown should slide in easily, with some resistance, and slide down on the occlusal surface without pinching the soft tissues.
3. Once the crown has reached about three quarters of its seating position with thumb pressure, it is beneficial to use a bite stick to complete seating. Place handle portion of the bite stick in the central groove of the crown at an angle matching the cuspal incline and have the patient bite it down from there.
4. The crown can be removed with fingers, an explorer, scaler, or crown remover pliers. Only use a crown remover plier if crowns have removal holes placed before try-on. Otherwise, you may misshape the crown.



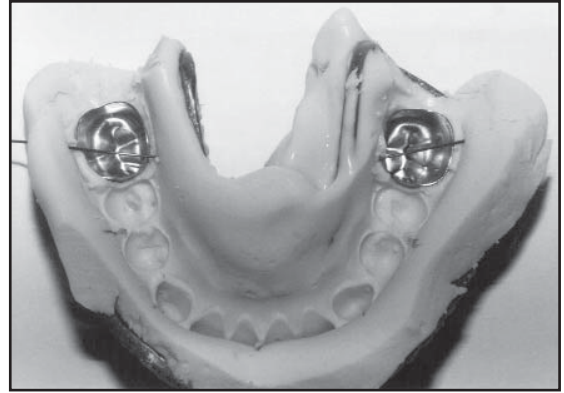
## Impressions and Work Models when Clinician/Staff Fit Crowns/Bands

1. *Crowns/bands to be incorporated into the work model* will require that the impressions be taken with the *crowns/bands seated* on the teeth. Remove crowns/bands, place in impressions securing with wax or preferably a pinning technique to ensure that the crowns/bands do not move while pouring the stone.

**Alert:** Due to the smooth form of crowns, they can easily be mistakenly placed in the impressions backwards or switched from right to left.



**Upper impression for a MARA with crowns held in place with short pieces of stainless steel wire.**

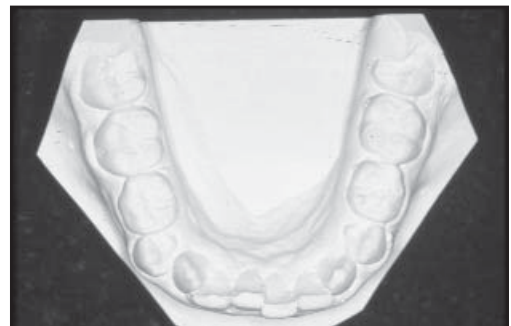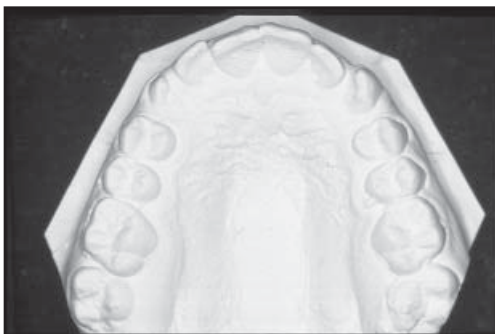


**Lower impression for a MARA with crowns held in place with short pieces of stainless steel wire.**

**Pearl:** Before pouring the impression in orthodontic stone, wax can be generously wiped inside the crown or band in the area where soldering is to be done on the buccal outside of the crown/band. This prevents the plaster from taking away heat from the crown/band during soldering. This way the crown/band material will not be overheated when soldering attachments. Overheating when soldering causes breakage.

2. *Your direct-fit crowns or bands to be placed indirect on the work models*

This procedure will require that the impressions be taken with the crowns/bands removed from the teeth. Crowns/bands to be re-fit on the work models by the laboratory should be sterilized, identified, bagged and the bags stapled to the prescription sheet. The work model should be poured in hard orthodontic stone.

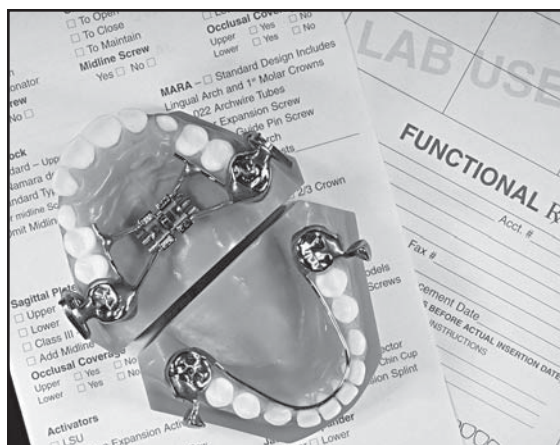


**Note:** Due to the breakage problems associated with using bands to fabricate the MARA, it is preferable to allow the laboratory to indirect fit thick blank bands on your work models. AOA routinely provides the Ormco UltiMax band.

# Delivery of the MARA

## Pre-Insertion Check List

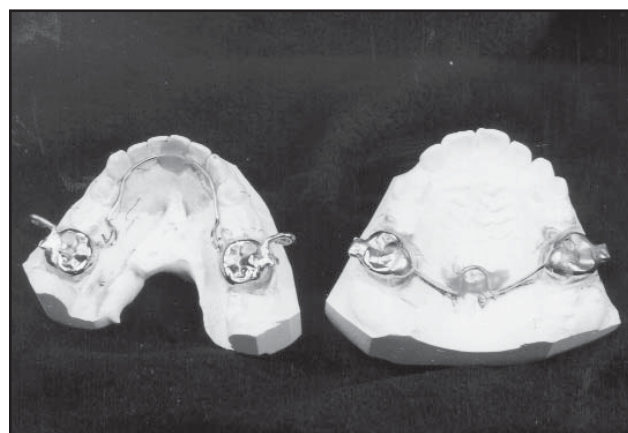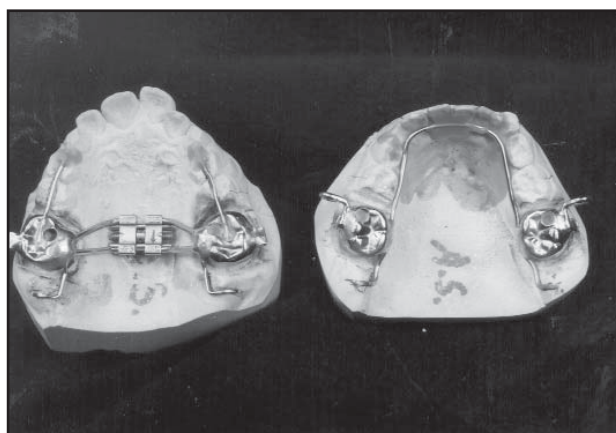
Several days before the patient's appointment check to make sure that you have the appliance and its components back from the laboratory. Review the prescription sheet to determine that the appliance has been made to specification and make sure that the work models and appliance identifications match your patient.



**Note:** To ensure accuracy, AOA laboratory returns all MARA's secured to the original work model with wax. The appliances are advanced to prescription specifications. Appropriate adjustments will also be made to the lower arms and initial set of upper elbows.

A torque key, uncut upper elbows that are longer in all dimensions and shims of 1-5mm lengths are available from AOA to accommodate future adjustments and activations.

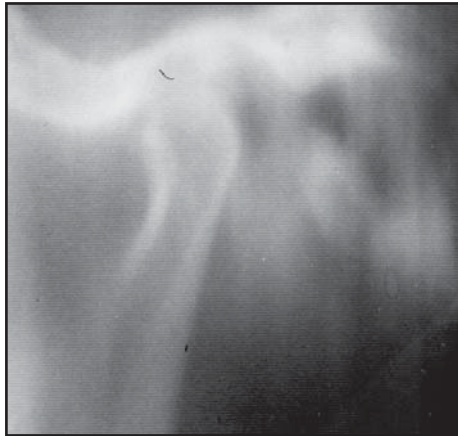
*Never discard work models until after the appliance has been inserted. If there is a problem, the original work models will need to be returned to the laboratory along with the new models. This procedure ensures quality control for both the laboratory and your practice.*



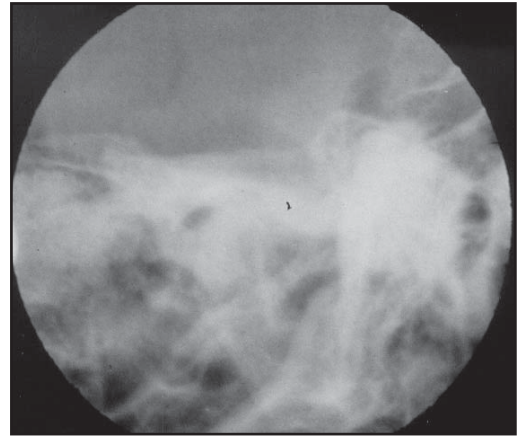
**Note:** The MARA is a versatile appliance and is modified depending on the treatment plan and clinician's preferences. Make sure the appliance returned to your office meets design specifications as noted on the prescription sheet for that particular patient. Above are examples of modified MARA designs fabricated by AOA laboratory.

## Clinical Insertion

**Step 1.** Many clinicians will take corrected tomograms or transcranial x-rays prior to seating the MARA. This is done to evaluate the initial position of the condyle and give the orthodontist a beginning baseline of joint morphology.



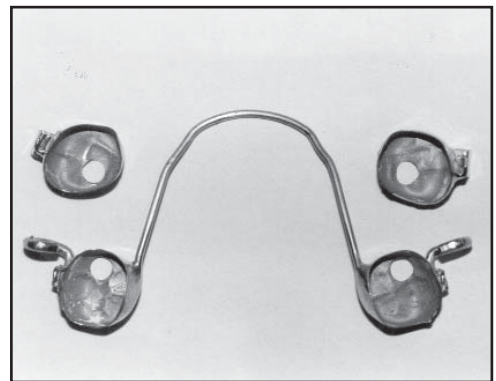
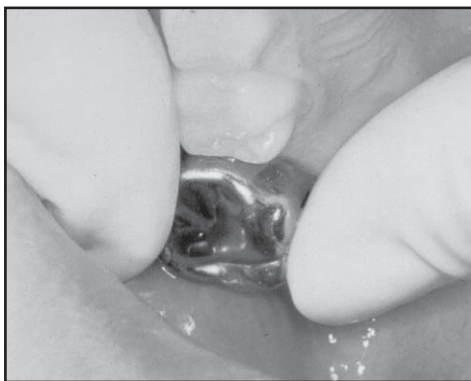
**Tomogram.**



**Transcranial.**

**Step 2.** Remove all separators.

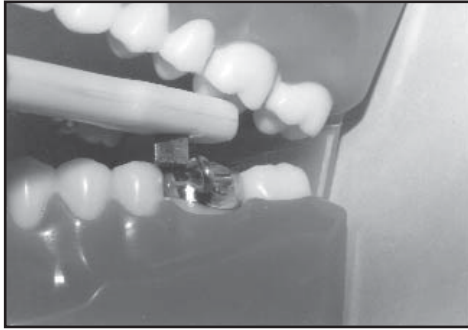
**Step 3.** Fit crown/band MARA components on teeth (*one at a time and then removing them to prevent aspiration*), checking size and length of crown/band.



**Note:** At this time document on the patient's chart any large restorations to teeth receiving crowns. Crown removal on such teeth could result in a fracture if using crown removing pliers that apply pressure to the occlusal surface of the tooth. In this situation, the cutting technique would be selected at the end of MARA treatment when the appliance is removed.

During the initial fitting procedure, if the crown has a tight snap fit and you cannot remove with your fingers, use an explorer or scaler to help pry it loose. Avoid using band and crown remover pliers since they apply pressure to the top of the crown and can cause distortions. However, you may use these pliers if a removal hole has been pre-cut into the crown allowing the tip of the pliers to rest on the tooth enamel. Care should be taken not to distort the gingival edge of the crown.

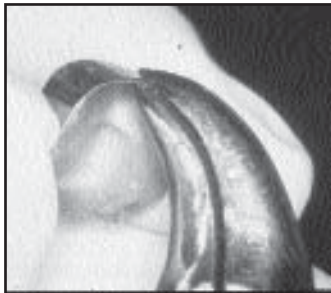
The crown should slide on easily, with some resistance, and slide fully down onto the occlusal surface without pinching the soft gingival tissues.



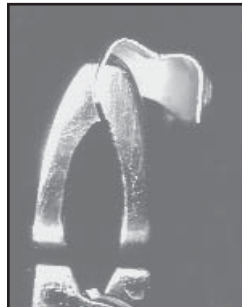Once the crown has reached about three quarters of its seating position with thumb pressure, it is beneficial to use a bite stick to complete seating. Place handle portion of the bite stick in the central groove of the crown at an angle matching the cuspal incline and have the patient bite it down from there.

### *Crown Adjustments*


Crown is too loose. Crimp the mesial and distal edges of the stainless steel crowns, using bird beak, Ormco crown contouring pliers, How pliers or Tweed arch bending pliers. Adjusting a crown in this manner can tighten it up to one-half size.



**Bird beak contouring plier.**



**Ormco Crown Contouring Plier.**  
*Cross section of contouring procedure using Ormco crown contouring plier. .*



**Tweed plier used to crimp a crown.**

**Pearl:** If the crown seems a little too large after crimping and you still want to go ahead with cementation, recrimp the crown very sharply close to the margin or edges all around the crown including the interproximal area. Do not try the crown on the tooth again. Fill the crown completely full with glass ionomer to compensate for the extra crown space.

**Note:** If your MARA design does not have occlusal removal holes and you usually use a barrier on the occlusal surface of the molars, you may consider **not** using Vaseline or Chapstick on the tooth with the loose-fitting crown. This will enhance bond strength by allowing the adhesive to flow into the occlusal grooves. You may want to make a notation on the patient's chart that extra cleanup will be required at the removal appointment.

Crown is too tight. It may have been over crimped, and you will need to straighten or flatten out the edges of the crown with How pliers. You can also trim the crown gingivally. Care must be taken whenever trimming crowns because certain types of contoured crowns get considerably larger when trimmed.

Crown is too long. If the patient complains that it is uncomfortable on the gingival tissue. Use a heatless stone or scissors to trim the edges slightly to relieve impingement. It is important to remember that the higher up you trim a crown, the looser it gets on the tooth.

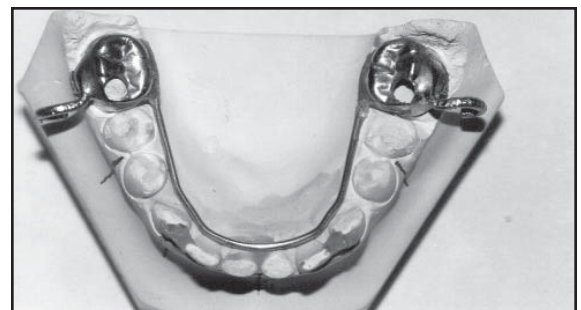
**Note:** Crown or crowns do not fit. Upper and lower impressions for a new set of working models should be taken. The original work models may have been distorted. When possible, direct fit a new crown on the tooth. If this is not possible, give the laboratory a detailed explanation of the crown problem. When returning a MARA to the laboratory, it is very useful for them to have the original models because examination of the original and new models may help to identify the fabrication problem.

**Step 4 :** Evaluate the placement of the mandibular arms and the lingual arch.

Adjustments to the mandibular arms are rarely required, but if necessary use heavy three-prong pliers. It is virtually impossible to make adjustments after the appliance has been cemented.

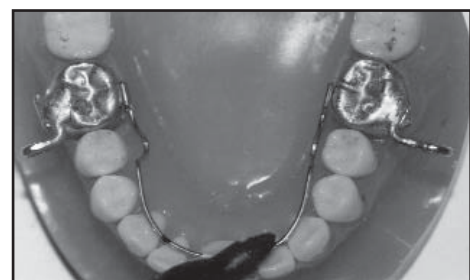
Check that the mandibular arms are aligned properly. If they are out too far, they will cause cheek irritation. To evaluate this effectively the upper elbows need to be slipped in place, since the elbows will partially shield the lower arms. If the lower arms are too far inward they will not engage the upper elbows, especially in Class II.

Check that the lingual arch rests very close but not on the cingulums of the lower incisors. The lower crowns may be rotated a little if necessary to make the unit fit better. Make sure the lingual arch is the correct width and is not expansive, nor narrowing to the lower molars.



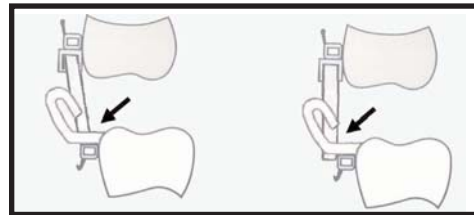
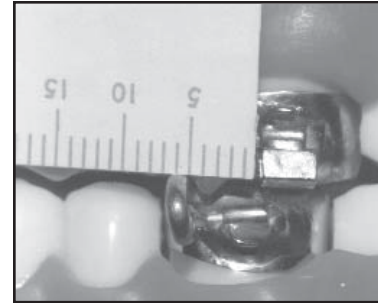
**Lingual arch rests correctly to cingulums and the arch is correct width in posterior. (Not expansive.)**

**Pearl:** Incorporating a small omega or adjustment loop into the lingual wire during construction can make the adjustment of this component simpler.



**Step 5.** Evaluate the upper elbows. Check the elbows in the mouth to make sure the elbows and lower arms fit together correctly.

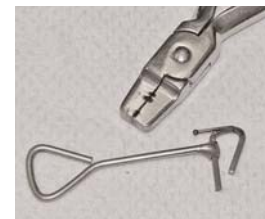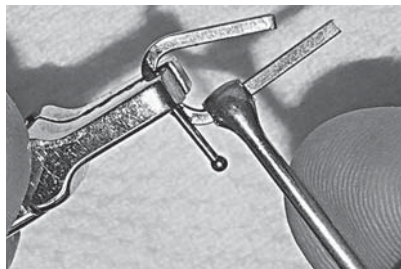
**a.** Once all four of the MARA crowns have been fitted, seat them and have the patient bite end-to-end on the incisors with the midlines on. Look to see that the space for the upper elbows is similar on both the right and left sides. There should be 4-8mm between the upper large square tubes and the lower arms. Any less will not allow the elbows to fit - any more may cantilever the elbows unnecessarily far. This distance can be adjusted by rotating the crowns on the teeth and bending the lower arms mesially or distally.



**Elbow torqued inward too tight.**

**Elbow torqued correctly.**

- b.** Try in both upper elbows.  
 1) Torque if necessary to fit barely outside the lower crowns.



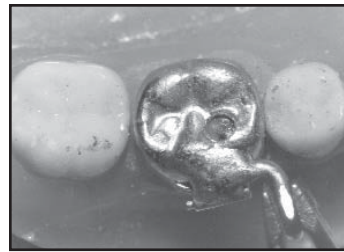
Use a torque tool and plier to adjust elbow in or out.

Use the torque tool, three-prong pliers and a Bernard/ Weingart plier to make adjustments. Adjustments are rarely required chairside during the initial delivery as they are made by the technician during fabrication.

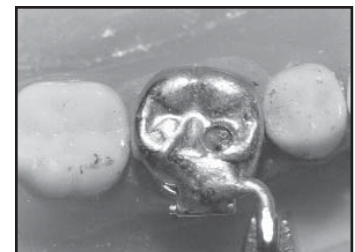- 2) Place shims on the upper horizontal legs of the elbows in order to achieve the advancement wanted and correct any midline discrepancies.
- 3) Both elbows should touch the arms when the midlines are on. To help achieve this relationship you can vary the rotational position of the lower crown and can bend the lower arm backward or forward.



**Vary the position of the lower arm by how you seat the lower crown on the teeth.**



**Lower arm rotated mesially on molar.**



**Lower arm rotated distally on molar.**




**Step 6.** Evaluate occlusal rests. Occlusal rests need to be checked for their approximation to the teeth.

### Adjustments to Occlusal Rests

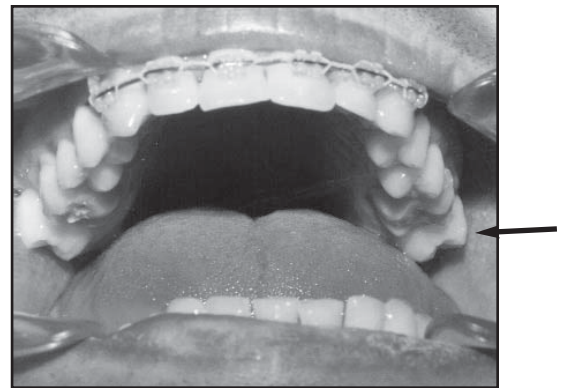
Occlusal Rest adjustments are easily made with How or bird beak pliers. However, caution should be taken when adjusting rests as they can break if annealed too much.

Premolar rests are usually bonded to the tooth and should be micro etched. *(AOA Laboratory will micro-etch these rests during fabrication).*

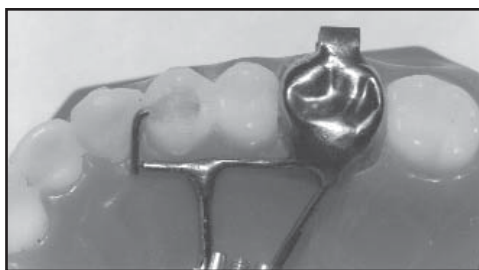
Second molar rests as a rule are not bonded.



Occlusal rests to second molars.



Extrusion of upper second molars due to MARA treatment without second molar rests, or composite occlusal build-ups.



Occlusal rests to upper or lower pre-molars are usually bonded to the tooth after cementation.

**Pearl:** If you have made considerable adjustments to occlusal rests, crowns or bands, you may want to re-microetch before cementing the MARA.

### ***Alternative to occlusal rests when super eruption is of concern:***

An alternative to metal occlusal rests is an occlusal buildup with composite/acrylic, fixed with the acid etch technique. This is usually placed on the lower second molars. Also, if intrusion of the first molars is not desired, as in deep bite cases, then lingual plateaus, or (bite turbos) can be fixed on the upper anterior teeth. *Buildups are placed after the MARA has been cemented.*

## Preparation and Cementation of MARA

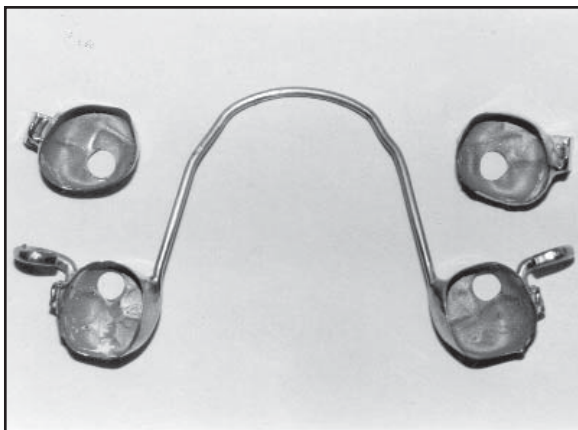
**Step 1.** Remove the elbows from the upper crowns or bands. (The lab usually returns the appliance with the elbows advanced and in place.)

**Note:** Most practices find it easier to cement the MARA without the elbows attached to the upper crowns or bands. However, if you choose to cement the upper elbows attached make sure the appliance fits in all dimensions.

**Step 2. Optional.** If necessary re-microetch the inside of the crowns or bands. The laboratory will microetch before returning the appliance. However, repeating this procedure would be applicable if there were a lot of adjustments made to these MARA components during initial fitting.

**Step 3.** Dry the MARA and all its components thoroughly, paying special attention to the inside of the crowns/bands.

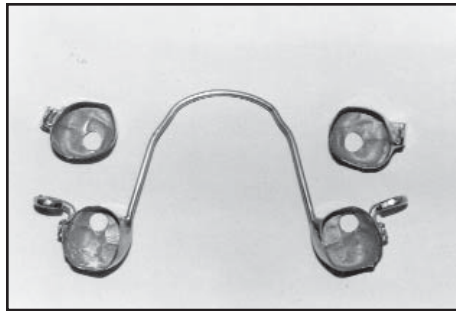
**Step 4.** Place toothpaste, lotion, or wax in any and all open areas of the MARA components. This includes upper tubes, upper and lower archwire slots, and also in the expander screw if one has been incorporated into the MARA design. Avoid getting toothpaste, lotion or wax inside the crowns as they may contaminate cement and weaken the bond.



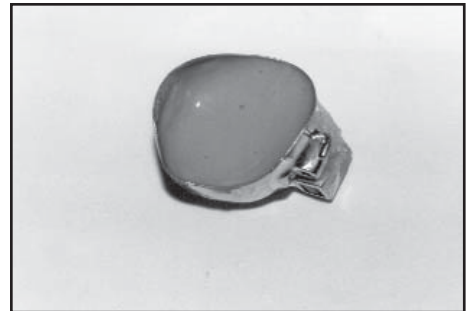
## Cementation of the MARA

### Step 1. Cementing Crowns or Bands.

- a. *Crowns:* Mix cement and place in the crowns. Crowns should be 1/2 to 2/3 full. Use a glass ionomer cement such as Fuji I, Ormco ProTech.
- b. *Bands:* A light-cure cement such as Ormco's OptiBand is recommended. The tooth surface will be prepped and bands placed according to the manufacturer's specifications.



MARA ready for cementing.



Crown filled with glass ionomer.

### Clinical Tips and other Pearls

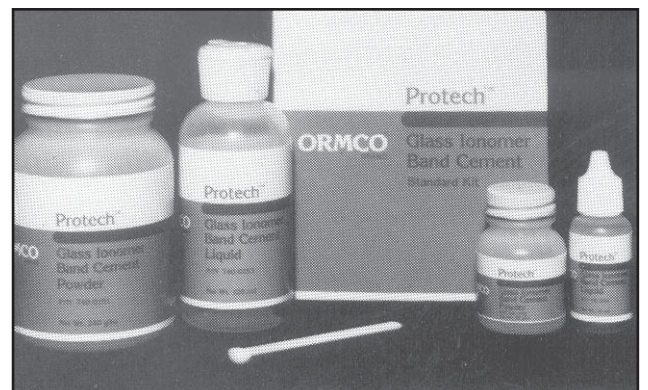
**#1:** Make sure the doctor is at the chair and ready to proceed as you are filling crowns with cement. If the cement hardens, you will lose about 45 minutes cleaning out the crowns and re-microetching.

**#2:** Because of salivation, it is recommended to start cementing crowns and bands to the mandibular arch first, then the maxillary arch.

**#3:** Using "Allwrap" or a similar material over the mixing slab will cut cleanup time. This material is found through dental supply houses and is the same material general dentists use to cover their equipment for sterilization considerations.

**#4:** If you are using a banded style MARA, be sure to tell the patient not to bang down on the lower arms. You will also want to only advance the mandible a couple of mm at a time getting the patient to an edge to edge relationship within the first six months of MARA treatment.

**#5:** Cements: Ormco's ProTech Gold glass ionomer is very good to use because its gold color is easily seen when cutting through the crown during the removal procedure, and during cleanup makes it easy to see that all of the cement has been removed.



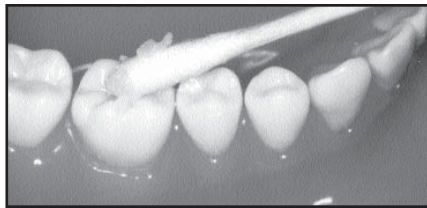
**Step 2.** Isolate, dry the tooth and set the crowns or bands.

**a.** Cementing bands:

1. A light-cure cement is recommended. The tooth surface will be prepped and bands placed according to the manufacturer's specifications.

**b.** Cementing crowns without holes on the occlusal surface:

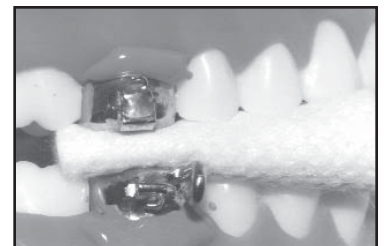
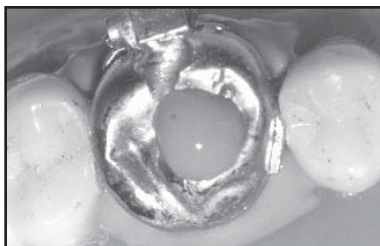
1. With a cotton applicator place a thin film of Vaseline or a little Chapstick on the occlusal surface of the tooth just before placing the crown. This will keep the glass ionomer out of the grooves simplifying removal of the crown and keeping cleanup time at removal to a minimum.



2. Clean excess cement from crowns and surrounding teeth immediately using the air water syringe and suction. When using a glass ionomer there is no reason to wait for it to set up before rinsing.
3. Have the patient bite on cotton rolls to hold the crowns still while the cement sets.

**c.** Cementing crowns with removal or vent holes on the occlusal surface:

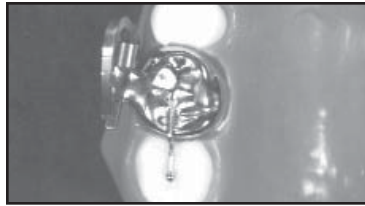
1. Do not use Vaseline or Chapstick on the teeth if a crown removal hole or vent has been pre-cut in the occlusal surface of the crown.
2. If there is a removal hole or vent, the cement should set or cure before cleaning.
3. Do not wipe the extruded cement away from the hole until it sets, and then leave a bit of excess to retard wash-out. Check for voids around the margins of the holes to avoid decalcification.
4. Because the cement escapes out of the holes, do not blow air around the removal or vent holes before the cement completely sets up.
5. Have the patient bite on cotton rolls to hold the crowns still as cement sets.
6. Clean off any excess cement after it sets.



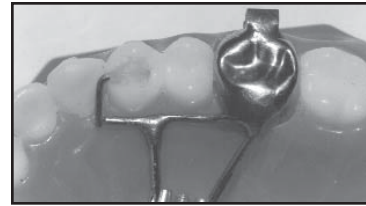
**Step 3.** Bonding occlusal rests that are located on the bicuspids. Prepare the bicuspid teeth for light-cure composite material, bonding one arch at a time. Place enough adhesive to fill in the occlusal grooves of the tooth and cover the metal rests. Cure adhesive with light. An adhesive booster is suggested to increase bond strength.

**Note:** Second molar rests are not normally bonded.

**Pearl #1:**



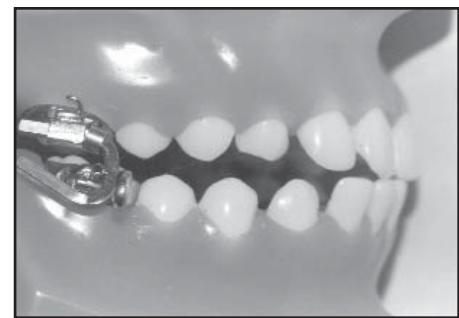Occlusal second molar rest.



Occlusal rest from expander bonded to premolar.

**Inserting MARA Elbows**

Slip the upper elbows into the upper square tubes, guiding the patient's lower jaw into the advanced forward position. At first, patients have a tendency to resist closing in this position. Telling the patient to bite their front teeth in an edge-to-edge position seems to help them learn the new bite pattern. If the patient has problems biting forward back up the advancement by exchanging the existing shims for a smaller size.



Patient biting edge-to-edge. Elbow engages lower arm correctly.

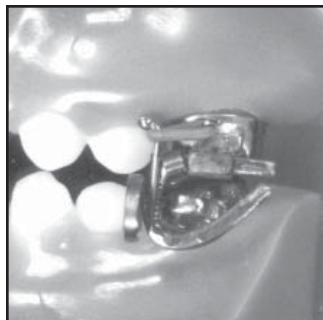
**Post-Insertion Bite Functioning Check List and Adjustments**

**Step 1.**

Check the elbow extensions to make sure they are not too long or too short in any dimension to insure maximum patient comfort and proper function of the MARA.

**Step 2.**

The patient should be able to open and close in front of the upper elbows without interference from the appliance and the lower arm should not extend more than 2mm beyond elbow.

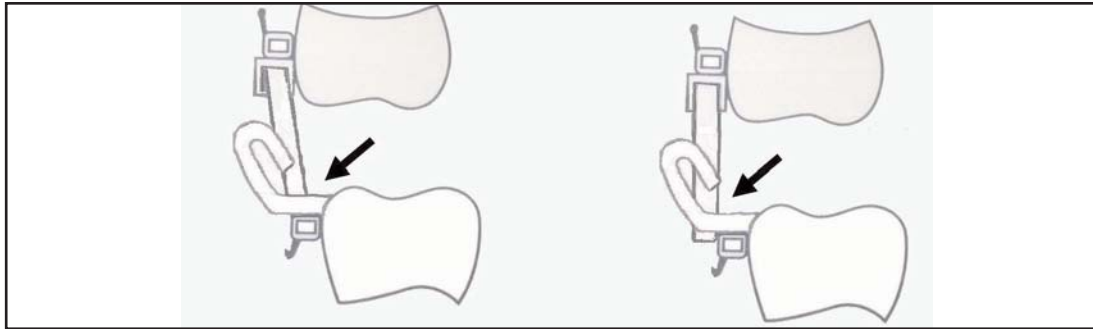


Elbow correct in all dimensions.



Upper elbow and lower arm correct. Patient can function properly.

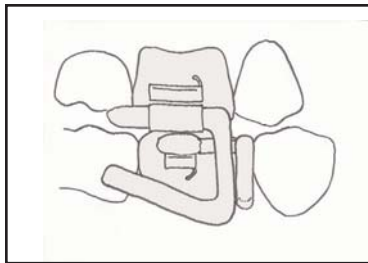
If the patient is unable to close completely because the expansion of the maxillary arch is not sufficient and, consequently, the inner surfaces of the upper elbows are touching the buccal surface of the mandibular molars, then the elbow should be torqued more buccally



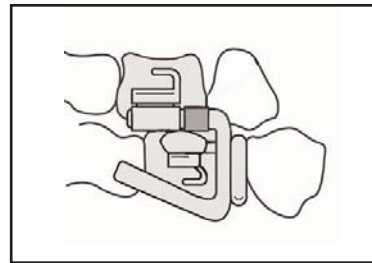
Elbows torqued incorrectly interfering with closure.

Elbow torqued correctly.

**Step 3.** Check that the patient's midlines are lined up and the occlusion has been advanced correctly. If midlines are off, correct by placing a shim/bushing on the upper elbow of the appropriate side that will shift the mandible over lining up the midline.




Midline off. Add shim to elbow to correct.

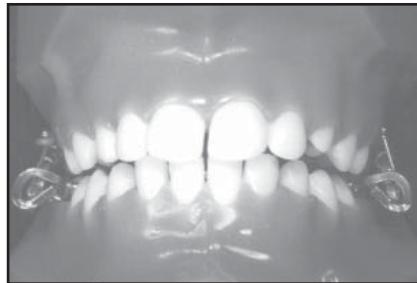


Midline corrected with shim added to elbow.

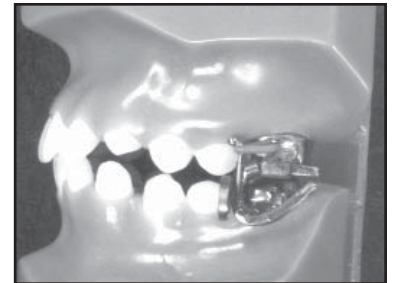
**Step 4.** When the appliance has been fit properly in all dimensions secure the elbows to the upper crown by placing a double steel ligature from the ball hook soldered to the elbow to the hook on the upper archwire tube, and then cover that with a heavy elastomer.



Elbow secured with separator elastic and/or .014 ligature wire.



MARA properly fit. Front view.



MARA properly fit. Side view.

## Post-Insertion Instructions to Patient/Parent

It is important to inform patients and parents that there will be an adjustment period and that problems associated with the appliance can arise. Discuss these issues in detail at the exit interview. A “care kit” and a written “instruction sheet” should be sent home with the patient. Educating and communicating with patients and parents empower them to take a proactive role in the management and care of their appliance during therapy, minimizing frustrations and resulting in fewer emergency appointments.

If the patient is a minor, the parent should always be present at the exit interview:

### Important:

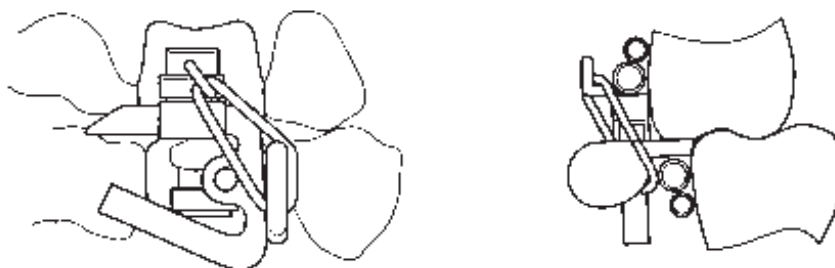
1. Explain that the patient will have to make a conscious effort to bite forward with the lower jaw until their muscles become accustomed to the new position, and it will take a good week before they feel completely comfortable. (Illustrate this for the parent and patient by physically guiding the patient’s lower jaw forward as they bite down, allowing the parent to see how the appliance functions properly.)

***This is a perfect opportunity to point out to the parent and patient how good the chin and profile looks when biting correctly in the appliance.***

2. The patient may bite their cheeks until they learn to avoid it.
3. Explain that there will be difficulty in eating for four to ten days and they will be biting on their incisors. Suggest that they cut most of their food into small pieces, keeping frustration with chewing to a minimum. They will be able to eat just about anything on their normal diet in a few days.
4. If it is not noted on the chart that the patient is a bruxer or mouth breather, ask the parent if the child sleeps with their mouth open at night. If they do, you may want to give the patient vertical elastics to keep the mouth closed while sleeping.
5. Explain the possibility of the lower arm getting locked into the upper elbow. Assure them this doesn’t happen often, but if it does and they cannot disengage it with gentle movement, they are to call your office and your office will provide immediate care. *(This rarely happens especially with the new lower arm design.)*

*Explain that unlocking the appliance can be done easily in the orthodontic office by simply cutting the ligature wire and/or removing the elastic and sliding the elbow forward. Once either elbow is removed, they unlock easily from the other side.*

**Note:** If it is a concern that a patient is a bruxer or sleeps with their mouth open and retruded as a mouth breather may, vertical elastics can be used to help keep the patient’s mouth closed and in the Class I position while sleeping or a new elbow with more vertical height may need to be placed.



6. There is not a hamster look with the MARA, but sometimes a patient may have a puffy look of the cheeks. Explain that the puffiness will disappear over the next several weeks.
7. The patient may experience soreness in the cheek area. Inform them that the soreness will go away as the tissue toughens and that a callus forms.

*Provide the patient with Orabase with Benzocaine, wax or cotton rolls to help alleviate uncomfortable symptoms that may occur.*



Should the patient experience an unusual degree of irritation or discomfort, the following options may be of help.

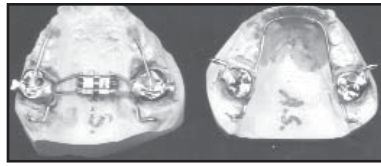
- a. A button the size of a silver dollar can be made with lab silicone to cover the offending attachments, usually the lower arm. (Fibers from a cotton roll can be incorporated into the silicone for strength.)
  - b. A light-cured material such as Barricade (a periodontal product) can be temporarily attached to offending MARA attachments.
  - c. A thick elastic can be stretched over the upper elbow, incorporating the circumference of the elbow during the day and including the lower arm at night. Or place elastics vertically, distal and mesial on the elbow, slipping them over the horizontal leg to the lower sweepback leg.
8. Explain that due to the exceptional forces on the appliance during chewing, a crown or band may come loose. *If the patient has a banded style MARA it is very important to stress that they avoid closing down with a lot of force banging the upper elbow against the lower arm. This behavior will weaken the band and result in appliance breakage.*
  9. An upper elbow can be lost in spite of being tied in with an elastomer and/or ligature wire. If the elbow comes loose, request the patient to save it and bring it back when they come in to have the elbow re-tied.
  10. Patients and parents should always be given written information flyers that describe the appliance, its function, and possible problems with solutions. Each office should create their own unique information sheet.

*AOA and the author invite you to take the information provided in the post - insertion instructions section and create a sheet for your patients.  
(see page 59 bottom for suggestions)*



# Expander MARA: Clinical Considerations

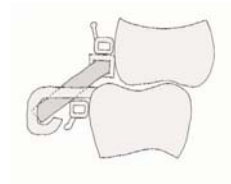
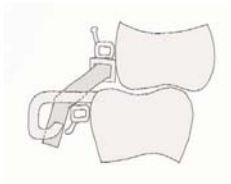
The MARA can be fabricated with a variation of expansion designs incorporating both upper and lower arches.



## Clinical Delivery

Delivery of the Expander MARA is basically the same as described in the section on Clinical Delivery of the MARA with the following exceptions:

1. The upper elbows and the lower crowns usually are not be attached until upper expansion is complete. However this is not always the case. Some clinicians will start forward advancement during expansion, but the elbows will have a difficult time being engaged behind the lower arms when the upper molar is too narrow (see illustration).



2. Before cementing make sure that all the orifices in the expander, large square tubes and archwire tubes are filled with toothpaste or wax to keep out glass ionomer. *(If using wax, be careful not to get the wax on the inside of a crown.)*



Expander MARA ready for cementation.

## Post Insertion Instructions

Expanders are usually turned several times before the patient leaves the office. The assistant makes the first turn of the expander with the parent watching. Then the parent should turn it. This ensures that the parent is turning it correctly. If upper and lower expanders are present, review the procedure for both. The frequency and amount of turns and amount of time required for maximum expansion depends on:

1. The maximum expansion allowed by the screw.
2. The number of turns required to fully open the screw. (Because of the variations in design, follow the manufacturer's guidelines or ask the laboratory to provide the information pertaining to the expander.)
3. The expansion desired for the patient.

Schedule the patient to be seen in four weeks to check if expansion is complete.

## Completion of Expansion and Continuation of MARA Therapy

Once the maxilla is expanded to the width desired:

1. Cut the expander off the appliance. Due to hygiene considerations it is prudent to remove the expander as soon as possible. A palatal arch is not needed to hold the expansion, because the elbows will hold the arch and keep the expansion from relapsing.
2. Cement the mandibular crowns if they had not been placed at the same time as the maxillary appliance.
3. Attach the upper elbows and advance as prescribed.
4. Schedule bracket placement if applicable.

### **Mandibular Arch**

Completion of mandibular expansion usually occurs before placement of the lower MARA. Once lower expansion is completed, it should be retained with a lingual arch or lower braces. *(When the lower arch has been expanded, it is recommended that a new lower MARA be fabricated with a lingual arch.)*

## Treatment Sequence and MARA Activation

Treatment protocols are different, depending on the treatment philosophy and mechanics being used by the clinician. Some clinicians prefer to expand the arches first (many skeletal Class II malocclusions require maxillary and/or in some cases mandibular expansion), correct the AP with the MARA and then place brackets on Class I cases. Others like to incorporate the expanders into the MARA, expand their patients and then continue their treatment plan: correcting rotations, aligning and leveling the arches.

When brackets are used in conjunction with the MARA, they are usually placed sometime during the first ten weeks after insertion of the MARA to begin combined treatment mechanics and/or to:

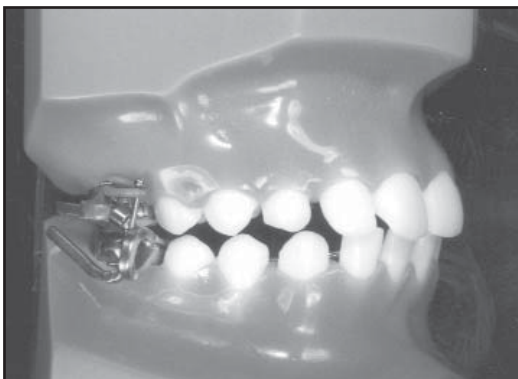1. You can prevent the upper molars from distalizing by placing an upper 2x4 appliance to tie the upper arch together. This will encourage more of an orthopedic effect on the maxilla, but it will cause a downward and backward rotation of the maxilla which will increase face height and reduce chin projection. It is usually better to let the upper molars distalize and to continue to shim the upper elbows forward to maintain end to end incisors.

2. Prevent distal tipping of the upper molars by placing a heavy rectangular archwire.

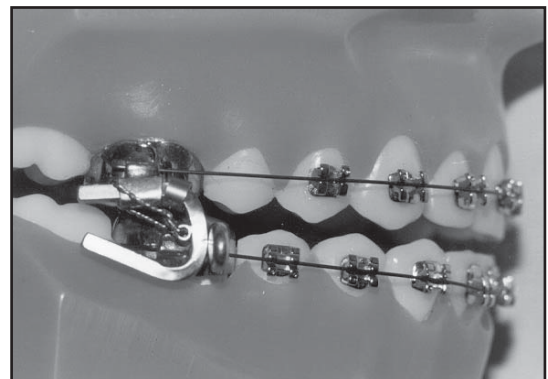
**Note:** Occlusal rests are also incorporated into the MARA design if this is a concern. However, because there is no vertical force as with the Herbst, tipping is usually minimal except in adults where the absence of growth encourages tipping.

3. Counter the possible protruding effect of the MARA on the lower incisors, which has been reported on the average to be less than 1mm. Also, the lower molars must be stabilized with a lingual arch and possibly lower braces. If only a lingual arch is used, some minor incisor proclination will occur, which can be countered after MARA therapy  
or by placing brackets (*negative -5 to -10 degree torque*) on the incisors in conjunction with the MARA.

**Pearl:** If orthodontic appliances are going to be used with the MARA, *it is important not to place brackets on the upper second bicuspids*, as they may interfere with elbow insertion. It is sometimes preferable to use a segmented archwire in the upper arch.

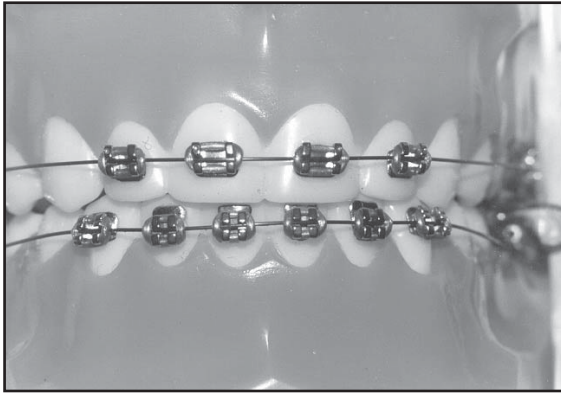


**Basic MARA has lingual arch.**  
(Shown with new elbow design).

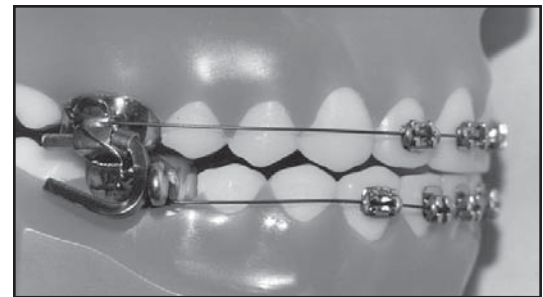



**MARA with brackets.**  
(Earlier version of elbow)

MARA therapy usually takes 12-15 months but can be shorter or longer depending on the severity of the Class II being corrected and the age of the patient. The appliance is activated two to four times during treatment. Clinicians will activate the MARA approximately every 12-16 weeks and in increments of 2-3mm, achieving and then maintaining an edge-to-edge relationship.



**Patient ready for first activation of MARA. Bite has deepened and needs advancement shims placed to move mandible forward.**



**First activation of MARA completed. (Earlier version of elbow)**

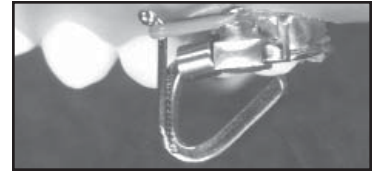
**Note:** The goal is to advance the incisors to end-to-end incisal relationship. As with the Herbst, overcorrection with the MARA is necessary due to an anticipated relapse of 10-20% caused by muscle pull and remodeling in the posterior glenoid fossa.

1. A medium 4-5mm Class II can usually be advanced the entire 4-5mm initially. This position will be maintained by adding the appropriate shims/bushings to the upper elbows keeping the patient in the end-to-end incisal relationship throughout MARA therapy.
2. A severe 8-9mm Class II should be advanced only half way (4-5mm) when the appliance is fabricated and held there for 6 months. Because relapse may occur shims/bushings may have to be added to the upper elbows to maintain the initial 4-5mm advancement during the first 6 month period of MARA therapy. Then advance the remaining distance to end-to-end incisal relationship and hold there for the next 6 months or until the end of MARA therapy. Once again, shims/bushings may need to be added during this time to maintain the advancement.

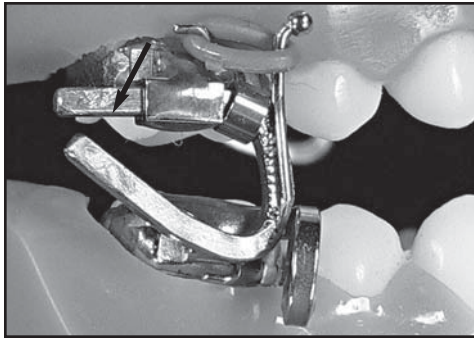
*If the patient has difficulty tolerating the initial advancement reduce the advancement and let them get used to it. At the next appointment (12 - 16 weeks later) add shims bringing the patient forward as initially desired.*

## Activating or Advancing the MARA


**Step 1.** Remove elbows by slipping the elastic separator off the ball hook and cut ligature wire if one is present.



- a. If the distal extension of the upper elbow is long enough simply add the advancement shims to the anterior part of the horizontal leg of the upper elbow, re-check the advancement as well as the midlines. If the midline is off correct by replacing a shim of the appropriate length to re-align.



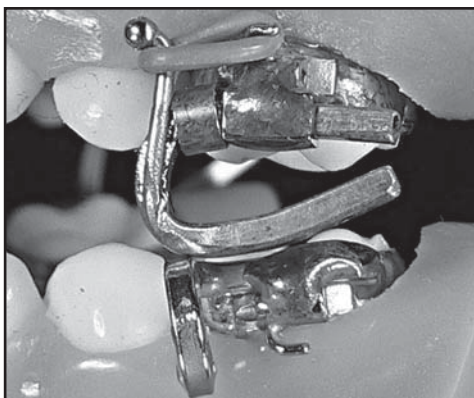
Elbow distal extension of horizontal leg long enough to support advancement.



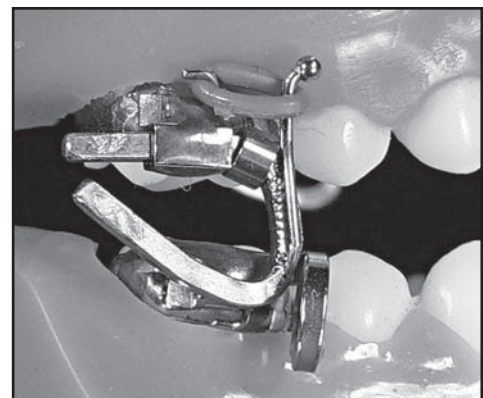
MARA advanced by placing shim on the existing upper elbow.

- b. Check the vertical leg of the upper elbow. If it is too short, place new longer elbows and place the appropriate size shims/bushings over the anterior portion of the horizontal leg to achieve the desired advancement. *The elbows must be tall enough in their vertical leg that the patient can open a few millimeters before escaping the mandibular lower arm. This holds the mandible forward even when relaxing.*

**Note:** When replacing upper elbows follow the instructions as described in the *Delivery of MARA, Clinical Insertion, Step 5, Section b, p. 31.*



Upper elbow w/7mm vertical leg is too short. Engagement easily lost.

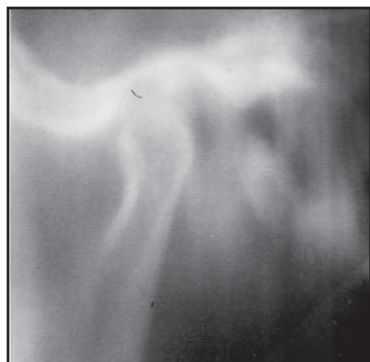


Upper elbow replaced w/10mm vertical leg to correct. Engagement maintained.

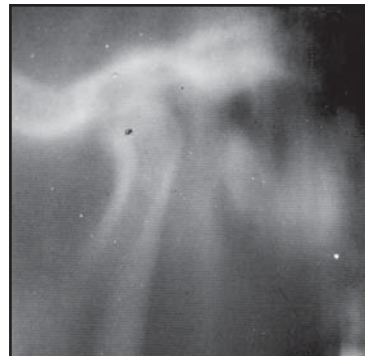
**Step 2.** After adjustments and patient is functioning correctly, tie the upper elbows in using a heavy separating elastic. An .014 ligature wire may be used as added stability if the elbow seems to wobble. For patient comfort it is suggested that the ligature wire be tied on first and then place the separator over it. (See top photo new elbow design).

## Determining When to Remove the MARA

Treatment time with the MARA typically takes about a year but the determining factor for many clinicians is when the tomogram or transcranial x-ray shows that the Temporal Mandibular Joint has remodeled and the condyle is reasonably centered in the fossa. Getting to this point may take up to 24 months, depending on the severity of the Class II correction and age of the patient.

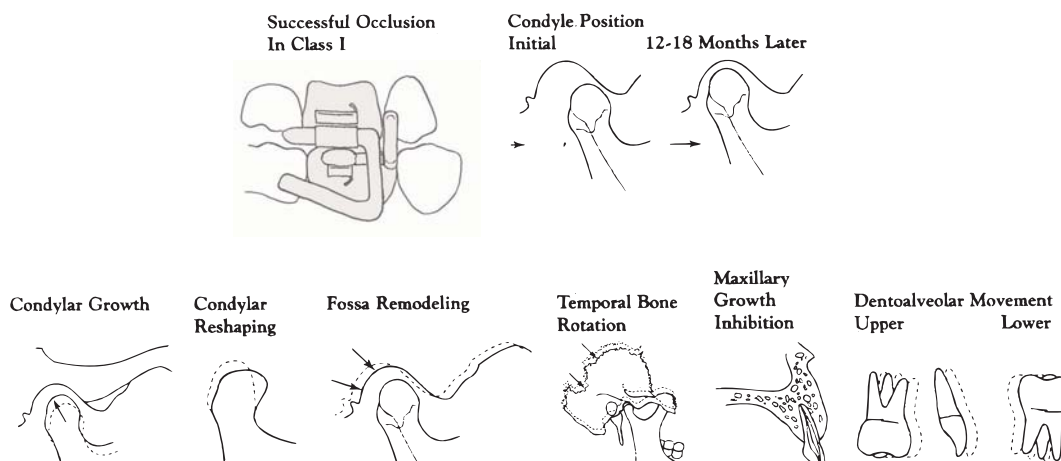


Condyle not centered in fossa.



Condyle centered in fossa.

### Review of Changes Produced by the MARA Over the Course of Treatment



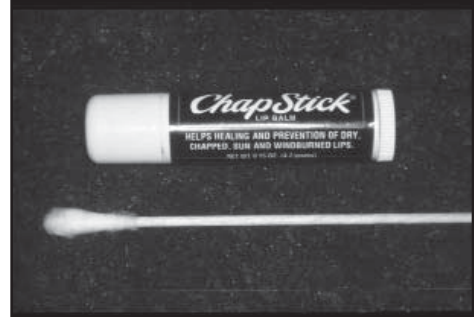**Note:** If tomograms or transcranials are not available, a guide to determine the end of MARA therapy is when the patient has the ability to protrude the mandible 8-13mm beyond end-to-end incisors.

**Pearl:** When it is determined that the patient is ready to be rescheduled for MARA removal and will be continuing with edgewise finishing treatment, it is advantageous from a production/scheduling standpoint to place separators (5's and 7's) at this time. At the next visit, remove the appliance, fit and cement posterior bands and bond the teeth as indicated. This sequence will save several appointments.

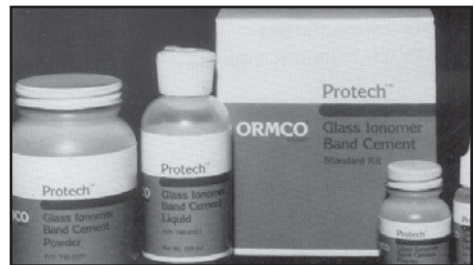
# Removal of the MARA

Before discussing the current removal techniques, let's reflect back on where the removal procedure actually begins. Crown removal actually starts prior to cementation of the MARA.

1. If occlusal removal holes are not present in the crowns, using Vaseline or Chapstick on the dried occlusal surface of the molars will prevent the glass ionomer cement from forming a bond down in the occlusal grooves, which makes removal difficult.



2. Utilizing a tinted glass ionomer such as ProTech Gold (Ormco) helps to distinguish the cement from the tooth enamel when cutting into the crowns and when cleaning off cement.




3. Placement of a horizontal slit to be used in conjunction with an occlusal removal hole later affords a purchase point necessary to accommodate certain styles of crown removal pliers.





**Horizontal slit.**

4. Placing a vertical notch in the crown before delivery of the appliance simplifies the removal procedure by eliminating the need to use a bur subgingivally if the crowns are to be sectioned and if a crown splitter plier is to be used.



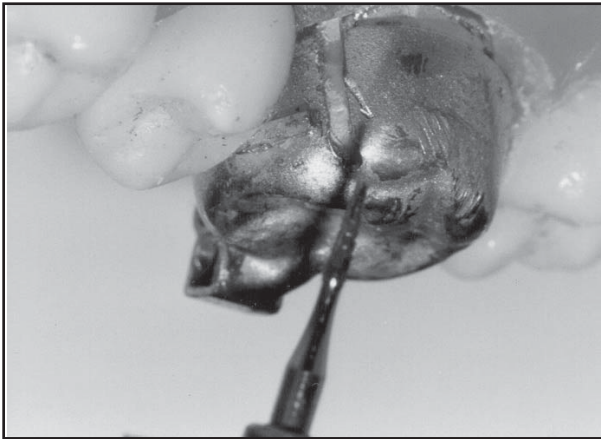
**Vertical notch.**



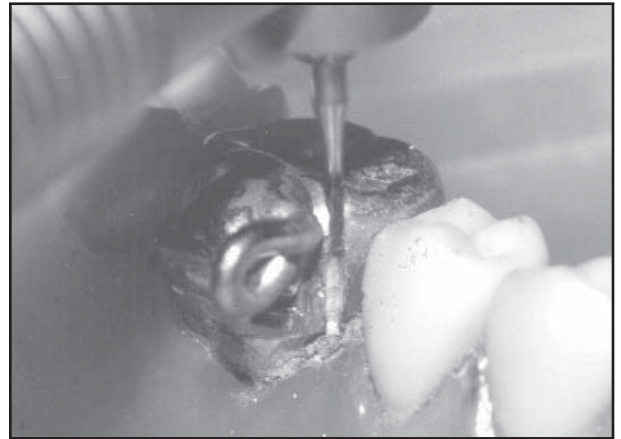**Crown Splitter.**

## Crown Removal Cutting Technique

- Step 1.** Place a topical anesthetic on the gingival tissue in the areas where the crowns are to be cut.
- Step 2.** If applicable, remove the composite material from occlusal rests freeing them from the teeth.
- Step 3.** Using a bur, cut the crowns occlusally and down to the mesial gingival margin. On the upper crowns, make the cut occlusally and down the mesiopalatal cusp gingival margin. On the lower crowns, make the cut occlusally and down the mesiobuccal cusp.




Maxillary crown cut.

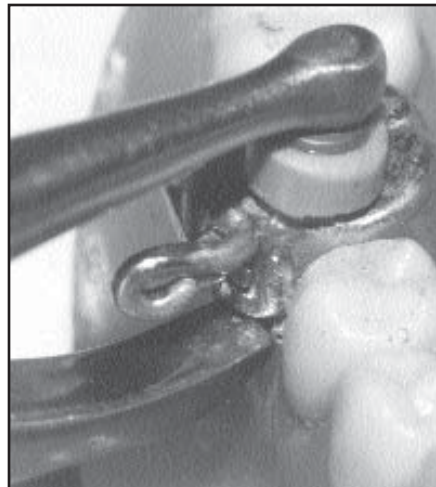


Mandibular crown cut.

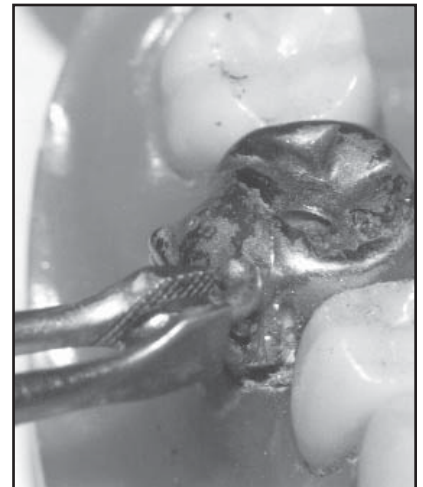- Step 4.** The crowns are then removed using crown or band removing pliers along with a rocking and peeling motion utilizing the attached upper elbows and lower arm for leverage. A band seating plier can also be used to grab the lower arm to assist in removal of the crown.



Cut maxillary crown removed with a band removing plier.



Cut mandibular crown removed with a band removing plier.




Mandibular crown removed with band seating plier.

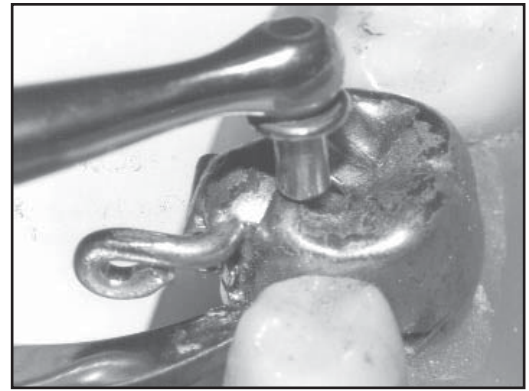

## Crown Removing Plier Technique

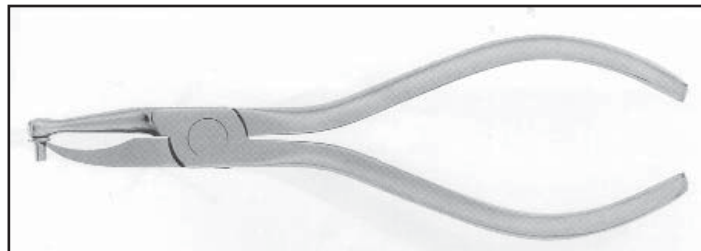
- Step 1.** Place a topical anesthetic on the gingival tissue in the areas where the crowns are to be removed.
- Step 2.** If applicable, remove the composite material from occlusal rests freeing them from the teeth.
- Step 3.** Find or place a crown removal hole 2-4mm in diameter in the occlusal surface of the crowns. Place the post of the plier into the occlusal hole and slide the lower beak of the plier into the horizontal slit of the crown for the upper and under the buccal arm on the lower. Apply pressure and the crown will snap off. (It is not necessary to remove the upper elbows prior to crown removal.)



Maxillary crown removed with crown removing plier.



Mandibular crown removed with crown removing plier.



Chastant (AEZ) crown removing plier.

**Pearl:** On the upper crown a horizontal slit may be placed on the mesial lingual corner to act as a purchase point for the plier. *Many crowns are slightly sub-gingival and accessing the edge of it could be uncomfortable for the patient.* The purchase point should be halfway from the gumline to the occlusal.



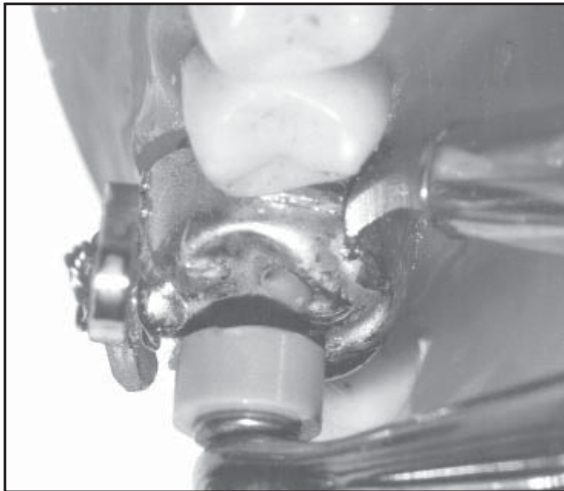
Maxillary crown with horizontal slit and occlusal removal hole.

# Crown Slitting Plier Technique

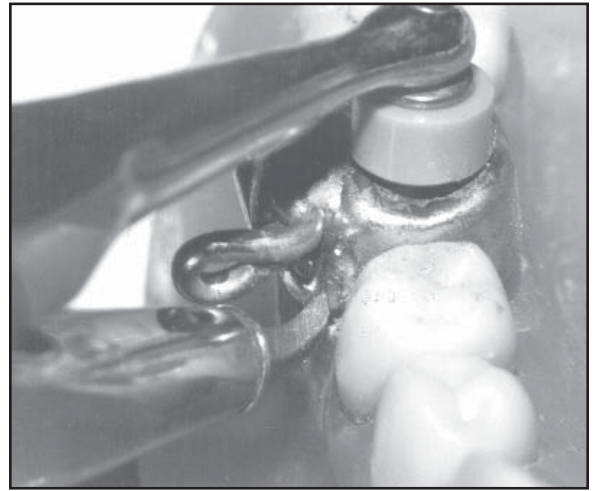
- Step 1.** Place a topical anesthetic on the gingival tissue in the areas where the crowns are to be removed.
- Step 2.** If applicable, remove the composite material from occlusal rests freeing them from the teeth.
- Step 3.** Find the vertical removal notch previously created at the mesial gingival corner and engage the blade of the crown slitting plier into the removal notch and the pad of the plier on the occlusal surface of the crown. The plier should be held at a slight angle to the occlusal plane.

Maxillary crown -- hold the slitter slightly below the occlusal plane.  
Mandibular crown -- hold the slitter slightly above the occlusal plane.


This slight angling enhances attack of the point and blade of the slitter keeping the point riding underneath the crown in an occlusal direction. As slitting occurs, the width of the blade forces the crown apart and the crown is easily removed. The crown usually comes off in the jaws of the slitter, or is aided by peeling the crown from the tooth. (Leave elbows attached to crowns for leverage).



**Maxillary crown removed with crown slitting plier.**



**Mandibular crown being removed with crown slitting plier.**

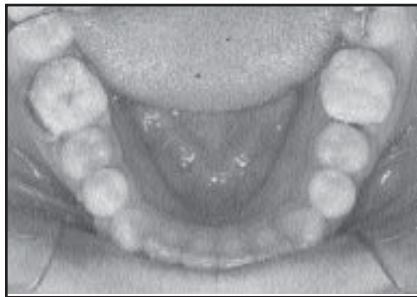

**Crown slitting (AEZ) plier.**

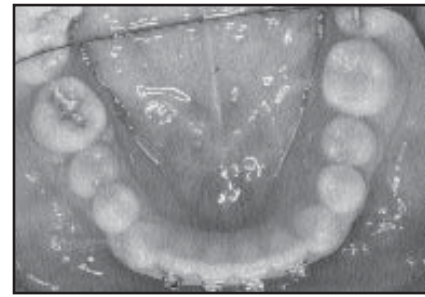
## Cement Removal

As discussed earlier, simplifying the removal of the cement started with cementation. If Vaseline or Chapstick was used on the occlusal surface of the tooth prior to cementation, most of the cement will have remained in the crown when removed. This occurs for two reasons: First, the crown was microetched enhancing adhesion inside the crown and secondly, Vaseline/Chapstick forms a barrier or shield between the tooth surface and cement in the occlusal grooves. If these shields were not applied, or a removal/vent hole was incorporated during fabrication, which preclude the use of a shield, the cement will remain adhered to the occlusal grooves, making cleanup slightly more time consuming.

- Step 1.** Place lip retractors for a clear working field.
- Step 2.** Dry the cement with a tooth dryer. This will help to break the cement away from the tooth.
- Step 3.** Use an ETM #800-3490 (Ormco) bond removal pliers to break away as much of the cement as possible.
- Step 4:** Use a bur similar to the type used to remove bonding material in a slow-speed or a high-speed polishing hand piece to finish the cleanup.



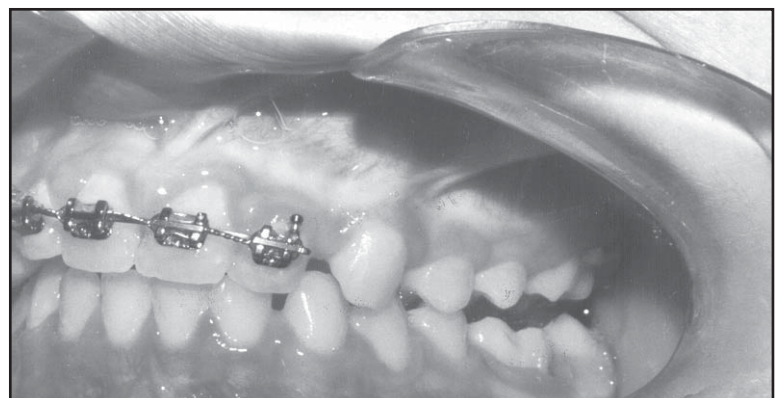Lower molars needing cleanup.



Cleaned up. Note unwanted rotation of lower right 1st molar.

**Pearl:** There is plenty of space between the molars and premolars when the crowns are removed. This is a good time to place posterior bands and bond the teeth as indicated. This sequence will save several appointments.

**Note:** Depending on the mechanics used during MARA therapy, you may notice that the first molars are intruded from having the crowns between the occlusion, but they will be elevated when brackets and archwires are placed. This problem usually disappears during full treatment. However, if not, the patient can wear light vertical elastics.

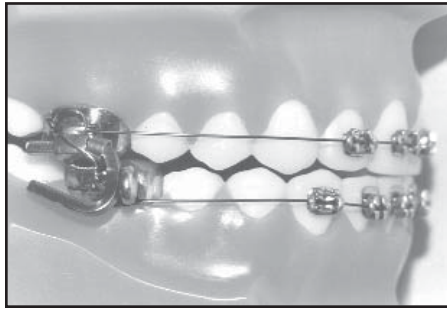


Posterior open bite after removing MARA crowns.

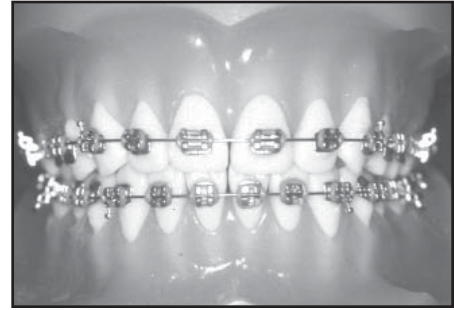# Continuation of Orthodontic Treatment

Finalization of the occlusion is determined by a number of factors, such as whether or not orthodontic mechanics were utilized by the clinician during MARA therapy.

Some clinicians like to use brackets to control the torque of the teeth and to level and align the teeth during MARA treatment. When the Class II is corrected and the MARA is removed, the rest of the teeth are then banded or bracketed to finish detailing the occlusion.

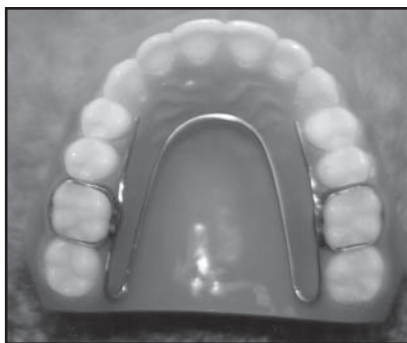


**MARA with brackets.  
(Old elbow design)**

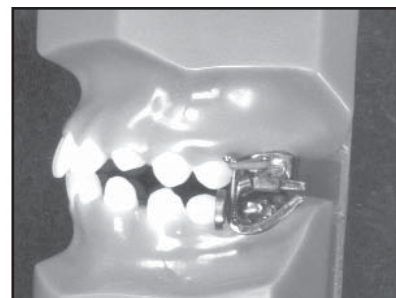

Another philosophy is to simplify the correction of Class II cases by completing the patient's treatment in phases:

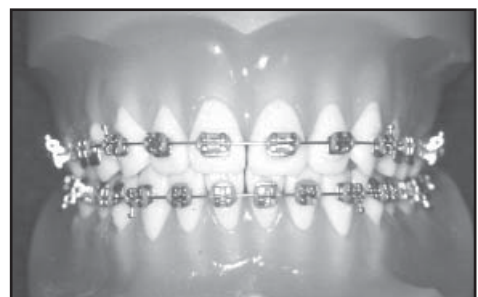
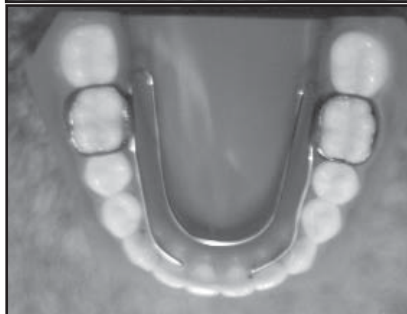1. Expand the upper and/or lower arches.
2. Correct the AP with MARA therapy.
3. Remove the MARA appliance.
4. Place brackets on uncrowded Class I cases.



**1. Expansion of arches.**



**2. Correction of AP with MARA.**



**3. Finishing with brackets in  
uncrowded Class I.**

# Appendix

## Supply List for MARA Treatment

### **MARA Demonstration Appliances for Consultation**

AOA Laboratory, 800-262-5221 or 262-886-1050.

Two tone models on appropriate malocclusion.

**MARA Accessory Kit** includes assorted elbow sizes, shims of various lengths (1-5mm) and torquing tool. Elbows, shims and torquing tools may be purchased separately.

**MARA Crown Components** are available with pre-soldered MARA buccal attachments (upper tubes and lower arms. Crowns come in size 4,5,6,7 the most common sizes used. An inventory storage box is also available.

### **Ormco Crowns and Ormco Crown Fit Kit**

Ormco representative: 800-854-1741. Or AOA when furnishing crowns during fabrication.

### **Pliers: (AEZ and ETM)**

Ormco, or your Ormco representative: 800-854-1741.

#### **AEZ**

Band removing plier #803-0609

Band seating plier #803-0123

Crown contouring plier #800-0160

Crown removal plier (Chastant) #803-0610

Crown slitting plier # 803-0430

Tweed plier #803-0125

#### **ETM**

Bond remover plier #800-3490

#### **Miscellaneous:**

Mathieu plier #801-0064

Small beak 3 prong plier

How plier

Weingart utility plier

#### **Glass Ionomer**

Ormco representative: 800-845-1741.

ProTech Gold: Introductory Kit #740-0255    Standard Kit #740-0256

#### **Allwrap for use over cold mixing slabs**

Local dental supply company.

#### **Negative Torque Lower Incisor Brackets**

Ormco representative: 800-854-1741.

Orthos Prescription: Negative -5 and -10 degree Torque available.

*Negative torque incisal brackets are also available in the Mini-Diamond line.*

## Suggested Reading List:

Eckhart, James E.: The MARA Appliance. AOAppliances, etc., (AOA) Allesee Orthodontic Appliances in Partnership With Your Practice, Volume 1, Number 1, 1997.

Eckhart, James E.: Introducing the MARA. Clinical Impressions, Ormco, Volume 7, Number 3, 1998.

Simon, Eugene, Haerian, Andre.: Efficient Treatment by Design: Using the MARA for Class II's. AOAppliances, etc., (AOA) Allesee Orthodontic Appliances, Volume 5, Number 1, 2001.

Eckhart, James E.: MARA Provides Effective Adult Treatment. Clinical Impressions, Ormco, Volume 10, Number 1, 2001.

Rondeau, Brock.: MARA Appliance. The Functional Orthodontist, A Journal of Functional Jaw Orthopedics, Volume 19, Number 2, Summer 2002.

Eckhart, James E.: The e-MARA. AOAppliances, etc., (AOA) Allesee Orthodontic Appliances, Volume 7, Issue 1, 2003.

Kulbersh.: MARA Article. American Journal of Orthodontics & Dentofacial Orthopedics, Volume 123, Number 3, March 2003.

Eckhart - White.: Class II Therapy with the Mandibular Anterior Repositioning Appliance. World Journal of Orthodontics, Volume 4, Number 2, 2003

Eckhart, James E.: Using the MARA to Correct Class II's in Adults. AOAppliances, etc., (AOA) Allesee Orthodontic Appliances, Volume 8, Issue 1, 2004.

Eckhart, James E.: MARA User's Newsletter, April 1, 2004.

Allesee Orthodontic Appliances (AOA), MARA Mandibular Anterior Repositioning Appliance, Lit. #001.314 Rev. A.

Eckhart, James E.: Updating the MARA, AOAppliances, etc., (AOA) Allesee Orthodontic Appliances, Volume 8, Issue 2, 2004.

Eckhart, James E.: MARA Modification. Clinical Impressions, Ormco, Volume 14, Number 1, 2005

# Common Questions and Troubleshooting the MARA

(A discussion with Dr. James Eckhart)

## Regarding How It Works

### How does it work?

When the patient tries to bite in Class II the lower arms interfere with closing, and the patient can only close in Class I. The patient must bite forward in front of the upper elbow. He/she is guided to habitually hold the jaw in Class I.

### What changes does it produce? Orthopedic? Orthodontic?

Remodeling similar to the Herbst except less vertical effect on the teeth.

Lower teeth move forward a little, lower incisors procline a little.

Upper teeth move backward a little.

Mandible (condyle) grows forward a little.

Maxilla growth is slightly restrained.

Glenoid fossa may remodel forward.

Temporal bone may rotate forward.

### What differences occur between high & low angle cases?

High angle cases may get more vertical face height increase as the Class II is corrected unless some steps are taken to prevent it, such as wearing a cervical collar at night. A cervical collar is similar in concept to the "Milwaukee Brace" neck brace, but is more familiar to us as the neck collar worn by automobile whiplash victims, and is worn at night to apply an upward pressure under the mandible, keeping the teeth in occlusion to prevent their extruding and lengthening the face in high angle cases. It may be obtained from Darby Medical at 800-448--7323, item # 3770300.

### What ages does the MARA work on?

It is a difficult appliance to use in the early mixed dentition because there is insufficient room in the cheek area. Some doctors attach this appliance to deciduous second molar teeth, but most wait and attach it to the permanent first molars. Late mixed dentition all the way through advanced adulthood is appropriate. Adults are capable of tremendous remodeling.

### How complicated is it to learn?

Clinicians and staff with Herbst experience seem to immediately recognize that the MARA is much simpler.

### What cases work the best with the MARA?

Brachyfacial (low angle) deepbite Class II cases work best.

### What is the typical treatment sequence?

1. Expand upper and lower arches if necessary
2. MARA
3. Braces

### **How stable is the Class II correction?**

As with the Herbst, overcorrection is necessary due to 10-20% relapse caused by backward muscle pull and remodeling in the posterior glenoid fossa. For this reason we treat to end-to-end incisors.

### **What cautions are necessary for case selection?**

1. Both the patient and the parents must have sufficient hardiness to overcome the first week. They must be trusting and not have been talked into the appliance if they resist the idea.
2. If there is an anterior open bite, the MARA will make it seem worse at first if occlusal coverage crowns are used.
3. There must be sufficient space in the back of the mouth, or else the arms will have to be cantilevered forward.
4. The permanent first molars must be well erupted with no distal operculum.

### **If a patient is only Class II on one side, can you use the MARA?**

Yes, place it bilaterally and center the midlines. It has been done and it worked well.

### **Can you use the MARA in bruxers?**

Yes, usually a patient will stop bruxing if the mandible is forward.

### **Can you treat an extraction case with the MARA?**

Yes and it is not very difficult.

### **Can a mutilated case be treated with the MARA?**

Yes, AOA can custom-make the appliance if sufficient teeth remain.

### **What are the specific indications for the MARA?**

1. You want to advance the mandible (children).
2. You want to avoid mandibular advancement surgery (adults) yet correct a Class II.

## **Regarding Delivery and Adjustments of the MARA**

### **Do you take TMJ tomograms before advancing the mandible?**

Yes, so you will know what position the condyles should return to before removing MARA.

### **What if I do not have access to a tomographic machine?**

Transcranial x-rays can image the condyle relative to the fossa. TMJ oriented panorex's may be of some value.



**Does the lower arm buccal projection bother the cheek?**

Not unless it sticks out too far. When the mouth is closed, the upper elbow shields the cheek from the lower arm. The lower arm must extend 1-2mm wider than the elbows in order to function when the patient attempts to close in Class II. The in-out profile of the lower arm is adjustable before cementation, using a bird beak and small beak 3-prong plier extraorally. There is a buccal shield (Simon Shield) variation for the lower arm which AOA can fabricate for you.

**In fitting the crowns, do the gingival margins need trimming?**

Rarely if using the Ormco crown. If using the 3M crown some trimming may be necessary. But with any crown you sometimes need to crimp in the gingival margins for added retention.

**Is it necessary to grind or do a crown prep on the first molars?**

No; stainless steel crowns are fitted over the unprepped teeth. *Occasionally a large cusp of Carabelli needs to be reduced.*

**How much do you advance the mandible at first?**

The goal is eventually to advance the incisors to end-to-end incisors, overcorrecting because some relapse is expected. A medium 4-5mm Class II can be advanced this far all at once, but the patient may adapt to the appliance better and break it less if only 2mm advancements are done at a time, 8 weeks apart. A severe 8-9mm Class II could be advanced half way (4-5mm) at first and held there for 6 months, and then advanced the remaining distance to end-to-end incisors and held there for at least another 6 months, or could be advanced in just 2mm increments from the start, until overcorrected. The gradual approach is less likely to overtax the ability of the appliance. Either approach is likely to require replacing the elbows as longer ones are likely to become necessary.

**How do you make subsequent advancements to the mandible?**

The upper elbows slide back and forth in their large square tubes. Their forward position is governed by shims slid onto the anterior part of their horizontal leg. Once they are shimmed they are tied with separator elastics or ligatures. The shimmed elbows engage the lower arms and hold the mandible forward. Midway through treatment it may be necessary to change to elbows with longer horizontal legs for greater advancement.

**What adjustments of the elbows are important?**

The elbows need to be torqued in close to the lower crowns in order to prevent the patient biting inside the elbows when retruding the mandible into Class II, but not so close that they hit the lower buccal surface in Class I, preventing closure. Torque adjustments are done outside the mouth using the torquing tool provided.

The elbows should not extend too far distally to where they poke the cheeks (neither the horizontal leg nor the sweepback leg).

The elbows must extend far enough distally so that the patient cannot bite behind the sweepback legs, and so that the elbow can be advanced by a shim in a few months.

The elbow sweepback leg must be adjusted in its in-out position with a three prong plier so that it is comfortable to the lower gums and the cheek. Bending the sweepback leg to nearly touch the horizontal leg and to be approximately the same length enables the two legs to shield each other and avoid cheek irritation.

The elbows must be tall enough in their vertical leg that the patient can open a few millimeters before escaping the lower arm. This holds the mandible forward even when relaxing.

## **What Problems May the Patient Experience?**

### **What problems do patients have with the MARA's bulk?**

If the lower arm extends more than 2mm buccal to the upper elbow, cheek sores are likely. If the upper elbow extend too far distally or the patient is too young, cheek sores are likely. On younger children using the E's for anchorage and adding the "Simon Shield" to the lower arm can make the appliance more comfortable.

### **Does the MARA take getting used to?**

It takes about a week to get used to it. Common problems include initial cheek biting until the patient learns to avoid it, and cheek puffiness, which can be minimized by placing cotton over the arms while sleeping and by warm salt water rinses.

Chewing is difficult for a few days, and soft foods should be suggested: If requested, AOA can provide a printed patient handout , telling the patient what to expect and how to handle things that come up.

### **What can go wrong with the MARA?**

A. The patient may get the elbow locked onto the lower arm.

Getting the lower arm locked inside the elbow happens because the lower arm is not long enough (not wide enough) or has too small a radius of curvature allowing it to wedge into the interior of the elbow, or because the upper elbow is not torqued lingually tight enough, or because the elbow sweepback leg is too short and not bent up enough to prevent entry of the lower arm from the distal. The problem has been eliminated by making the lower arm loop taller than the interior of the elbow so it will not fit inside.

B. The patient may fail to bite in Class I, but hold the mouth open and retruded, possibly even biting behind the elbow.

The MARA U, with the lower arms curling upward, prevents this. Also, this is avoided by making the vertical leg of the elbow long enough to stay engaged while opening. In addition, the sweepback legs of the elbows must not be so short that they allow biting behind, and the mandible must not be advanced too far in one jump.

C. If the maxilla is not wide enough, the upper elbows have difficulty staying engaged with the lower arms because they are torqued buccally too much and do not have enough vertical engagement.

The solution is to make sure the upper molars are wide enough before placing the MARA.

D. If the lower molars are not stabilized with a lower lingual arch, they may rotate mesiolingually so much that the upper elbows can no longer stay engaged behind them.

### **Do TMJ symptoms occur from the advancement?**

No; in fact frequently the MARA is used to relieve TMJ symptoms, and is useful to recapture anteriorly displaced discs and to unload the joint.

### **Does the occlusal coverage of the crowns cause any TMJ symptoms?**

If you are concerned about this you can grind out the occlusal coverage of the crowns before cementation. There is still a strength benefit from using a crown vs a band.

### **Must the lower molars be stabilized during MARA treatment?**

Yes, they must be prevented from moving mesially and crowding out the second bicuspid, and they must be prevented from mesial-lingual rotation. These movements are caused by pressure from the upper elbows. The solution is a lingual arch.

### **How do I avoid unfavorable results?**

1. Don't treat patients too young.
2. Don't advance severe cases too much at a time.
3. Hold long enough.
4. Don't persist with children who break it a lot.
5. Counsel children on what is expected of them.
6. Read MARA articles, and read this manual.

### **What breakage can be seen?**

The patients sometimes lose elbows. For this reason you need to keep spare parts.

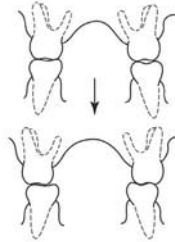
Certain patients who retrude the mandible and bang on the arms in the open mouth position will knock crowns loose, break solder joints, and either intrude or cause loose lower molar teeth. They need strong instruction on where to hold their jaw, and if they continue to ignore instructions, should be discontinued on the MARA.

## Regarding Clinical Management of the MARA

### What must be done prior to placing the MARA?

The upper incisors should be uncrowded, properly torqued, and intruded if necessary, so they can serve as references to where the lower incisors are moved.

Make sure the upper molars are wide enough so the upper elbows can hang vertically down outside the lower crowns. An expander can be built into the MARA, but the elbows and lower crowns should not be inserted until the upper crowns are wide enough.



### Do the upper molars need a palatal arch?

Not usually necessary, but OK to use. Prevents swallowing a crown if one comes off, and helps assure that the rotations of the crowns at cementation are as planned in the lab.

### What cement do you use?

I prefer crown MARAs and use a glass ionomer, Protech Gold, fromOrmco. For a banded MARA I would suggest a light cured cement such as Optiband also fromOrmco.

### What tools are necessary for adjusting a MARA?

Torquing the vertical leg of the elbow is done by holding the horizontal leg in a torquing tool provided by AOA, while bending the vertical leg with a utility plier. The torquing tool avoids dinging the corners of the horizontal leg, so it is not damaged and can continue to slide through the square tube. All other bends of the elbows are done with a small beak 3 prong heavy duty plier. How to hold the tools and make appropriate adjustments are illustrated in this manual.

### How do you tie in elbows?

Secure with a twisted ligature, cut and tuck the pigtail under and place the separator elastic over the hooks on top of the ligature wire. This will add stability and be more comfortable for the patient.

### What do you tell patients to expect after delivering the MARA?

AOA provides a nice handout with each case answering these questions. This manual provides detailed instructions which you may use in creating your own patient information sheet. However the highlights would be to (1) caution the patient to avoid banging down on the MARA, to only use it as a guide for where to hold the jaw, (2) eat soft foods for the first few days, biting carefully so as not to pinch the cheeks, (3) and if any parts come loose to bring them with them for reinsertion.

### **How long between appointments?**

Unless there are edgewise appliances needing attention, MARA's can be checked each 3-4 months. If you are advancing the mandible gradually in 2mm increments, you should do that each 8-12 weeks.

### **What changes happen between appointments?**

The incisor overbite may deepen. The Class II may relapse a bit. These changes are probably due to distal movement of the upper molars. Shims may need to be added to the elbows in order to continue advancing the mandible. Longer elbows may be necessary.

### **Can you have braces on at the same time as the MARA?**

Yes. Except do not put brackets on the upper second bicuspids because they interfere with elbow insertion and removal.

If you do not want the upper molars to distalize, place an upper 2X4 appliance to tie the upper arch together. This will encourage more of an orthopedic effect on the maxilla, but it will be a downward and backward rotation of the maxilla which will increase face height and reduce chin projection. It is usually better to let the upper molars distalize and to continue to shim the upper elbows forward to maintain end-to-end incisors.

If you have crooked lower teeth, braces on the lower teeth during the MARA treatment makes sense. Otherwise, it may be simpler to place most of the braces after the MARA is removed.

### **Do the lower incisors dump forward?**

Slightly (less than one would suppose). The lower molars must be stabilized with a lingual arch with or without lower braces. If only a lingual arch is used, the appliance is fairly break-proof and hygiene is easy for the patient, but some incisor proclination will happen. If braces are also used, especially if negative torque lower incisors are used, lower proclination is less likely.

### **Do the upper molars tip distally like with the Herbst?**

Not as much because there is not a vertical vector of force with the MARA. An upper edgewise wire will prevent distal tipping of the upper molars but beware of unwanted occlusal plane tipping down in front. Adults treated with the MARA seem to get more distal tipping of the upper first molars, so occlusal rests extending to the upper second molars are suggested.

### **What if the patient mouth breathes at night and slips back into Class II?**

Try having the patient wear vertical elastics to keep the mouth closed, or you may need new elbows with longer vertical legs. Use the MARA U design with the lower arms curling upward, providing more vertical engagement and greater resistance to disengagement.

### **How long do you leave the MARAs in?**

Until there is x-ray evidence that the condyle is centered again in the fossa. Usually this takes 12-15 months, longer for more severe Class II's and longer for adults. If no x-rays are available, the patient should also have the ability to protrude 8 - 13mm beyond end-to-end incisors.

### **Do you overtreat? How long?**

Some doctors report TMJ tomogram evidence of the condyles being re-centered in the fossa in 8-9 months. Even so, the remodeled bone may be immature and the muscle attachments may not be finished migrating. We recommend leaving the MARA in for 12 months.

### **How long do MARA treatments take?**

Average Class II's are corrected in 12-15 months, followed by 4-8 months of braces. If expansion precedes the MARA, it takes longer. More severe Class II's take longer and adults take longer.

### **Do you see relapse after MARA treatment?**

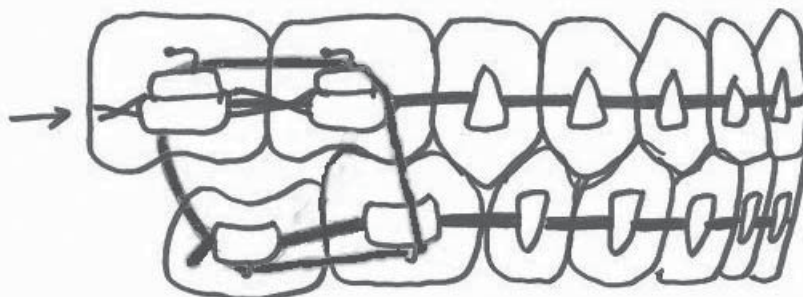
Rarely. As with Herbst treatment, 10 -20% relapse is common, but this is handled by over correction and by leaving the MARA in a full 12-15 months (longer for adults). If the Class II is not overcorrected, Class II elastics may be used during the final 6 months after the MARA is removed if necessary.

### **How do you remove the MARA?**

If you have removal holes in the occlusal of the crowns, they pop off easily with the crown removing plier. Detailed cutting procedures are described in this manual. Half or more of the cement will stick to the crowns if they were microetched before cementation. The remaining cement can be removed with a band removing plier and a high speed polishing bur.

### **Do the molars seem intruded when you remove the MARA?**

Yes, if there were crowns on the molars. They are easily extruded with vertical elastics once bands or brackets are placed on them.





As demand for nonextraction, nonextraction treatment continues to grow, the MARA (Mandibular Anterior Repositioning Appliance) is an increasingly prescribed option for the correction of Class II malocclusions. Experience has taught us that each clinician may require a unique design, as well as experience a reasonable learning curve in the clinical management of the appliance. Should questions arise, we welcome and encourage dialogue between your office and our staff. Please call our Communication Center at (800) 262-5221.

**Paula S. Allen-Noble**

800-990-3485 or 985-727-2985 Fax: 985-727-9801  
E-mail: Allen.Paula@sybrondental.com  
Mandeville, LA (home office)

---

**Max A. Hall**

800-262-5221 or 262-886-1050 fax: 262-886-6879  
E-mail: Hall.Max@sybrondental.com  
Sturtevant, WI (Wisconsin Laboratory)

---

**Copyright 2005 All Rights Reserved**

**MARA U.S. patent #5848891**

*The MARA (Mandibular Anterior Repositioning Appliance) has a U.S. patent issued, and Allesee Orthodontic Appliances is the exclusive licensee to fabricate the MARA and its components.*

**Allesee Orthodontic Appliances**

P.O. Box 725  
13931 Spring Street  
Sturtevant, WI 53177 U.S.A.  
800-262-5221 or 262-886-1050  
Fax: 262-886-6879

**Visit us at our website: [aolab.com](http://aolab.com)**  
**AOA is a subsidiary of Ormco Corporation**



*Subsidiary of Sybron Dental Specialties*

**Communication Center**  
**800-262-5221**

---

**International 262-886-1050**

**AOA Wisconsin**

13931 Spring Street  
Sturtevant, WI 53177  
Fax 262-886-6879

**AOA Connecticut**

6 Niblick Road  
Enfield, CT 06082  
Fax 860-741-7655

**AOA California**

341 E. First Street  
Calexico, CA 92231  
Fax 760-357-9488

---

**[www.aolab.com](http://www.aolab.com)**