

# AOAppliances, etc.

## In This Issue:

- Interproximal Enamel Reduction
- Lingual Case Report
- Damon Retention Splint
- Where to Find AOA This Year

We are introducing our 13<sup>th</sup> edition of AOAppliances, etc. Newsletter – your positive comments and interesting suggestions for future articles is always enjoyable. Please continue to share “pearls” and trust you enjoy this latest edition.

We are proud to introduce Dr. Mike Swartz, Orange, California, who will review techniques commonly used for interproximal (stripping) reduction. With the industries acceptance of Red, White & Blue and Spring Retainers to correct minor irregularities, Dr. Swartz has offered a convenient approach.

Dr. Courtney Gorman, Marion, Indiana, is sharing a case report that was treated lingually utilizing AOA's Class Indirect Bonding service. Dr. Gorman was challenged with alignment, overbite and restorative issues that were handled successfully with lingual treatment.

AOA will be attending the AAO in San Francisco this coming May. We will have a full compliment of appliances to share with you and your staff. Should you be attending, please stop by and say hello.




David Allesee  
General Manager,  
AOA Laboratory



13931 Spring Street, Sturtevant, WI 53177  
800-262-5221 Fax 262-886-6879  
262-886-1050 (International)

6 Niblick Rd, Enfield, CT 06082  
800-826-2224 Fax 860-741-7655  
860-741-3745 (International)

## Interproximal Enamel Reduction

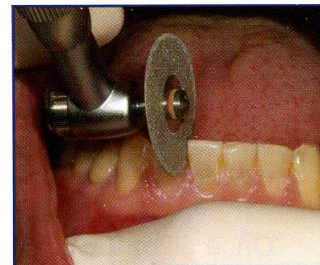

Michael L. Swartz, D.D.S.

The removal of enamel at the interproximal contact areas is a method to gain additional space as well as flatten the contact areas on lower incisors to perhaps achieve some added post-treatment stability.

Termed; *reproximation* or *interproximal enamel reduction* and commonly called *stripping*, *enamel stripping* or


*slenderizing*, it involves the judicious removal of interproximal enamel with carbide or diamond burs, diamond wheels and/or abrasive strips.



Primarily used in the area of the lower incisors with the objectives of gaining arch length, compensating for a tooth size discrepancy (a Bolton discrepancy), correcting tooth shape anomalies or broadening the contact areas to help prevent relapse and improve stability. The primary concerns with this procedure have been the amount of enamel that may be safely removed and the longer term consequences for caries and the periodontal health.

The conclusions reached, in a limited number of published studies, suggest that if a conservative 0.5mm or less of enamel (per surface) is removed, that there is no apparent increase in decay or any significant longer term periodontal health issues.<sup>1,11</sup>

Air rotor stripping (ARS)<sup>III,IV,V</sup> (high speed handpiece with diamond burs) can be differentiated from *reproximation*, *slenderizing*, or *stripping* in that these terms usually refer to the proximal enamel reduction only in the lower incisors. ARS is the technique of removing interproximal enamel in the posterior segments as well, to gain arch length for anterior or posterior crowding. The ARS procedure, versus a conservative reproximation of the lower incisors, is more aggressive and may be considered controversial.



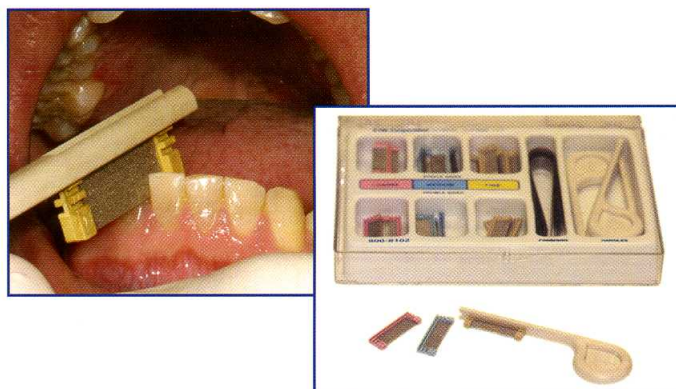
Safe sided diamond disk

Continued on page 2

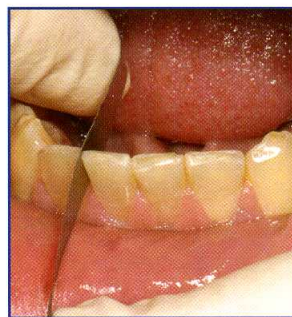Procedures for the reproximation of the lower incisors include the use of slow speed diamond disks, aluminum oxide sanding strips and disks or diamond coated sanding strips. The diamond disk or strip is used for the gross reduction followed by finer grit sanding strips or discs.

Procedures for the reproximation of the lower incisors include the use of slow speed diamond A technique that I have used for many years is to use single-sided diamond wheels on the slow speed handpiece. One set of diamond wheels is placed on the latch-type mandrel with the safe-side out, another set with the safe-side facing toward the handpiece. One is used on all the left facing surfaces and the other on the right facing surfaces. Using a safe sided disk provides more precise control of the grinding surface as with crowded teeth the adjacent tooth may be rotated relative to the wheel. Mounting the wheels in opposite directions allows you to always rotate the disk in the same direction and thus prevent the mandrel from un-screwing. Place the forefinger and thumb on the labial and lingual of the teeth to prevent cutting the lip or tongue.

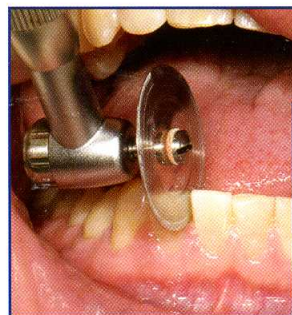

Once all of the surfaces have been reduced with the diamond wheel, the proximal surfaces are smoothed with sandpaper strips or disks. Ensure that in the process the reduced proximal surfaces are at right angles to the labial and that no ledge has been created.



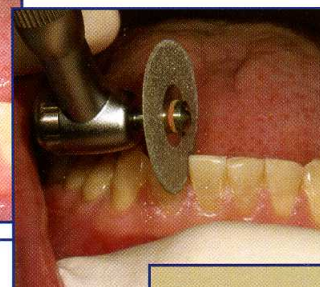
**Double sided and safe side strips-  
Interproximal Stripper Kit, Ormco #800-8102**



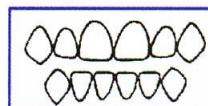
**Diamond coated metal strip**



**Single-sided diamond wheel on the slow speed handpiece.**



**Typical format for resetting and stripping on AOA Rx forms**



- Leave space:  
Mesial \_\_\_\_\_ Distal \_\_\_\_\_
- Reset Ideal - Call if not Feasible
  - Partial Correction - No Call Needed
  - Strip as Needed
  - Do Not Strip
  - Strip where Indicated on Diagram
  - Contacts already stripped

1. Radlanski, R.J., Jager, A., Schweska, R., Bertzbach, F., Plaque accumulations caused by interdental stripping. Am J Orthod Dentofac Orthop 1988;94:416-20.
2. Radlanski, R.J., Jager, A., Zimmer, B. Morphology of interdentally stripped enamel one year after treatment. J Clin Orthod 1989;23:748-50.
3. Sheridan, J.J. Air-rotor stripping. J Clin Orthod 1985;19:43-59.
4. Sheridan, J.J. Air-rotor stripping update. J Clin Orthod 1987;21:781-8.
5. Crain, G., Sheridan, J.J., Susceptibility of caries and periodontal disease after air-rotor stripping. J Clin Orthod 1990;24:84-5.

# Lingual Case Report

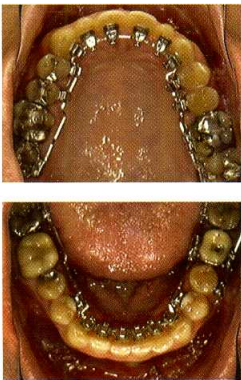


Dr. Courtney Gorman, D.D.S., M.S.

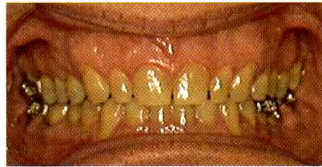The patient a 43-year-old male presented with a severe deep bite, full step Class II left and Class I right. The mandibular left first molar was missing and an implant had been placed but not restored. The maxillary dentition was severely worn incisally, occlusally, and lingually. The mandibular dentition was worn both occlusally and incisally. No third molars were present.

The treatment plan was to bond both arches with lingual appliances and level and align. During this phase the implant would be temporarily restored and used as anchorage for Class II correction with elastics. Major concerns included excessive loading of the implant and over correction of the facial midline. There were also concerns with successful bonding of the maxillary anteriors due to the excessive enamel wear and dentin exposure.

Models were sent to **AOA laboratories** and a CLASS setup was requested with over correction of the rotation in the maxillary left lateral, and over correction of the deep bite mainly thru intrusion of the mandibular incisors.



All teeth were initially bonded. The brackets were pre-treated with Ortho Solo ten minutes prior to bonding. The dental arches were isolated and etched for 20-30 seconds with liquid etching solution containing 35% Phosphoric acid. The teeth were then rinsed and dried and a thin coat of Ortho Solo was applied to enhance the bond strength to the exposed dentin. A very small amount of restorative material was placed on each bracket. The trays were seated and light cured for 20 seconds per tooth. After all brackets were bonded the trays were removed and the initial arch wires, 17x17 Cu Niti's were placed.



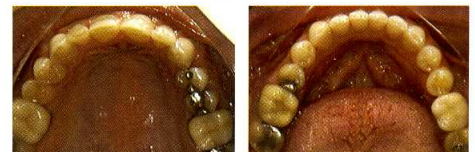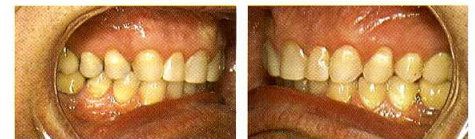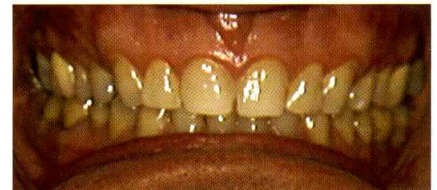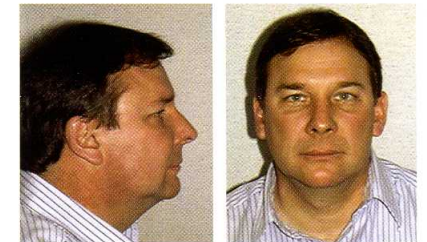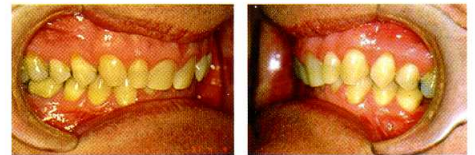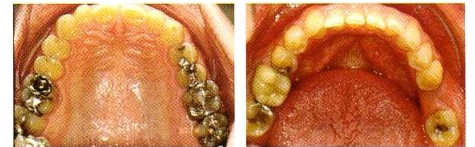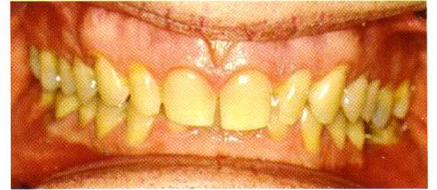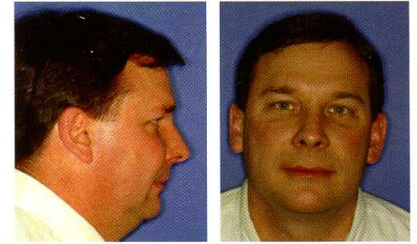During the first 12 weeks both lower second molars and the maxillary right second molar debonded. During the next appointment all three teeth were banded.

Both arches were leveled and aligned first with the Cu Niti's, then 175x175 TMA's, 17x25 TMA's, and finally 17x25 SS. Appointment intervals were 10 to 12 weeks and during the 5th month the implant was restored temporarily and banded.

Once the patient was in Stainless Steele arch wires class II elastics (Rams 6oz \_ inch) were used on the left. The patient attached them from the left maxillary lateral incisor to the left Mandibular second molar. Elastic wear continued for nine months until total class I correction was achieved.

During treatment the maxillary right first molar, mandibular right second bicuspid and first molar debonded and were not rebonded. The mandibular left second bicuspid debonded during class II correction so a buccal bracket was placed on the bicuspid and second molar and a segment was used to maintain alignment while the class II elastics were continued.

Total treatment time was twenty months and clear overlay retainers were delivered at the debond. Eight weeks later the maxillary incisors and the implant were restored and new retainers were made. The patient was instructed to wear his retainers only at night.




## CLINICAL TECHNIQUES FOR LINGUAL

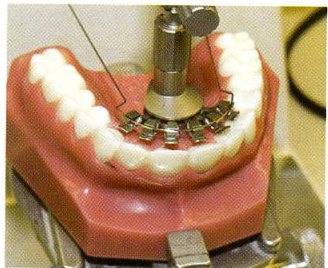With any new procedure there is a learning curve, same is true with working with the Lingual appliance.

The following helpful hints will help to make the clinical process easier.


1. Take accurate, bubble-free impressions for the lab's setup for the indirect bonding trays. This is crucial for proper bracket placement. Make sure the lingual surfaces of the teeth are clean and free of any tartar or calculus before the impressions are taken.
2. When bonding it is imperative to have a clean, well isolated, dry field. Micro-etching the surface is a good way to thoroughly clean the teeth. Using dry-angles and cotton rolls are very helpful in keeping the areas moisture free.
3. Patient positioning is important. Have the patient reclined more than normal and chin elevated higher to help with the clinicians back posture.
4. Good lighting is also a must.
5. A wonderful scaler to purchase is the Hu Friedy double-ended scaler. It has a fine, stiff point, which is great for removing alastics and doing intricate work in the mouth. (Order #600-0485-34/35)
6. Do as much work as possible before archwires are placed, such as, placing figure 8's with ligature and power tube.
7. Educate your patients on the care of their appliances. Eliminating sores and keeping gums healthy will make treatment for them, as well as you much more pleasant.



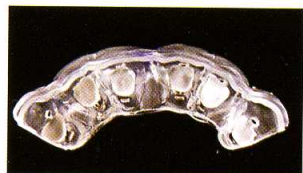Using the TARG in CLASS mode to uniformly place the Anterior Brackets.



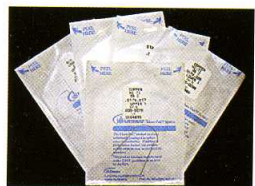The Magic™ Linguset bracket positioning unit featuring nickel free brackets and archwires.



TARG – Torque, Angulation, Reference Guide.



Two piece clear tray system with custom composite bases.



Lingual archwires available in single pack wire packs.